30/LIMP

Robert A. Doughty, M.D., Ph.D., and Carlos D. Rose, M.D.

Limp, an uneven, jerky, or laborious gait, is commonly seen in the presence of musculoskeletal disease in children. Careful observation of the gait and of the anatomic localization of the source of pain/weakness is crucial for identification of the involved area. An antalgic gait results from a short stance phase caused by pain in response to weight-bearing on that extremity, while a Trendelenburg gait is characterized by a downward pelvic tilt during the swing phase due to weakness or spasm of the contralateral gluteus (medius) muscle, often as a result of hip disease.

EVALUATION

Differential Diagnosis

Of the many conditions (Table 30.1) associated with limp, the most common cause at any age is trauma (Table 30.2); a significant injury usually is noted by an older child or adolescent but may be overlooked in an active toddler.

The "orthopedic" limps consist of a group of idiopathic conditions that include slipped capital femoral epiphysis (SCFE), congenital dislocation of the hip (CDH), and avascular necrosis (AVN). Legg-Perthes disease (AVN of the femoral head) affects children 5 to 9 years of age and, as in SCFE, the pain often is referred to the knee. Osgood-Schlatter usually is identifiable by local tenderness and swelling at the level of the distal infrapatellar insertion, and occurs primarily in young adolescents. Chondromalacia patellae is a common clinically diagnosable cause of limp and pain in active adolescent girls. Osteochondritis dissecans, a punched-out lesion of the hyaline cartilage of the femoral condyle, is uncommon but can be diagnosed with plain films.

Benign hypermobility syndrome is a common cause of recurrent musculoskeletal pain in children. It usually presents as 1- to 4-week cycles of episodic, nocturnal, postactivity, bilateral, ill-defined pain of the lower extremities.

An increasingly recognized pediatric condition is reflex sympathetic dystrophy (RSD)—an entity characterized by intense, ill-defined, generally unilateral pain and mottling of the entire extrem Antecedent mild injury or immobilization is co mon. The psychologic background in these p tients often includes environmental stress and s ondary reinforcement.

Most children with limp have minor disorde that respond to treatment on an ambulatory ba A few patients, however, have more serious con tions such as fractures, SCFE, CDH, AVN, an occasionally, potentially severe conditions such septic joint, osteomyelitis, or malignancies (Tab 30.3). Key factors in the evaluation include a hi tory of trauma, fever, findings of systemic illnes localized abnormalities on physical examinatio and in some cases the results of the x-ray, comple blood count (CBC), and erythrocyte sediment tion rate (ESR) (Fig. 30.1).

An obvious traumatic episode followed by lim dysfunction and local evidence of injury narrow the differential considerably. In these cases, a plai x-ray usually confirms fracture, avulsion, or so tissue swelling. Negative x-rays can be seen i stress fractures, particularly in active adolescent and in epiphyseal (Salter I) fractures in young chi dren. The latter is suspected in children with sig nificant local trauma and physeal tenderness o examination. The absence of a history of traum can be misleading, particularly in children unde the age of 3 years of age or in cases of child abuse "Minor" trauma followed by immobilization wit the appropriate psychological background sugges RSD.

Constitutional symptoms such as fever, weigh loss, and anorexia often occur with infection (osteomyelitis, septic arthritis), malignancy, o chronic rheumatic diseases. Elevated ESR, ane mia, thrombocytopenia, or abnormal white cell counts point to significant pathology.

A recurrent pattern of limp suggests a recurrent mechanism. In the absence of joint swelling, the differential diagnosis should include repetitive sports-related injury, internal derangement of the joint, child abuse, and benign hypermobility syndrome. When a history of swelling is elicited, however, chronic rheumatic diseases and Lyme disease

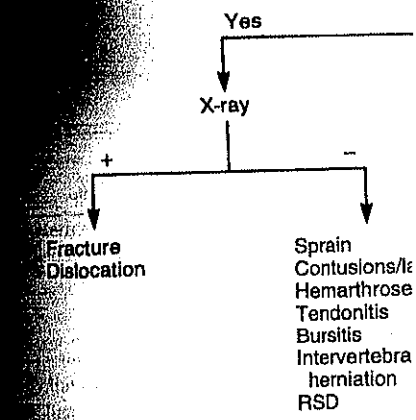

Figure

lead the list. A cyclic pattern of noct dramatic response to aspirin is s osteoma, a benign bony tumor.

Additional historical factors inc of pain (severe with fracture, infe malignancy; milder pain with c rheumatic, and Lyme diseases; an absent with Legg-Perthes, SCFE, a tionship with activity (benign hyp drome); presence of morning stiff chronic rheumatic diseases); and (pain only on weekdays suggest ance). A patient complaint of "joi gests orthopedic sources of limp, nal derangement or osteochondriti free intraarticular bodies.

Referred pain always should particularly during the physical

s D. Rose, M.D.

l mottling of the entire extrem
njury or immobilization is co
logic background in these
es environmental stress and
ent.
with limp have minor disord
atment on an ambulatory ba
vever, have more serious co
tures, SCFE, CDH, AVN,
tially severe conditions such
yelitis, or malignancies (Ta
in the evaluation include a h
er, findings of systemic illne
lities on physical examinatio
he results of the x-ray, comple
), and erythrocyte sedimen
g. 30.1).
matic episode followed by lim
cal evidence of injury narrow
siderably. In these cases, a pla
irms fracture, avulsion, or so
egative x-rays can be seen
rticularly in active adolescent
Salter I) fractures in young chi
suspected in children with si
ma and physeal tenderness o
absence of a history of traum
, particularly in children und
f age or in cases of child abus
llowed by immobilization wi
chological background sugge

ymptoms such as fever, weig
a often occur with infectio
tic arthritis), malignancy, o
diseases. Elevated ESR, an
enia, or abnormal white cel
ificant pathology.
ern of limp suggests a recurren
absence of joint swelling, the
sis should include repetitive
y, internal derangement of the
and benign hypermobility syn
ory of swelling is elicited, how
atic diseases and Lyme disease

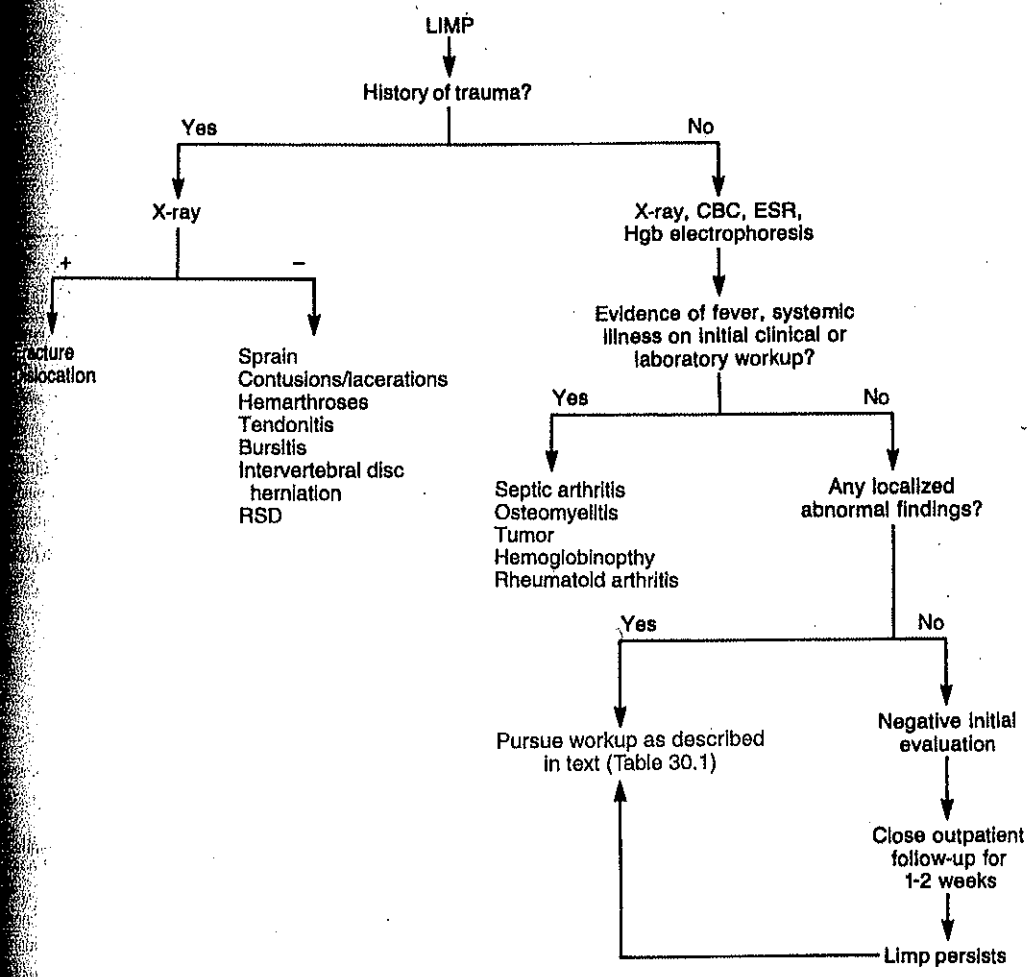

Figure 30.1. Approach to the diagnosis of limp.

ead the list. A cyclic pattern of nocturnal pain with ramatic response to aspirin is seen in osteoid steoma, a benign bony tumor.

Additional historical factors include the degree f pain (severe with fracture, infection, RSD, or malignancy; milder pain with osteochondritis, heumatic, and Lyme diseases; and, occasionally bsent with Legg-Perthes, SCFE, and CDH); relationship with activity (benign hypermobility syndrome); presence of morning stiffness (typical of chronic rheumatic diseases); and daily variation (pain only on weekdays suggests school avoidance). A patient complaint of "joint locking" suggests orthopedic sources of limp, including internal derangement or osteochondritis dissecans with free intraarticular bodies.

Referred pain always should be considered, particularly during the physical examination. A slipped or infected disk or a space-occupying lesion of the spinal canal may cause hip, knee, or leg pain leading to limp. Hip disease may cause pain to be referred to the knee, particularly in Legg-Perthes syndrome and SCFE.

A thorough review of systems should be performed. A recent history of viral infection or use of an antibiotic may suggest an immune complex–mediated arthritis (as seen in postinfectious reactive arthritis), serum sickness (often associated with oral cephalosporins), or toxic synovitis. In postinfectious reactive arthritis and in serum sickness, multiple organ involvement (skin, mucosal membranes, eyes, and internal organs), periarticular swelling, migratory arthritis, acute onset, and systemic features are more typical than a presentation with simple limp. Acute rheumatic fever, Reiter's syndrome, erythema nodosum,

entation

bosacral Spine, crolliac Joint, Pelvis	Hip	Knee	Ankle	Foot	Skin/ Soft Tissue	Neuromuscular
rniated disc	SCFE AVN	Referred hip pain Discoid meniscus	Avulsion Sprain Fractures	Fracture	Tendonitis Bursitis Contusion Laceration	Muscle strain Muscle hematoma Nerve injury
		Fractured patella Collateral/cruciate ligament tear				
citis	Toxic synovitis	Referred hip pain		Spondyloatropathy	Phlebitis Abscess Cellulitis Lymphadenitis	Viral myositis
phylococcus acroiliitis ylosing pondylitis ral mass						Sarcoidosis Trichinosis Dermatomyositis Rhabdomyosarcoma
	Toxic synovitis	Referred hip pain Osgood-Schlatter		New shoes Foreign body Paronychia		Postinfectious myositis
ere scoliosis euermann's isease	CDH SCFE AVN	Chondromalacia Osteochondritis dissecans		Calcaneal spur Warts Bunions AVN	Insect bite	Myasthenia M. dystrophy Spinal cord tumor Sacral tumor Diastematomyelia
ay C t A B27	X-ray MRI	X-ray with hips MRI	X-ray	X-ray CBC ESR HLA B27	CBC ESR Gallium scan	CBC ESR CPK Aldolase Muscle biopsy Nerve conduction EMG CT Scan MRI

R, erythrocyte sedimentation rate; Hgb
ntibodies; HLA, histocompatibility ant
viations.)

important to each joint are listed here

Table 30.2 Causes of Limp Differentiated by Age of Presentation

Preschool
Occult trauma (e.g., muscle/ligament stress, epiphyseal fracture)
Toxic synovitis
Osteomyelitis
School age
Traumatic lesions
Benign hypermobility syndrome
Aseptic necrosis of the femoral epiphysis (Legg-Perthes)
Adolescent
Traumatic lesions
Aseptic necrosis of the tibial tubercle (Osgood-Schlatter)
Slipped capital femoral epiphysis (SCFE)
Reflex sympathetic dystrophy

erythema multiforme, and Henoch-Schönlein purpura are examples of postinfectious processes. Toxic synovitis is the most likely to be seen initially with an isolated limp. Additional findings are limited range of motion of the hip, a moderately elevated erythrocyte sedimentation rate (ESR), and a normal-appearing x-ray. Other pertinent concerns the emergency physician should ask about, especially in examining toddlers, include asking about the presence of the following: (1) recent intramuscular injections; (2) a recent vaccination (particularly measles-mumps-rubella); or (3) new, poorly fitting shoes.

Physical examination should include muscular strength testing; joint examination for warmth, swelling, tenderness, range of motion, and periarticular atrophy (chronic arthritis); and bone percussion for tenderness (discitis, osteomyelitis, and malignancy). Skin tenderness, exquisite pain on palpation, mottling, and decreased temperature are found in RSD. Gait should be observed, with shoes off and on, and the patient should be asked to climb up steps. Leg lengths should be checked (anterior superior iliac crest to medial malleolus), and circumferences measured. Brisk reflexes, borderline Babinski reflex, and a tense heel suggest mild cerebral palsy. Foot deformities are seen in Charcot-Marie-Tooth disease, and tarsal collision and regional weakness can be found in various muscular dystrophies. Special areas to check include (1) the soles of the feet and the area between the toes, for foreign bodies; (2) calluses or marks on the feet that indicate poorly fitting shoes; (3) the spine, to elicit referred pain; (4) the toes, for psoriatic dactylitis or ingrown toenails; (5) the plantar fascia and the Achilles inser-

Table 30.3 Causes of Limp and its Associations

High Morbidity
Fracture
SCFE
AVN
CDH
Discitis and osteomyelitis
Septic arthritis
Potential Mortality
Bone tumors
Leukemia
Neuroblastoma
Thrombophlebitis of deep veins (rare)

tion, for enthesopathy (pain at site of insertion (6) the sacroiliac joints, for tenderness; and (7) t abdomen for a mass. A rectal examination of t patient should be considered to search for a abscess or a sacral mass.

The most useful studies for evaluating limp a (1) the radiograph to rule out fractures, effusion (t not evident on physical examination), lyt lesions, and periosteal reaction; (2) a complet blood count as an indicator of infection, inflam mation, malignancy, or hemoglobinopathy; an (3) ESR to help differentiate infectious, inflam matory, and malignant processes from othe causes of limp. Other potentially useful tes include technetium bone scan (for osteomyelitis Legg-Perthes, septic arthritis, bone marro tumor, discitis, aseptic necroses, and osteo osteoma), arthrocentesis (complete cell counts t differentiate septic, traumatic, and rheumato arthritides; stains and cultures); arthroscopy (f culture, synovial biopsy, and visualization o internal derangements), and gallium scan (t localize occult infection or tumor).

When results of the initial history, physic examination, CBC, ESR, and/or x-rays localiz the site and cause of pathology, the physician ca begin specific management. It is not uncommo however, for children with recent onset of limp t remain undiagnosed despite a thorough initi evaluation. Such children may be managed as out patients without further laboratory work-up a long as close follow-up is assured.

Suggested Readings

Cassidy JT, Petty EE: *Textbook of Pediatric Rheumatology.* Ed Philadelphia, WB Saunders, 1995.

Jacobs JC: *Pediatric Rheumatology for the Practitioner.* Ed New York, Springer, 1993.

Polley HF, Hunder GG: *Physical Examination of the Joints.* Philade phia, WB Saunders, 1978.

31/LY

Paula M. Maz

Palpable lymph nodes are a cor children. Despite the relative abu hold tissue in the neonatal perio ormally are not palpable in the ne the neonatal period, cervical, axill nodes are commonly found. Occ ormally palpated in only 5% of c palpable preauricular and posta avicular, epitrochlear, or popli always abnormal. In general, lym han 1 cm are significant in any lo

VALUATION

A distinction is made between 31.1) and generalized adenopath Generalized adenopathy is defined of more than two noncontiguo regions. Historically, the time of growth, and the duration of ly must be determined. Chronic lym defined as lymphadenopathy of weeks' duration, and this histori focuses the clinician on a subset o the broad differential of lympha presence and duration of fever, a pruritus, cough, weight loss, anor are important systemic symptoms

Recent illnesses must be del larly since lymphadenopathy may weeks following the resolution illnesses. Exposure to tuberculo animals, or a history of a pustula vide a diagnostic clue. Certain m notably phenytoin (Dilantin) an cause generalized lymphadenopa

Regional Adenopathy

Table 31.1 describes the d each lymph node region. Occi commonly enlarge in response fungal scalp infections or to ch tion such as seborrheic dermati nodes frequently are enlar chlamydial conjunctivitis (oc Parinaud's syndrome). Subma