

REVIEW ARTICLE

MEDICAL PROGRESS

Alopecia Areata

Amos Gilhar, M.D., Amos Etzioni, M.D., and Ralf Paus, M.D.

THE IMPACT OF CERTAIN SKIN DISEASES ON THE LIVES OF THOSE AFFECTED tends to be underestimated or even dismissed as simply a “cosmetic problem.” Alopecia areata exemplifies such a condition, owing to its substantial disease burden and its often devastating effects on the patient’s quality of life and self-esteem.^{1,2} Although alopecia areata is one of the most common autoimmune diseases, the pathobiology of this chronic, relapsing hair-loss disorder is not fully understood, and the available therapies are disappointing.³⁻⁶

This review summarizes the pathogenesis, clinical presentation, and management of alopecia areata and synthesizes relevant background information concerning the biologic and pathobiologic features of the hair follicle. Currently available evidence suggests that alopecia areata can be considered a T-cell-mediated autoimmune disease in which the gradual loss of protection provided by immune privilege of the normal hair follicle plays an important role.⁷⁻⁹

From Flieman Hospital (A.G.), B. Rappaport Faculty of Medicine, Technion-Israel Institute of Technology (A.G., A.E.), and Meyer’s Children’s Hospital, Rambam Campus (A.E.) — all in Haifa, Israel; the Department of Dermatology, University of Lubeck, Lubeck, Germany (R.P.); and the School of Translational Medicine, University of Manchester, Manchester, United Kingdom (R.P.). Address reprint requests to Dr. Gilhar at the Skin Research Laboratory, B. Rappaport Faculty of Medicine, Technion-Israel Institute of Technology, Haifa, Israel, or at doritg_2000@yahoo.com.

N Engl J Med 2012;366:1515-25.

Copyright © 2012 Massachusetts Medical Society.

EPIDEMIOLOGY

Alopecia areata is the most frequent cause of inflammation-induced hair loss, affecting an estimated 4.5 million people in the United States.¹⁰ Depending on ethnic background and area of the world, the prevalence of alopecia areata is 0.1 to 0.2%,¹¹ with a calculated lifetime risk of 2%. Alopecia areata affects both children and adults and hair of all colors.¹² Although the disorder is uncommon in children under 3 years of age, most patients are relatively young: up to 66% are younger than 30 years of age, and only 20% are older than 40 years of age. There is generally no sex predilection, but more men were found to be affected in one study involving a group of subjects who were 21 to 30 years of age.¹³ In a study of 226 Chinese patients with alopecia areata who were 16 years of age, the median age at onset was 10 years, and the male:female ratio was 1.4:1; the disorder was more severe in boys and in those with an onset in early childhood.¹⁴

Alopecia areata is associated with an increased overall risk of other autoimmune disorders (16%).^{15,16} For example, it is accompanied by lupus erythematosus in 0.6% of patients,¹⁷ vitiligo in 4%,¹⁸ and autoimmune thyroid disease in 8 to 28%.¹⁹

NORMAL HAIR GROWTH

It is important to understand normal hair growth and the normal immunobiology of the hair follicle in order to appreciate the changes that occur in alopecia areata and thus its clinical presentation and diagnosis. Hair follicles are the only organs in the human body that undergo extensive, lifelong, cyclic transformation.^{20,21} They switch from a period of very rapid growth, pigmentation, and hair-shaft production (anagen, the active-growth phase, with classification ranging from stages I to VI) to a short, apoptosis-driven phase of organ involution (catagen). After catagen, the hair follicle

enters a period of relative quiescence (telogen) before it reenters anagen (Fig. 1A).^{20,21} This regenerative cycle is made possible by an abundance of keratinocyte and melanocyte stem cells located for the most part in the so-called bulge area (Fig. 1B).^{20,21,23,24} Although hair-follicle cycling and regeneration are stem-cell-dependent,²⁴ hair-shaft production and pigmentation are accomplished by the differentiated progeny of these stem cells. These rapidly proliferating keratinocytes and the pigment-producing melanocytes reside in the anagen hair matrix (Fig. 1A),^{20,21,23,24} the major target of the inflammatory attack in alopecia areata.²⁵⁻²⁸

IMMUNOBIOLOGY OF THE HAIR FOLLICLE

A crucial immunologic feature of the hair follicle is its creation of a milieu of relative immune privilege that normally renders unlikely an autoimmune attack on intrafollicularly expressed autoantigens.²⁹⁻³¹ This relative immune privilege is established mainly by suppression of the surface molecules required for presenting autoantigens to CD8+ T lymphocytes (i.e., major histocompatibility complex [MHC] class Ia antigens [HLA types A, B, and C] in association with MHC class I-stabilizing β_2 -microglobulin) and by the generation of an overall immunoinhibitory local signaling milieu.²⁹⁻³² Although the physiological function of immune privilege with respect to hair follicles is not yet evident, we do know that several autoantigens associated with pigment production are highly immunogenic (as seen in vitiligo and halo nevi). Therefore, one plausible theory is that melanogenesis-associated autoantigens generated during active hair-shaft pigmentation — and perhaps other anagen-associated hair-follicle autoantigens — pose a constitutive risk of attracting autoreactive CD8+ T cells already present.²⁹⁻³² As with other tissues protected by classic immune privilege (e.g., the anterior chamber of the eye, the central nervous system, and the fetal trophoblast),^{33,34} down-regulation of MHC class I molecules may serve to reduce the risk that follicle-associated autoantigens will be presented to CD8+ T cells.^{29,30} (See Table 1 in the Supplementary Appendix, available with the full text of this article at NEJM.org.)

This down-regulation of MHC class I molecules, however, entails the risk that the hair follicle may be attacked by natural killer (NK) cells,

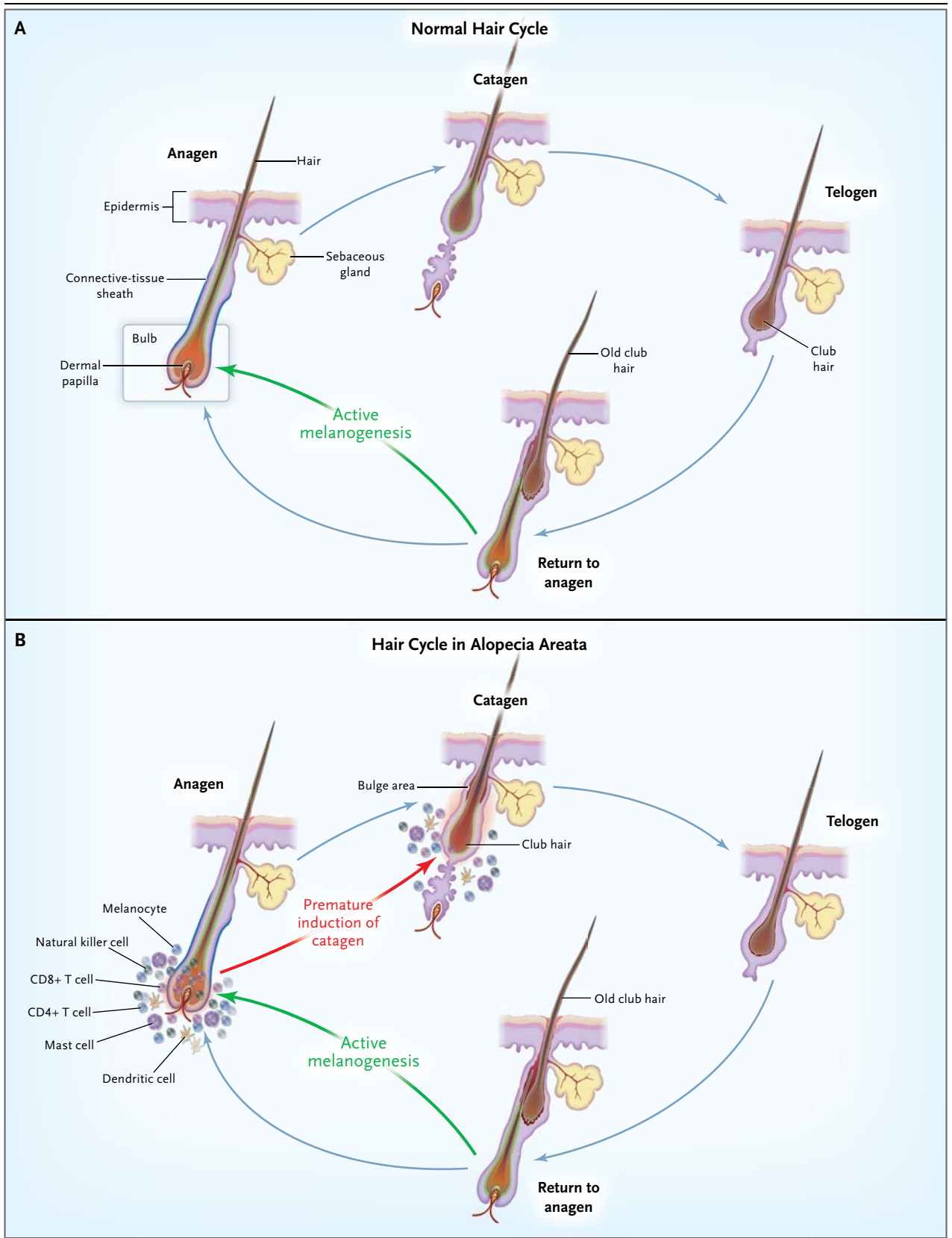
Figure 1 (facing page). The Normal Hair Cycle and Disordered Cycling in Alopecia Areata.

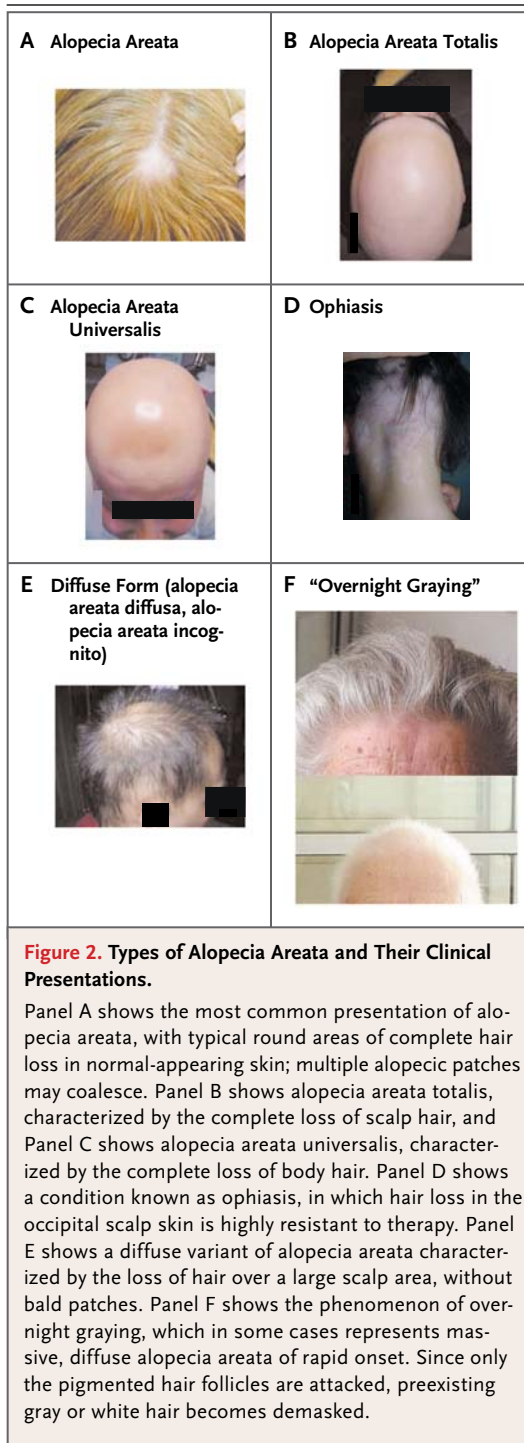
Panel A shows the normal cycle of hair growth, in which human hair follicles are continuously transformed in a cycle of organ construction and deconstruction. During anagen, which for scalp hair lasts 1 to 8 years, a pigmented hair shaft is generated. This phase of active growth consists of six stages (I through VI). Anagen is followed by catagen, a rapid, apoptosis-driven organ-involution phase that lasts several weeks, during which melanogenesis is switched off and the hair shaft is transformed into a “club hair.” The hair follicle then enters telogen, a phase of relative quiescence that varies in duration (e.g., lasting several months on the scalp), and then returns to anagen.²² Panel B shows the disordered, shortened hair cycle in patients with alopecia areata, in which a characteristic inflammatory-cell infiltrate attacks only (or at least primarily) pigment-producing hair follicles (predominantly those in stages III through VI of anagen). The mixed inflammatory-cell infiltrate contains T cells, mast cells, natural killer (NK) cells, and dendritic cells, among which CD8+ T cells are typically the first inflammatory cells seen to be entering the anagen hair-bulb epithelium. (A more detailed description of these cycles can be found in the Supplementary Appendix.)

since NK cells are primed to recognize and eliminate MHC class I-negative cells.³⁵ To reduce this risk, healthy hair follicles appear to down-regulate the expression of ligands that stimulate the activation of NK-cell receptors (NKG2D)³⁶ and secrete molecules that inhibit NK-cell and T-cell functions, such as transforming growth factors β_1 and β_2 , α melanocyte-stimulating hormone, and macrophage migration inhibitory factor.³²⁻³⁷ In the hair follicles of healthy rodents, immune privilege generated in this manner is so effective that even transplanted allogeneic melanocytes escape rejection if they manage to migrate into the hair bulb during anagen (Table 1 in the Supplementary Appendix).^{30,38}

CLINICAL PRESENTATION AND DIAGNOSIS

Alopecia areata is manifested as the loss of hair in well-circumscribed patches of normal-appearing skin, most commonly on the scalp (Fig. 2 and 3) and in the region of the beard (Fig. 3A).^{17,39-41} The onset is typically rapid, and the disease can progress to the point where all the hair is lost on the scalp (alopecia areata totalis) or even on the whole body (alopecia areata universalis) (Fig. 2A, 2B, and 2C). Variants of this disorder include ophiasis, in which hair loss affects the occipital





scalp (Fig. 2D); diffuse forms of alopecia (Fig. 2E); and "sudden graying," a variant in which pigmented hair follicles are attacked, with the result that preexisting gray hairs are demasked (Fig. 2F). These presentations, together with tell-tale clinical signs, such as exclamation-mark hairs

(Fig. 3B), cadaver hairs (Fig. 3C), nail pitting (Fig. 3D), and the growth of white hair in formerly alopecic lesions (Fig. 3E), often render the diagnosis straightforward (Table 1).^{12,42,43} An association of patchy hair loss with autoimmune disorders,¹⁷⁻¹⁹ as well as with atopic dermatitis (in 39% of cases),¹⁵ further points to the correct diagnosis.

If the diagnosis is not clear after a clinical evaluation (Table 1 and Fig. 3), as can be the case with the diffuse variant of alopecia areata, skin biopsy is usually diagnostic. In acute alopecia areata, histologic examination reveals a characteristic "beeswarm pattern" of dense, perifollicular lymphocytic infiltrates around anagen hair follicles (Fig. 1 in the Supplementary Appendix); in patients with chronic disease, this pattern may be absent.^{25,26,28,42} (Additional clinical pictures and recommendations for the diagnostic workup are available from the National Alopecia Areata Foundation at www.naaf.org/site/PageServer?pagename=about_alopecia_types.)

MANAGEMENT

Although diagnosing alopecia areata is usually easy, treating it is not. Curative therapy does not exist, and there is a paucity of well-conducted, long-term, controlled trials evaluating therapy for alopecia areata and its effect on the quality of life.³ Given the often unsatisfactory results of current therapy, some clinicians rely on the high rate of spontaneous remission and will recommend a wig if remission does not occur.³ Still, limited but often helpful therapeutic options do exist for both acute and chronic, relapsing alopecia areata.^{4-6,39}

Clinicians have two principal management options: use of an immunosuppressive regimen (preferable for patients with acute and rapidly progressing alopecia areata) or an immune-deviation strategy that manipulates the intracutaneous inflammatory milieu (favored for patients with the chronic, relapsing form^{39,44}). At present, only two approaches reach the level of evidence-based medicine: intralesional injections of glucocorticoids and the induction of contact allergy.⁴⁻⁶

The best-tested immunosuppressive treatment consists of intradermal injections of triamcinolone acetonide (5 to 10 mg per milliliter) given every 2 to 6 weeks. This agent stimulates localized regrowth in 60 to 67% of cases. Side effects include pain, localized skin atrophy, and depigmentation, and relapses are frequent after treatment has

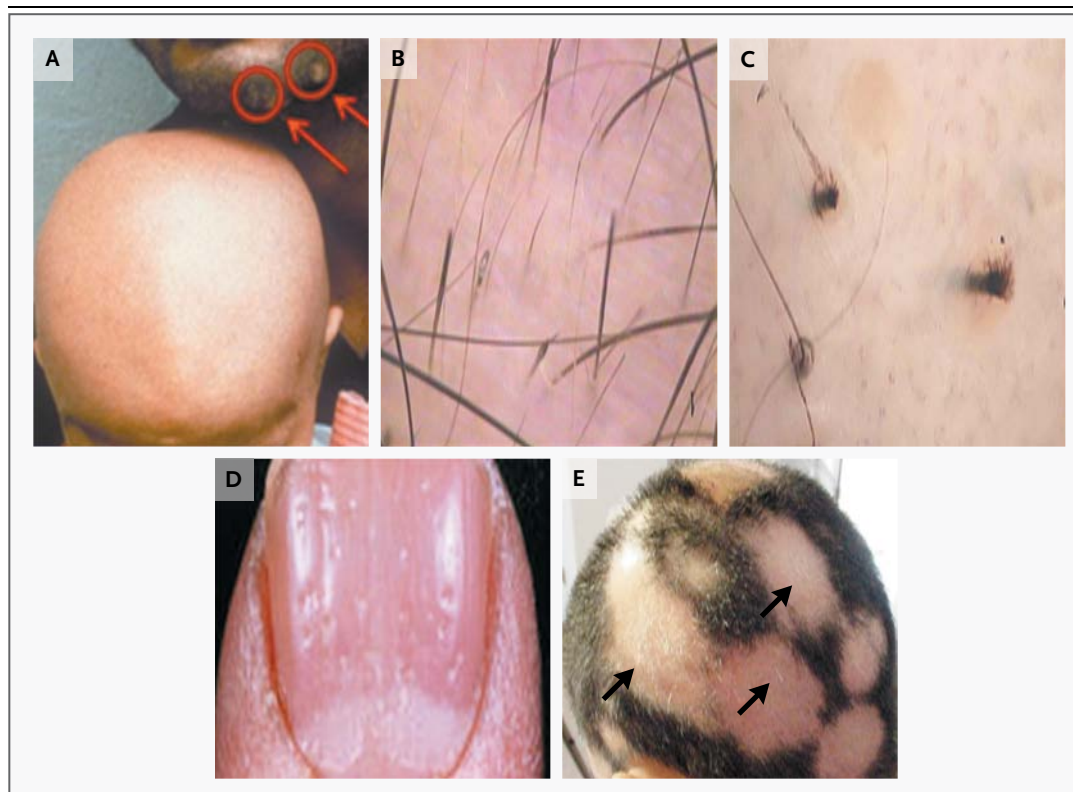


Figure 3. Characteristic Clinical and Dermoscopic Features of Alopecia Areata.

Panel A shows the characteristic features of alopecia areata in a father and his child. The father's hair loss occurred in well-circumscribed patches of clinically uninfamed, symptomless skin in the beard region. The child has alopecia areata totalis. Panel B shows "exclamation-mark hair," in which the distal segment of the hair shaft is broader than its proximal end, and Panel C shows "cadaver hairs" (comedo-like black dots). Panel D shows nail pitting, one of several nail changes that can be present in alopecia areata, another being onychodystrophy. Panel E shows the regrowth of white hair shafts (poliosis) in an alopecic lesion. The signs depicted in Panels B through E are best visualized by means of dermoscopy.⁴¹ Photographs courtesy of Dr. Vera Price, San Francisco (Panel A); Dr. Roberto D'Ovidio, Bari, Italy (Panels B, C, and E); and Dr. Avner Shemer, Tel Aviv (Panel D).

been discontinued.⁴⁵ Potent topical glucocorticoids are also widely used, especially in children and in adults with less than 50% loss of scalp hair.⁴⁶ High-potency topical glucocorticoids with occlusive dressings are most beneficial and lead to improvement in more than 25% of affected patients⁴⁷; however, glucocorticoid-induced folliculitis is a common adverse effect.^{4,5}

The use of systemic glucocorticoids is limited mainly because of their adverse-event and side-effect profiles. In one study, moderate regrowth of hair (31 to 60%) was observed in 30% of patients treated with oral prednisolone (200 mg given once a week for 3 months); however, in 25% of patients with a response, relapse occurred within 3 months.⁴⁸ The best response was achieved with high-dose intravenous methylprednisolone (500 mg given on 3 consecutive days); 147 of 218 patients

(67%) treated for multifocal alopecia areata had more than 50% regrowth of hair. However, relapse occurred within a year in one third of those who had a response, and the number of relapses increased with time.⁴⁹ Other potential immunosuppressive strategies are suggested by case reports of patients with alopecia areata in conjunction with other autoimmune diseases for whom hair regrowth was complete when systemic immunosuppressant agents such as azathioprine were used to treat the other conditions.^{50,51}

The simplest form of topical immunomodulation therapy is the irritant dithranol (anthralin), an antipsoriatic agent.⁵² Dithranol (0.2 to 0.8%) can be applied for 20 to 30 minutes daily as the initial, short-contact therapy, with the length of contact gradually increased by 10 minutes every 2 weeks to a maximum of 1 hour or until a low-grade der-

Table 1. Diagnostic Criteria for Alopecia Areata.

Diagnostic Tool	Diagnostic Findings
Family history	Atopy, thyroid disease, or other autoimmune disorders may be associated with alopecia areata; a family history of any of these disorders may therefore be diagnostic
Physical examination	
Hair and skin	Most characteristic diagnostic finding is the presence of circumscribed, hairless patches or large alopecic areas in otherwise normal-appearing skin areas; pigmented hair is preferentially attacked and lost in active disease, whereas regrowth is frequently characterized by tufts of white hair; sudden pseudowhitening of hair is observed in a rare, rapidly progressing, diffuse variant form of alopecia areata
Nails	Nail changes, if present, are usually characterized by pitting; onychodystrophy is less common
Eyes	Ocular abnormalities include lens opacities and abnormalities of retinal pigment epithelium ⁴³
Dermoscopy	Yellow dots (i.e., keratotic plugs in follicular ostia) are often seen in alopecia areata ³² but are not specific for the diagnosis
Cadaver hairs	Comedo-like cadaver hairs (black dots) may also be present
Exclamation-mark hair	Distal segment of the hair shaft is broader than its proximal end, resembling an exclamation mark
Follicular ostia	Openings in the hair follicles through which the hair fiber emerges from the skin; these ostia are well preserved in alopecia areata, in contrast to the findings in scarring alopecia
Pull test*	A positive pull test at the margins of alopecic lesions that produces telogen ("club") or dystrophic anagen hairs supports a clinical working diagnosis
Laboratory tests	None of the available tests will confirm the diagnosis, but thyroid-function tests and tests for thyroid antibodies may be advisable because of the increased association between alopecia areata and thyroid autoimmunity ²⁹ ; abnormal results of thyroid-function tests, the presence of thyroid autoantibodies, or both further support a clinical or histologic working diagnosis of alopecia areata
Histologic examination†	Biopsy specimens should be obtained only if the clinical diagnosis is in doubt; on histologic examination, a dense, peribulbar lymphocytic infiltrate is seen in acute alopecia areata

* The pull test is also positive in other conditions, such as fungal hair infections.

† This perifollicular infiltrate can be deceptively subtle in long-standing, chronic disease.²⁸

matitis develops. This treatment deserves consideration as a second-line therapy for adults and children with persistent disease.⁴ Indeed, with this approach, hair regrowth was observed in 75% of patients with limited disease (including ophiasis) and in 25% of those with alopecia areata totalis.⁵²

The most effective form of immunotherapy is topical sensitization with diphenylcyclopropenone (diphencyprone [not approved by the Food and Drug Administration]) or squaric acid dibutylester. Diphencyprone can now be considered first-line therapy for alopecia areata totalis.⁴ First, the patient is sensitized to this obligatory synthetic allergen over a period of 1 to 2 weeks; then the lowest diphencyprone concentration that causes mild irritation is applied weekly (with the concentration subsequently increased to maintain a mild contact dermatitis). Although published results of this treatment vary greatly, one relatively large trial (involving 148 patients) showed hair regrowth in

17% of patients with alopecia areata totalis or universalis, 60% of patients with 75 to 99% hair loss, and all patients with less than 50% hair loss.⁵² Diphencyprone has also been used in children with severe alopecia areata (with regrowth reported in 27 to 33% of cases).³ Relapses are common after therapy is discontinued.^{26,53} The most frequent adverse events include pruritus, pain, lymphadenopathy due to local inflammation, generalized contact eczema, influenza-like symptoms, and changes in skin color at the site of al-
lergen application.^{4-6,39,53}

Topical minoxidil, a potassium-channel facilitator that has long been used as a general hair-growth stimulant in androgenetic alopecia, can also be used in alopecia areata, ideally in conjunction with other treatments, such as dithranol cream or oral glucocorticoids.⁴ After a 6-week course of oral glucocorticoids, topical application of 2% minoxidil may help prevent or delay re-

lapse in patients who have had a response to glucocorticoids.^{54,55} Several other topical and systemic agents have been tried, but they have not been shown to offer a clear therapeutic benefit.^{3,4}

PATHOBIOLOGY OF ALOPECIA AREATA

Improved pathobiologic concepts may ultimately pave the way to better management and outcomes in alopecia areata. It is important to note that this is a disorder of hair-follicle cycling in a dual sense⁵⁶: inflammatory cells attack only anagen hair follicles, which are then prematurely propelled into the catagen phase (Fig. 1B).^{26,56} Because of inflammation-induced dystrophy of the follicle, the hair shaft can no longer be firmly anchored in the hair canal and is rapidly shed²⁵; however, the hair follicle retains its capacity to regenerate and continue cycling, since in alopecia areata — unlike scarring alopecias — hair-follicle stem cells are generally not destroyed.⁵⁷ Thus, the loss of hair in this disorder is, in principle, reversible.

Like most other autoimmune diseases, alopecia areata is a chronically relapsing inflammatory disorder, which suggests a cyclic recurrence of disease-promoting events. Also, in the absence of a perifollicular infiltrate, there is no hair loss.^{9,26,27,56} The main therapeutic challenge, therefore, is to reduce the already established inflammatory infiltrates and to prevent both recurrence and spread to previously unaffected hair follicles. Unfortunately, currently available therapies do not predictably and satisfactorily meet this challenge.⁴

A better understanding is needed of how the perifollicular infiltrate in alopecia areata develops and why it chiefly forms around follicles in those stages of the hair cycle during which pigment is produced (i.e., anagen III through VI) (Fig. 1).⁵⁶ Alopecia areata may be considered an organ-specific autoimmune disease, since it exclusively affects hair follicles, nails, and (in some patients) the retinal pigment epithelium.^{4,22,38,42} Therefore, antigens or autoantigens that are preferentially or exclusively presented in these selected tissues could be important in the pathobiology of this disease. In addition, systemic interferon α therapy and tumor necrosis factor α antagonists, which are used to treat other autoimmune diseases, can trigger or aggravate alopecia areata,^{58,59} suggesting that selected cytokines may also be important pathogenetic factors.

GENETIC COMPONENT IN ALOPECIA AREATA

The development of alopecia areata has a strong genetic component (Section I in the Supplementary Appendix). For example, many patients with a family history of alopecia areata also have a personal or family history of atopy, Down's syndrome,^{11,12,42} autoimmune polyendocrinopathy–candidiasis–ectodermal dystrophy syndrome,⁶⁰ other autoimmune diseases, or a combination of these disorders.^{15,42} Familial cases of alopecia areata, as compared with sporadic cases, are often characterized by a poorer prognosis, more rapid progression, more frequent relapses, and greater resistance to therapy.^{17,38} Relatives of affected family members are also at greatly increased risk for alopecia areata.¹⁷ Substantial ethnic variations in the incidence and relative risk of alopecia areata^{11,60-69} further underscore the prominent role of genetic factors in its pathogenesis.

In a genomewide association study of 20 families with alopecia areata, Martinez-Mir et al. identified at least four susceptibility loci on chromosomes 6, 10, 16, and 18; a validation set was not included.⁷⁰ On chromosome 6, one susceptibility locus was found at 6p, a site that corresponds to the HLA locus; a second locus was found at 6q23.3, a site that is outside the HLA gene cluster.⁷⁰ The region on chromosome 16 overlaps with a region near a susceptibility locus for Crohn's disease.⁷⁰ The susceptibility locus for alopecia areata on chromosome 18p also contains a psoriasis-susceptibility region.⁷⁰ Indeed, alopecia areata can coexist with psoriasis.¹⁶

Cytotoxic T-lymphocyte–associated antigen 4 (CTLA4), a costimulatory molecule that is involved in the negative regulation of T-cell activation and has been implicated in psoriasis,^{71,72} may also be a susceptibility gene for alopecia areata — namely, in patients with a severe form of the disorder.⁷³ The CTLA4 association is supported by another genomewide association study in which Petukhova et al. affirmed the importance of both innate immunity and acquired immunity in the pathogenesis of alopecia areata and underscored the fact that this disorder shares pathways with other autoimmune diseases (Section I in the Supplementary Appendix).⁷⁴

The two genomewide association studies used different approaches to analyze susceptibility loci

for alopecia areata. Whereas Martinez-Mir et al.⁷⁰ scanned the genome within families of patients affected by alopecia areata, Petukhova et al.⁷⁴ evaluated 1054 patients and 3278 control subjects and identified 139 single-nucleotide polymorphisms that were significantly associated with alopecia areata. Petukhova et al. first performed an *in silico* analysis, which was then used to study samples from patients, whereas the study by Martinez-Mir et al. was solely an *in silico* analysis. Both studies identified susceptibility loci common to alopecia areata on chromosomes 6p (*HLA*), 6q (*UL16* binding protein [*ULBP*]), 10p (*IL2RA*), and 18p (*PTPN22*). In addition, Petukhova et al. identified some genes that may be associated with alopecia areata and other autoimmune diseases, such as the genes for *ULBP*, which encode a class of ligands for activating NKG2D (Section I in the Supplementary Appendix).

BASIC IMMUNOPATHOLOGY

Insights into the immunopathological mechanisms in alopecia areata may be best gained from examining the skin lesions. Although CD4+ T cells predominate numerically in the perifollicular infiltrates, CD8+ T cells appear to be the first lymphocytes to enter the proximal follicular epithelium (Fig. 1B, 1C, and 1E in the Supplementary Appendix).⁷⁵⁻⁷⁸ In addition, the numbers of NK cells and mast cells are greatly increased in the perifollicular infiltrates, raising the question of whether these cells are also involved in the pathogenesis of alopecia areata.^{37,78} Autoantibodies against follicular autoantigens are often found in the serum and skin of patients with alopecia areata,^{79,80} but there is no evidence that they are pathogenic.⁸¹

In fact, in murine models of alopecia areata, the disease can be transferred by CD8+ T cells alone,⁷ especially after the T cells have been primed by contact with melanogenesis-related autoantigens.^{82,83} The transfer of CD8+ T cells together with CD4+ T cells is most effective in initiating the disease in the most widely used murine model,⁷ whereas the transfer of serum or autoantibodies from patients with alopecia areata fails to elicit hair loss.⁸¹ Conversely, depleting CD8+ T cells restores hair growth in a rat model of alopecia areata.⁸⁴ Thus, it is reasonable to consider alopecia areata a CD8+ T-cell-dependent, organ-specific autoimmune disease (Table 2 in the Supplementary Appendix).

HYPOTHETICAL PATHOGENESIS OF ALOPECIA AREATA

It has been hypothesized that alopecia areata develops in a previously healthy hair follicle because its constitutive immune privilege collapses.^{30,85} According to this hypothesis, alopecia areata can occur in a genetically predisposed person only when proinflammatory signals (e.g., interferon- γ and substance P)⁸⁵⁻⁸⁷ known to up-regulate ectopic MHC class Ia expression in human hair-follicle epithelium^{32,87} expose previously “sequestered” follicle-associated autoantigens to preexisting auto-reactive CD8+ T cells (Fig. 4). If costimulatory signals and help from other cells, such as CD4+ T cells^{30,85} and mast cells,⁸⁸ are provided, the lymphocytic infiltrates could attack the hair follicle. Since only anagen hair follicles are attacked, the autoantigens in question may be generated and presented only during anagen (e.g., melanogenesis-associated peptides).^{37,83,85,89} This scenario is supported by extensive evidence derived from mouse models of alopecia areata.^{7-9,82-84,86,90,91}

Genomewide association studies suggest that other proinflammatory factors and NK-cell-stimulating ligands may also be active at some stage during the development of alopecia areata^{37,74} (Fig. 4, and Sections I and II and Table 2 in the Supplementary Appendix). NK cells and NKG2D and their endogenous ligands have been implicated in the pathogenesis of alopecia areata. Although very few NK cells are observed around healthy anagen hair follicles,²⁹ lesional follicles show prominent aggregates of CD56+ and NKG2D+ NK cells.³⁷ Moreover, hair follicles in alopecia areata overexpress MHC class I polypeptide-related sequence A (MICA) protein,³⁷ a key NKG2D agonist,³⁶ whereas MICA expression in healthy hair follicles is much more limited.³⁷ The conclusion that excessive NKG2D-mediated signaling may contribute to the pathogenesis of alopecia areata is underscored by the genetic association between the disease and NKG2D-activating ligands from the MICA family — namely, *ULBP3*. (*ULBP3* protein expression is actually up-regulated around lesional hair follicles in alopecia areata.⁷⁴)

FUTURE THERAPY

Current pathobiologic concepts may inform pre-clinical research to develop better therapeutic options for alopecia areata. Treatment strategies that

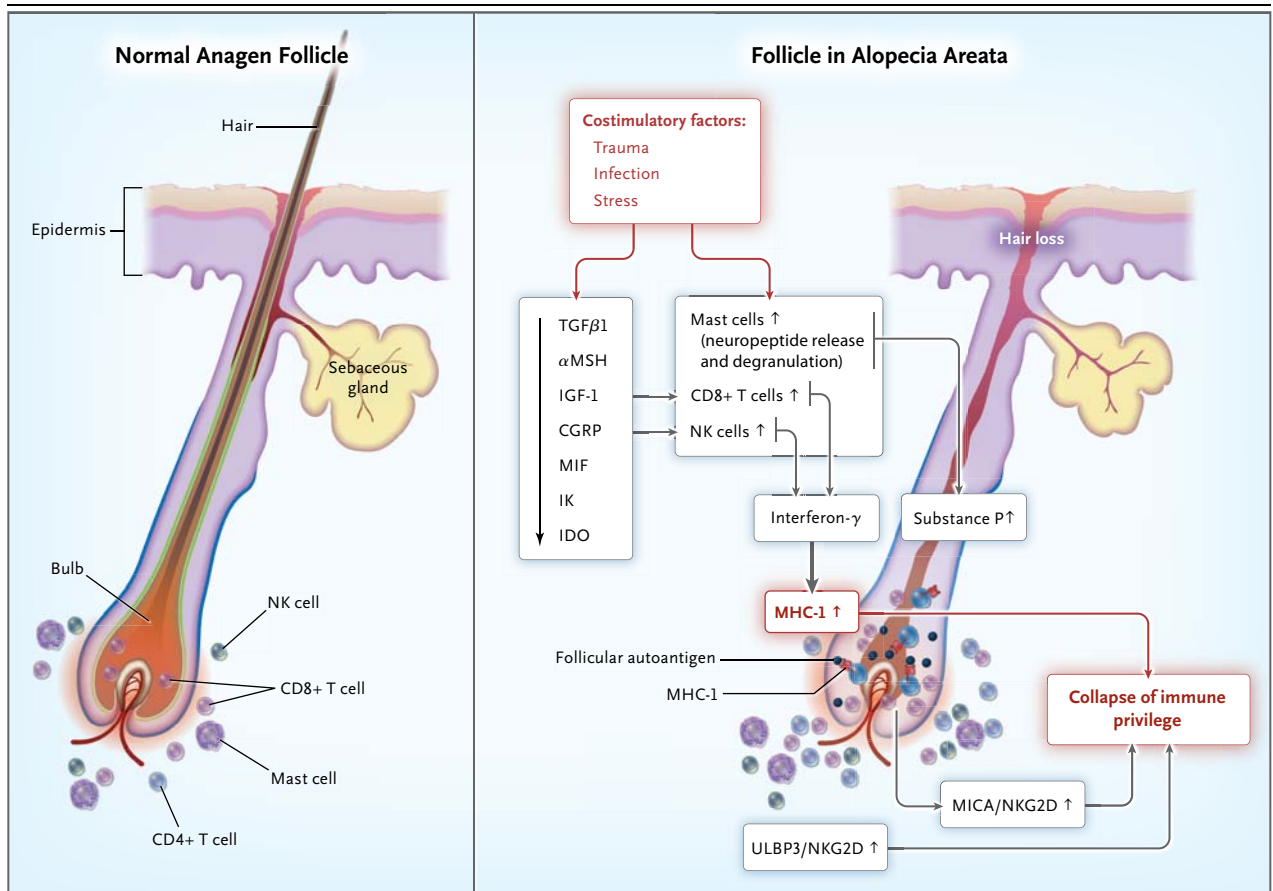


Figure 4. Theory of Immune Privilege Collapse in Alopecia Areata.

Under normal conditions, the hair follicle is protected by a relatively labile immune privilege. Patients with a certain specific genetic background are predisposed to abnormalities in the microenvironment of the follicle, allowing follicular autoantigens (e.g., melanogenesis-associated antigens) to be presented to preexisting autoreactive CD8+ T cells. When various costimulatory circumstances occur during anagen (e.g., trauma, infection, or stress), the clinical phenotype of alopecia areata results. (For a more detailed explanation of this process, see the additional description of Figure 4 in the Supplementary Appendix.) CGRP denotes calcitonin gene–related peptide, IDO indoleamine 2,3-dioxygenase, IGF-1 insulin-like growth factor 1, IK down-regulator of HLA II, MHC major histocompatibility complex, MICA MHC class I polypeptide–related sequence A, MIF migration inhibitory factor, α MSH α melanocyte–stimulating hormone, NK natural killer, NKG2D activating receptor for NK cells and subgroups of T lymphocytes, and TGF- β 1 transforming growth factor β 1.

restore or prevent the collapse of hair-follicle immune privilege and that antagonize excessive NKG2D-mediated signaling or the interaction of pathogenic CD8+ T cells with MHC class I–presented hair-follicle autoantigens may eventually lead to more effective management of this disease.^{4,9,37,74,85,91} New therapeutic strategies now being explored in preclinical research are described in Section III in the Supplementary Appendix.

This common autoimmune disorder already provides an excellent, easily accessible model of disease with which to investigate general principles concerning the generation, maintenance, collapse, and restoration of immune privilege.^{9,30,37,92} In-

sights obtained from such research may thus also become relevant to the treatment of other autoimmune diseases characterized by the collapse of immune privilege, such as multiple sclerosis, immune abortion, and autoimmune uveitis.^{9,33,34,41,92}

Supported in part by grants from the National Alopecia Areata Foundation (to Dr. Gilhar) and from Deutsche Forschungsgemeinschaft (DFG, GRK 1727 Autoimmunity) (to Dr. Paus). Dr. Paus reports receiving consulting fees from Henkel, Procter & Gamble UK, and Wolff Pharma and royalties from Thieme Publications and, on behalf of his institution, consulting fees from Wolff Pharma, Giuliani, and Bayer Germany and grant support from Shiseido, Henkel, Wolff Pharma, Giuliani, Bayer Germany, Curadis, Pflieger Germany, and Unilever UK. No other potential conflict of interest relevant to this article was reported.

Disclosure forms provided by the authors are available with the full text of this article at NEJM.org.

REFERENCES

- Picardi A, Pasquini P, Cattaruzza MS, et al. Psychosomatic factors in first-onset alopecia areata. *Psychosomatics* 2003;44:374-81.
- Paus R, Arck PJ. Neuroendocrine perspectives in alopecia areata: does stress play a role? *J Invest Dermatol* 2009;129:1324-6.
- Delamere FM, Sladden MM, Dobbins HM, et al. Interventions for alopecia areata. *Cochrane Database Syst Rev* 2008;2:CD004413.
- Harries MJ, Sun J, Paus R, King LE Jr. Management of alopecia areata. *BMJ* 2010;341:c3671.
- Alkhalifah A, Alsantali A, Wang E, et al. Alopecia areata update: part II. Treatment. *J Am Acad Dermatol* 2010;62:191-202.
- Garg S, Messenger AG. Alopecia areata: evidence based treatments. *Semin Cutan Med Surg* 2009;28:15-8.
- McElwee KJ, Freyschmidt-Paul P, Hoffmann R, et al. Transfer of CD8(+) cells induces localized hair loss whereas CD4(+)/CD25(-) cells promote systemic alopecia areata and CD4(+)/CD25(+) cells blockade disease onset in the C3H/HeJ mouse model. *J Invest Dermatol* 2005;124:947-57.
- Gilhar A, Ullmann Y, Berkutzki T, Assy B, Kalish RS. Autoimmune hair loss (alopecia areata) transferred by T lymphocytes to human scalp explants on SCID mice. *J Clin Invest* 1998;101:62-7.
- Gilhar A, Paus R, Kalish RS. Lymphocytes, neuropeptides, and genes involved in alopecia areata. *J Clin Invest* 2007;117:2019-27.
- McMichael AJ, Pearce DJ, Wasserman D, et al. Alopecia in the United States: outpatient utilization and common prescribing pattern. *J Am Acad Dermatol* 2007;57:Suppl:S49-S51.
- Safavi K. Prevalence of alopecia areata in the First National Health and Nutrition Examination Survey. *Arch Dermatol* 1992;128:702.
- Finner AM. Alopecia areata: clinical presentation, diagnosis, and unusual cases. *Dermatol Ther* 2011;24:348-54.
- Kyriakis KP, Paltatzidou K, Kosma E, Sofouri E, Tadros A, Rachioti E. Alopecia areata prevalence by gender and age. *J Eur Acad Dermatol Venereol* 2009;23:572-3.
- Xiao FL, Yang S, Liu JB, et al. The epidemiology of childhood alopecia areata in China: a study of 226 patients. *Pediatr Dermatol* 2006;23:13-8.
- Barahmani N, Schabath MB, Duvic M. History of atopy or autoimmunity increases risk of alopecia areata. *J Am Acad Dermatol* 2009;61:581-91.
- Chu SY, Chen YJ, Tseng WC, et al. Comorbidity profiles among patients with alopecia areata: the importance of onset age, a nationwide population-based study. *J Am Acad Dermatol* 2011;65:949-56.
- Goh C, Finkel M, Christos PJ, Sinha AA. Profile of 513 patients with alopecia areata: associations of disease subtypes with atopy, autoimmune disease and positive family history. *J Eur Acad Dermatol Venereol* 2006;20:1055-60.
- Kuchabal SD, Kuchabal DS. Alopecia areata associated with localized vitiligo. *Case Rep Dermatol* 2010;2:27-31.
- Kurtev A, Iliev E. Thyroid autoimmunity in children and adolescents with alopecia areata. *Int J Dermatol* 2005;44:457-61.
- Paus R, Cotsarelis G. The biology of hair follicles. *N Engl J Med* 1999;341:491-7.
- Schneider MR, Schmidt-Ullrich R, Paus R. The hair follicle as a dynamic miniorgan. *Curr Biol* 2009;19:R132-R142.
- Tosti A, Colombati S, De Padova MP, Guidi SG, Tosti G, Maccolini E. Retinal pigment epithelium function in alopecia areata. *J Invest Dermatol* 1986;86:553-5.
- Tobin DJ. The cell biology of human hair follicle pigmentation. *Pigment Cell Melanoma Res* 2011;24:75-88.
- Cotsarelis G. Epithelial stem cells: a folliculocentric view. *J Invest Dermatol* 2006;126:1459-68.
- Whiting DA. Histopathologic features of alopecia areata: a new look. *Arch Dermatol* 2003;139:1555-9.
- The dermis and the subcutis. In: Weedon D. *Weedon's skin pathology*. Vol. 1. 3rd ed. London: Churchill Livingstone/Elsevier, 2009:422-4.
- Khoury EL, Price VH, Greenspan JS. HLA-DR expression by hair follicle keratinocytes in alopecia areata: evidence that it is secondary to the lymphoid infiltration. *J Invest Dermatol* 1988;90:193-200.
- Dy LC, Whiting DA. Histopathology of alopecia areata, acute and chronic: why is it important to the clinician? *Dermatol Ther* 2011;24:369-74.
- Christoph T, Müller-Röver S, Audring H, et al. The human hair follicle immune system: cellular composition and immune privilege. *Br J Dermatol* 2000;142:862-73.
- Paus R, Nickoloff BJ, Ito T. A 'hairy' privilege. *Trends Immunol* 2005;26:32-40.
- Meyer KC, Klatte JE, Dinh HV, et al. Evidence that the bulge region is a site of relative immune privilege in human hair follicles. *Br J Dermatol* 2008;159:1077-85.
- Ito T, Ito N, Bettermann A, Tokura Y, Takigawa M, Paus R. Collapse and restoration of MHC class-I-dependent immune privilege: exploiting the human hair follicle as a model. *Am J Pathol* 2004;164:623-34.
- Carson MJ, Doose JM, Melchior B, Schmid CD, Ploix CC. CNS immune privilege: hiding in plain sight. *Immunol Rev* 2006;213:48-65.
- Niederborn JY. See no evil, hear no evil, do no evil: the lessons of immune privilege. *Nat Immunol* 2006;7:354-9.
- Höglund P, Brodin P. Current perspectives of natural killer cell education by MHC class I molecules. *Nat Rev Immunol* 2010;10:724-34.
- Natarajan K, Dimasi N, Wang J, Marizza RA, Margulies DH. Structure and function of natural killer cell receptors: multiple molecular solutions to self, non-self discrimination. *Annu Rev Immunol* 2002;20:853-85.
- Ito T, Ito N, Saathoff M, et al. Maintenance of hair follicle immune privilege is linked to prevention of NK cell attack. *J Invest Dermatol* 2008;128:1196-206.
- Colombe BW, Price VH, Khoury EL, et al. HLA class II antigen associations help to define two types of alopecia areata. *J Am Acad Dermatol* 1995;33:757-64.
- Tosti A, Duque-Estrada B. Treatment strategies for alopecia areata. *Expert Opin Pharmacother* 2009;10:1017-26.
- Westerhof W, Njoo D, Menkes HE. Sudden whitening of hair. In: Nordlund JJ, Boissy RE, Hearing VJ, King R, Oetting W, Ortonne J-P, eds. *The pigmented system*. 2nd ed. Malden, MA: Blackwell, 2006:764-6.
- Tosti A, Whiting D, Iorizzo M, et al. The role of scalp dermoscopy in the diagnosis of alopecia areata incognita. *J Am Acad Dermatol* 2008;59:64-7.
- Alkhalifah A, Alsantali A, Wang E, McElwee KJ, Shapiro J. Alopecia areata update: part I. Clinical picture, histopathology, and pathogenesis. *J Am Acad Dermatol* 2010;62:177-88.
- Tosti A, Colombati S, Caponeri GM, et al. Ocular abnormalities occurring with alopecia areata. *Dermatologica* 1985;170:69-73.
- Wiseman MC, Shapiro J, McDoland N, Lui H. Predictive model for immunotherapy of alopecia areata with diphenylpyrone. *Arch Dermatol* 2001;137:1063-8.
- Chang KH, Rojhirunsakool S, Goldberg LJ. Treatment of severe alopecia areata with intralesional steroid injections. *J Drugs Dermatol* 2009;8:909-12.
- Pascher F, Kurtin S, Andrade R. Assay of 0.2 percent fluocinolone acetonide cream for alopecia areata and totalis: efficacy and side effects including histologic study of the ensuing localized acneiform response. *Dermatologica* 1970;141:193-202.
- Tosti A, Piraccini BM, Pazzaglia M, Vincenzi C. Clobetasol propionate 0.05% under occlusion in the treatment of alopecia totalis/universalis. *J Am Acad Dermatol* 2003;49:96-8.
- Kar BR, Handa S, Dogra S, Kumar B. Placebo-controlled oral pulse prednisolone therapy in alopecia areata. *J Am Acad Dermatol* 2005;52:287-90.
- Luggen P, Hunziker T. High-dose intravenous corticosteroid pulse therapy in alopecia areata: own experience compared with the literature. *J Dtsch Dermatol Ges* 2008;6:375-8.
- Goddard CJ, August PJ, Whorwell PJ. Alopecia totalis in a patient with Crohn's disease and its treatment with azathioprine. *Postgrad Med J* 1989;65:188-9.
- Farshi S, Mansouri P, Safar F, Khibanloo SR. Could azathioprine be considered as a therapeutic alternative in the

- treatment of alopecia areata? A pilot study. *Int J Dermatol* 2010;49:1188-93.
52. Schmoeckel C, Weissmann I, Plewig G, Braun-Falco O. Treatment of alopecia areata by anthralin-induced dermatitis. *Arch Dermatol* 1979;115:1254-5.
53. Ohlmeier MC, Traupe H, Luger TA, Böhm M. Topical immunotherapy with diphenylcyclopropenone of patients with alopecia areata — a large retrospective study on 142 patients with a self-controlled design. *J Eur Acad Dermatol Venereol* 2011 May 14 (Epub ahead of print).
54. Fenton DA, Wilkinson JD. Topical minoxidil in the treatment of alopecia areata. *BMJ* 1983;287:1015-7.
55. Price VH. Double-blind, placebo-controlled evaluation of topical minoxidil in extensive alopecia areata. *J Am Acad Dermatol* 1987;16:730-6.
56. Messenger AG, Slater DN, Bleehen SS. Alopecia areata: alterations in the hair growth cycle and correlation with the follicular pathology. *Br J Dermatol* 1986;114:337-47.
57. Harries MJ, Paus R. The pathogenesis of primary cicatricial alopecias. *Am J Pathol* 2010;177:2152-62.
58. Ferran M, Calvet J, Almirall M, Pujol RM, Maymó J. Alopecia areata as another immune-mediated disease developed in patients treated with tumour necrosis factor- α blocker agents: report of five cases and review of the literature. *J Eur Acad Dermatol Venereol* 2011;25:479-84.
59. Agesta N, Zabala R, Díaz-Pérez JL. Alopecia areata during interferon alpha-2b/ribavirin therapy. *Dermatology* 2002;205:300-1.
60. Kumar V, Pedroza LA, Mace EM, et al. The autoimmune regulator (AIRE), which is defective in autoimmune polyendocrinopathy-candidiasis-ectodermal dystrophy patients, is expressed in human epidermal and follicular keratinocytes and associates with the intermediate filament protein cytokeratin 17. *Am J Pathol* 2011;178:983-8.
61. Gregersen PK, Olsson LM. Recent advances in the genetics of autoimmune disease. *Annu Rev Immunol* 2009;27:363-91.
62. Duvic M, Hordinsky MK, Fiedler VC, O'Brien WR, Young R, Reveille JD. HLA-D locus associations in alopecia areata: DRw52a may confer disease resistance. *Arch Dermatol* 1991;127:64-8.
63. Tazi-Ahnni R, Cork MJ, Wengraf D, et al. Notch4, a non-HLA gene in the MHC is strongly associated with the most severe form of alopecia areata. *Hum Genet* 2003;112:400-3.
64. Tazi-Ahnni R, Cox A, McDonagh AJ, et al. Genetic analysis of the interleukin-1 receptor antagonist and its homologue IL-1L1 in alopecia areata: strong severity association and possible gene interaction. *Eur J Immunogenet* 2002;29:25-30.
65. Sundberg JP, Silva KA, Li R, Cox GA, King LE. Adult-onset alopecia areata is a complex polygenic trait in the C3H/HeJ mouse model. *J Invest Dermatol* 2004;123:294-7.
66. Sun J, Silva KA, McElwee KJ, King LE Jr, Sundberg JP. The C3H/HeJ mouse and DEBR rat models for alopecia areata: review of preclinical drug screening approaches and results. *Exp Dermatol* 2008;17:793-805.
67. Rodriguez TA, Fernandes KE, Dresser KL, Duvic M. Concordance rate of alopecia areata in identical twins supports both genetic and environmental factors. *J Am Acad Dermatol* 2010;62:525-7.
68. Betz RC, König K, Flaquer A, et al. The R620W polymorphism in PTPN22 confers general susceptibility for the development of alopecia areata. *Br J Dermatol* 2008;158:389-91.
69. Kemp EH, McDonagh AJ, Wengraf DA, et al. The non-synonymous C1858T substitution in the PTPN22 gene is associated with susceptibility to the severe forms of alopecia areata. *Hum Immunol* 2006;67:535-9.
70. Martinez-Mir A, Zlotogorski A, Gordon D, et al. Genome wide scan for linkage reveals evidence of several susceptibility loci for alopecia areata. *Am J Hum Genet* 2007;80:316-28.
71. Muto M, Deguchi H, Tanaka A, Inoue T, Ichimiya M. Association between T-lymphocyte regulatory gene CTLA4 single nucleotide polymorphism at position 49 in exon 1 and HLA-DRB1*08 in Japanese patients with psoriasis vulgaris. *J Dermatol Sci* 2011;62:70-1.
72. Singh TP, Schöen MP, Wallbrecht K, et al. 8-Methoxypsoralen plus ultraviolet A therapy acts via inhibition of the IL-23/Th17 axis and induction of Foxp3+ regulatory T cells involving CTLA4 signaling in a psoriasis-like skin disorder. *J Immunol* 2010;184:7257-67.
73. John KK, Brockschmidt FF, Redder S, et al. Genetic variants in CTLA4 are strongly associated with alopecia areata. *J Invest Dermatol* 2011;131:1169-72.
74. Petukhova L, Duvic M, Hordinsky M, et al. Genome-wide association study in alopecia areata implicates both innate and adaptive immunity. *Nature* 2010;466:113-7.
75. Bodemer C, Peuchmaur M, Fraitaig S, Chatenoud L, Brousse N, DeProst Y. Role of cytotoxic T cells in chronic alopecia areata. *J Invest Dermatol* 2000;114:112-6.
76. Kalish RS, Johnson KL, Hordinsky MK. Alopecia areata: autoreactive T cells are variably enriched in scalp lesions relative to peripheral blood. *Arch Dermatol* 1992;128:1072-7.
77. Dressel D, Brütt CH, Manfras B, et al. Alopecia areata but not androgenetic alopecia is characterized by a restricted and oligoclonal T-cell receptor-repertoire among infiltrating lymphocytes. *J Cutan Pathol* 1997;24:164-8.
78. Cetin ED, Savk E, Uslu M, Eskin M, Karul A. Investigation of the inflammatory mechanisms in alopecia areata. *Am J Dermatopathol* 2009;31:53-60.
79. Tobin DJ. Characterization of hair follicle antigens targeted by the anti-hair follicle immune response. *J Invest Dermatol Symp Proc* 2003;8:176-81.
80. Hedstrand H, Perheentupa J, Ekwall O, et al. Antibodies against hair follicles are associated with alopecia totalis in autoimmune polyendocrine syndrome type 1. *J Invest Dermatol* 1999;113:1054-8.
81. Gilhar A, Pillar T, Assy B, David M. Failure of passive transfer of serum from patients with alopecia areata and alopecia universalis to inhibit hair growth in transplants of human scalp skin grafted on to nude mice. *Br J Dermatol* 1992;126:166-71.
82. Gilhar A, Landau M, Assy B, Shalaginov R, Serafimovich S, Kalish RS. Mediation of alopecia areata by cooperation between CD4+ and CD8+ T lymphocytes: transfer to human scalp explants on Prkdc(scid) mice. *Arch Dermatol* 2002;138:916-22.
83. *Idem*. Melanocyte-associated T cell epitopes can function as autoantigens for transfer of alopecia areata to human scalp explants on Prkdc(scid) mice. *J Invest Dermatol* 2001;117:1357-62.
84. McElwee KJ, Spiers EM, Oliver RF. In vivo depletion of CD8+T cells restores hair growth in the DEBR model for alopecia areata. *Br J Dermatol* 1996;135:211-7.
85. Paus R, Slominski A, Czarnetzki BM. Is alopecia areata an autoimmune-response against melanogenesis-related proteins, exposed by abnormal MHC class I expression in the anagen hair bulb? *Yale J Biol Med* 1993;66:541-54.
86. Siebenhaar F, Sharov AA, Peters EM, et al. Substance P as an immunomodulatory neuropeptide in a mouse model for autoimmune hair loss (alopecia areata). *J Invest Dermatol* 2007;127:1489-97.
87. Peters EM, Liotiri S, Bodó E, et al. Probing the effects of stress mediators on the human hair follicle: substance P holds central position. *Am J Pathol* 2007;171:1872-86.
88. Stelekati E, Bahri R, D'Orlando O, et al. Mast cell-mediated antigen presentation regulates CD8+ T cell effector functions. *Immunity* 2009;31:665-76.
89. Wade MS, Sinclair RD. Persistent depigmented regrowth after alopecia areata. *J Am Acad Dermatol* 2002;46:619-20.
90. Kang H, Wu WY, Lo BK, et al. Hair follicles from alopecia areata patients exhibit alterations in immune privilege-associated gene expression in advance of hair loss. *J Invest Dermatol* 2010;130:2677-80.
91. Alli R, Nguyen P, Boyd K, Sundberg JP, Geiger TL. A mouse model of clonal CD8+ T lymphocyte-mediated alopecia areata progressing to alopecia universalis. *J Immunol* 2012;188:477-86.
92. Kinori M, Kloeppe JE, Paus R. Can the hair follicle become a model for studying selected aspects of human ocular immune privilege? *Invest Ophthalmol Vis Sci* 2011;52:4447-58.

Copyright © 2012 Massachusetts Medical Society.