

PediatricsⁱⁿReview[®]

Acne and Its Management
S. Alison Basak and Andrea L. Zaenglein
Pediatrics in Review 2013;34;479
DOI: 10.1542/pir.34-11-479

The online version of this article, along with updated information and services, is located on the World Wide Web at:
<http://pedsinreview.aappublications.org/content/34/11/479>

Pediatrics in Review is the official journal of the American Academy of Pediatrics. A monthly publication, it has been published continuously since 1979. Pediatrics in Review is owned, published, and trademarked by the American Academy of Pediatrics, 141 Northwest Point Boulevard, Elk Grove Village, Illinois, 60007. Copyright © 2013 by the American Academy of Pediatrics. All rights reserved. Print ISSN: 0191-9601.

American Academy of Pediatrics

DEDICATED TO THE HEALTH OF ALL CHILDREN™



Acne and Its Management

S. Alison Basak, MD, MA,*
Andrea L. Zaenglein, MD**†

Author Disclosure
Dr Basak has disclosed no financial relationships relevant to this article. Dr Zaenglein has disclosed that she has received research grants from Galderma Laboratories, Johnson and Johnson, Mediceis Pharmaceutical Corp., Stiefel Laboratories Inc., and Photocure Inc., that she has acted as a consultant for Galderma, Promius, Mediceis, and Valeant Pharmaceuticals International, and that she has been a speaker for Galderma. This commentary does contain discussion of unapproved/investigative use of a commercial product/device.

Practice Gap

Acne is the most common skin disorder in the United States, affecting approximately 85% of young people between 12 and 24 years of age. Critical components to diminish physical and psychological concerns and lessen the potential for permanent sequelae include correct choice of therapy, and promotion of adherence to therapeutic regimens by educating patients regarding expected adverse effects, realistic expectations for improvement and the importance of maintenance regimens.

Objectives After completing this article, readers should be able to:

1. Diagnose different types of acne lesions and assess severity.
2. Recognize and correct common misconceptions about acne held by patients and their parents.
3. Prescribe appropriate therapy according to the patient's clinical presentation.
4. Educate patients regarding the expected course and potential adverse effects of therapies.

Introduction

Acne vulgaris (acne) is the most common skin disorder in the United States. (1)(2) The severity can vary from mild comedonal acne to fulminant systemic disease that affects multiple organ systems. Acne often is a cause of permanent scarring, emotional distress, and decreased self-esteem, which has led to the development of a multibillion dollar industry of medications, beauty products, and procedures that target individuals with acne. (3) Highly effective treatments are available, so familiarity with the diagnosis and management of this condition is essential for virtually all health care professionals.

Epidemiology

Acne vulgaris affects 40 million to 50 million individuals each year in the United States. (1)(4) Although acne, or one of its variants, can occur in people of every age, adolescents are the most commonly affected group. Approximately 85% of people between 12 and 24 years of age will have acne. (5) Adolescent acne usually begins with the onset of puberty, occurring earlier in girls than boys. Early on, blackheads and whiteheads predominate, and the midface, known as the T zone, is involved typically. Later, inflammatory lesions become more prevalent, and the lateral aspects of the cheeks, jaw, back, and chest are affected. Unfortunately, contrary to previous dogma, not all patients outgrow the condition; 12% of women and 3% of men continue to have clinical acne until 44 years of age. (6)

Pathogenesis

Acne is a chronic inflammatory process of the pilosebaceous unit, which consists of a hair, its associated sebaceous gland, and the opening of the follicle to the skin surface known as the follicular ostium (colloquially called a *pore*). These units are concentrated on the face, back, and chest, which explains

Abbreviations

DHEAS: dehydroepiandrosterone sulfate
FDA: Food and Drug Administration
FSH: follicle-stimulating hormone
LH: luteinizing hormone
OTC: over the counter

*Department of Dermatology, Penn State Hershey Medical Center, Hershey, PA.

†Department of Pediatrics, Penn State Hershey Medical Center, Hershey, PA.

why acne is most prominent in these areas. Four interrelated processes are known to contribute to acne development: abnormal keratinization with obstruction of the follicle, androgen stimulation with increased sebum production, secondary inflammation, and proliferation of bacteria (Fig 1).

Abnormal Keratinization

Individual acne lesions begin with obstruction of the pilosebaceous unit in a process known as comedogenesis. Normally, skin cells lining the upper portion of the hair follicle are shed into the follicular lumen and extruded through the follicular opening. In acne lesions, overproduction and abnormal cohesiveness of these desquamated epithelial cells leads to their retention within the follicle and subsequent obstruction of the ostium. Termed *microcomedones*, these plugs prevent drainage of sebum out of the follicle and lead to its accumulation underneath the skin, eventually forming clinically apparent comedones. Also, proinflammatory mediators, such as interleukin 1 and tumor necrosis factor α are produced by keratinocytes that become activated in response to the disrupted epithelium caused by accumulating sebum. (7)

Comedones can be divided into open and closed subtypes (blackheads and whiteheads, respectively). The open comedone is an easily visible, small, dome-shaped papule with a widely dilated, black-appearing orifice. Although the exact cause of the black color is unknown, it is thought to be secondary to melanin deposition, oxidation of the keratinous material and lipids at the opening, or interference with light transmission through compacted epithelial cells. The color is not due to dirt or poor hygiene. Closed comedones are small, white or flesh-colored papules with no surrounding erythema. Often

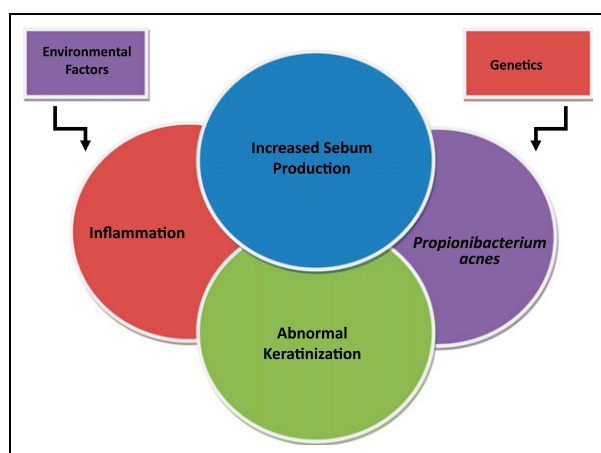


Figure 1. Pathogenesis of acne.

they are not immediately obvious to the naked eye but can be appreciated better on palpation, stretching, or side lighting of the skin. Closed comedones are obstructed follicles in which the opening to the surface has remained microscopic and keeps the contents from escaping. Closed comedones are the lesions that, when they rupture, lead to the pustules, nodules, cysts, and scars seen in inflammatory acne.

Hormonal Stimulation of Sebum Production

Production of sebum, the oily, lipid-rich substance made by sebaceous glands, is controlled primarily by gonadal and adrenal androgen hormone stimulation. Levels of dehydroepiandrosterone sulfate (DHEAS), testosterone, and dihydrotestosterone notably increase at adrenarche, resulting in bigger sebaceous glands that produce more sebum. As the sebum accumulates, microcomedones enlarge into visible comedones. The pressure eventually ruptures the follicle wall in the dermis, causing extrusion of the comedo contents into surrounding epithelium and initiating an inflammatory response. Although hormones play a critical role in the pathogenesis of acne, most patients with acne have normal circulating hormone levels. (8)(9)

Inflammation

Inflammation leads to the characteristic papules and pustules of acne. The clinical appearance of the lesion depends not only on the size of the comedo that has ruptured but also on the extent of the inflammatory reaction in the dermis. Pustules greater than 5 mm in diameter are termed *nodules* and tend to be seated deeper in the dermis. They may coalesce into sinus tracts. The degree of inflammation, determined somewhat by host-specific responses, is a key determinant of scar formation. A person's innate immunity plays a large role in acne, with factors such as β -defensins and cathelicidins all contributing to resultant inflammation. (10)(11)(12)

Bacteria

The ordinarily harmless bacterium, *Propionibacterium acnes*, contributes significantly to the production of acne. These commensal, gram-positive, nonmotile rods are found deep within the sebaceous follicle. They produce chemotactic factors, proinflammatory mediators, and lipolytic enzymes through the Toll-like receptor 2 pathway that break down sebum into immunogenic components. All of these agents serve to intensify inflammation at ruptured comedones. (13)(14)(15) Hypersensitivity to *P acnes* also may play a part in the more severe forms of acne. (16) Acne vulgaris is not an infection but rather

an inflammatory process in which bacteria may aggravate but not precipitate the disorder.

Genetics

The tendency to develop acne and the severity of acne are often familial. The number, size, and activity of sebaceous glands are inherited, and concordance of acne severity among identical twins is high. (17) However, given the extremely high prevalence of acne and the influence of environmental factors, it is not possible to attribute the presence of acne solely to genetic factors. (18)

Environmental and Exacerbating Factors

In addition to the pathogenic factors mentioned above, there may be other triggers or exacerbating conditions. Stress appears to be a common trigger for acne, possibly via activation of the hypothalamic-pituitary-adrenal axis and subsequent increase in androgen production. Mechanical factors, such as skin occlusion from sports gear (such as helmets, chin straps, and shoulder pads) may worsen acne. Premenstrual flares are common. Topically applied occlusive preparations, such as pomades and cocoa butter, can contribute to physical blockage of pilosebaceous units. Oils or greases in the work environment also can cause obstructive lesions, affecting people such as mechanics or fast-food workers. Several medications worsen acne, including anabolic steroids, progestins, lithium, isoniazid, hydantoin, and gold. (19)

Patients frequently are concerned about the effect of their diet on their acne. Diet's role in acne currently is a hotly debated topic among acne researchers. Although substantiated dietary culprits may emerge in the future, several controlled studies to date have refuted the value

of dietary restrictions in limiting acne eruptions. (20) (21)(22) For many years, the elimination of foods such as chocolate, soft drinks, milk, fatty foods, ice cream, and iodides was recommended; however, the literature currently does not support these restrictions. (23) Although there may be many good reasons to limit intake of these foods, prevention of acne is not one of them. A patient occasionally will insist on an apparent relationship between a particular food and acne flare-ups, in which case limiting intake of that particular food is common sense.

Another common misperception is that frequent face washing will improve acne. Dirt does not cause acne. In fact, frequent washing and the use of harsh products can irritate the skin, worsen acne, and impair a patient's tolerance for topical medications that truly have the capacity to improve their acne. Commonly held misconceptions are reviewed in Table 1.

Clinical Presentation

Acne can occur at any age, and presentations can vary widely. Acne's protean clinical manifestations include comedones, pustules, papules, nodules, scars, and dyspigmentation. Guidelines for the treatment of childhood acne were recently published and endorsed by the American Acne and Rosacea Society and the American Academy of Pediatrics to establish treatment standards for children with acne. (24)

Neonatal Acne

Neonatal acne is a common disorder, affecting up to 20% of healthy neonates. Involvement usually is limited to the face and most often presents within the first 30 days of life (Fig 2). This acneiform eruption is thought to be related

Table 1. **Acne Misconceptions Corrected**

Myth	Reality
Acne is due to poor diet	Overall, current evidence does not support this. Studies that suggest otherwise need to be replicated before dietary restriction can be justified.
Bad hygiene causes acne	Frequent washing has no improving effect on acne and can actually worsen it. It can also decrease tolerance of acne medications that might otherwise be very effective.
Acne is infectious	Acne is not contagious. Bacteria can worsen but do not cause acne.
Make-up makes acne worse	Greasy cosmetics should be avoided. Noncomedogenic products are fine.
Squeezing pimples makes them go away faster	Squeezing comedones and pustules increases the risk of scarring and can prolong their presence by inciting inflammation, especially if the lesions rupture into the skin rather than to the surface.
Acne only affects teenagers	People of all ages can be affected by acne, and it may persist well beyond the teen years.
Acne is cosmetic	Clinicians often underestimate the psychological effect of acne. For many patients with acne, it is devastating. Rare subtypes of acne can be associated with systemic illness.
Moisturizer makes acne worse	Noncomedogenic moisturizers are an important adjunct to topical retinoids and will not undo the beneficial effects of the medication. Most modern over-the-counter lotions are noncomedogenic.

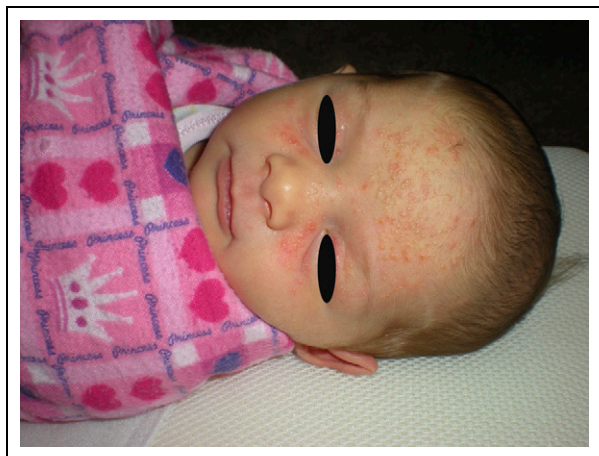

Figure 2. Neonatal acne.

to stimulation of sebaceous glands by maternal androgens and colonization with yeast species. *Malassezia furfur* and *Malassezia sympodialis* often are visible on pustule smears. Whether what most pediatricians know as neonatal acne is true acne is controversial. Many pediatric dermatologists prefer the term *neonatal cephalic pustulosis* to describe this common neonatal process. Most cases resolve spontaneously in several weeks and do not require treatment. In pronounced cases, ketoconazole cream, 2% or hydrocortisone cream, 1%, can be used. If true comedones or nodular lesions are noted, the child should be treated for infantile acne.

Infantile Acne

Infantile acne usually has an age of onset between 3 and 6 months of life. Typically, an admixture of comedones, papules, and pustules is observed on the face (Fig 3). Infantile acne results from physiologic increased production of adrenal and gonadal androgens. Most infants have no hyperandrogenism. However, a complete hormonal evaluation is indicated in any infant with unusually severe or persistent acne or other signs of hyperandrogenism. Most cases resolve by 2 to 3 years of age, with some lasting up to age 5 years. (25)(26)

It is important to treat even mild cases of infantile acne because scarring is significantly more common in this age group. Up to 50% of these infants can develop pitted scars on their cheeks as a consequence of acne. (27) Treatment with a mild retinoid, such as adapalene gel, 0.1%, or tretinoin cream, 0.025%, may be used daily with benzoyl peroxide cream, 2.5%. Certain formulations, such as washes and alcohol-based gels, should be avoided in infants because of the risk of irritation of skin and eyes. For treatment of more severe inflammatory

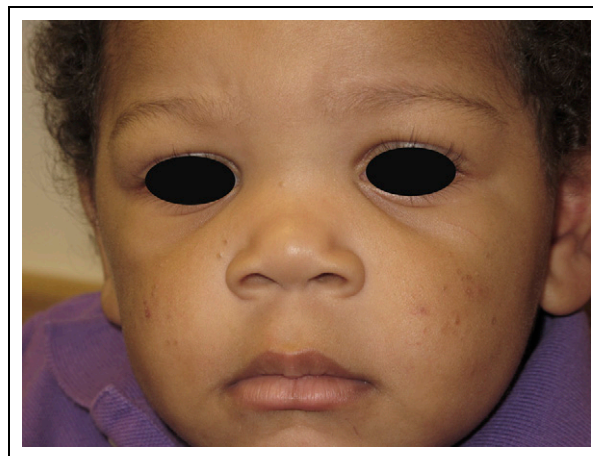

Figure 3. Infantile acne.

lesions, oral erythromycin, azithromycin, or trimethoprim-sulfamethoxazole can be used. For the rare cases of nodulocystic acne, referral to a dermatologist for oral isotretinoin is appropriate.

Mid-Childhood Acne

In children between 1 and 7 years of age, new-onset acne is unusual, and hyperandrogenism should be ruled out with a thorough history, physical examination, and laboratory evaluation. (28) During these years, androgen production should be minimal until approximately 7 years of age, when adrenarche occurs with a resurgence of adrenal androgen production. When acne occurs before the normal timing of adrenarche, the child requires an evaluation for causes of hyperandrogenism, such as congenital adrenal hyperplasia, gonadal or adrenal tumors, Cushing syndrome, and precocious puberty. Treatment is similar to that for adolescent acne (with the exception of using tetracyclines due to the risk of teeth staining) and includes regulation of any identified cause of hyperandrogenism.

Preadolescent Acne

In children 7 years and older, acne often is the first sign of impending puberty, especially in girls. Acne can precede pubic hair development, areolar budding in girls, and testicular enlargement in boys. (28) Most affected children have comedonal lesions that involve the T-zone of the chin, nose, and forehead (Fig 4). Therapy of acne in this age group follows the same algorithm as adolescent acne.

Adolescent Acne

Acne in adolescence can present in a variety of ways. Comedonal acne, as the name suggests, consists primarily of noninflammatory blackheads and whiteheads on the

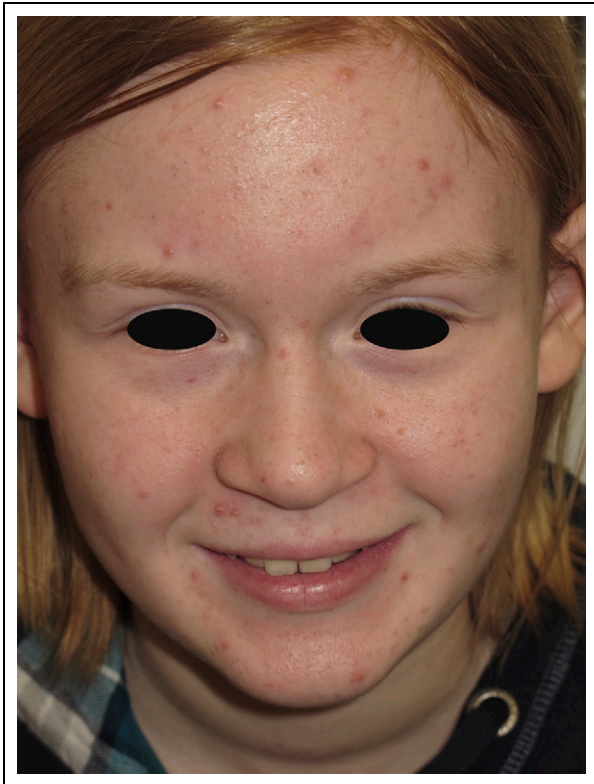

Figure 4. Preadolescent acne.

face and, occasionally, the back and chest. Papulopustular acne is characterized by erythematous papules and pustules 1 to 5 mm in diameter. As the severity progresses, nodules form and become inflamed, indurated, and

tender. Acne cysts that contain pus and serosanguinous fluid develop deeper within the skin, resulting in the nodulocystic acne subtype. In the most severely afflicted patients, these lesions coalesce into complex cystic plaques, abscesses, and sinus tracts. This severe degree of acne without systemic manifestations is termed *acne conglobata*.

Acne fulminans is a rare and severe variant, occurring almost exclusively in boys between 13 and 16 years of age. Acne fulminans is characterized by the abrupt onset of nodular and suppurative acne in association with systemic manifestations, including fever, arthralgias, osteolytic bone lesions, myalgias, hepatosplenomegaly, and severe fatigue. Laboratory abnormalities include leukocytosis and an increased erythrocyte sedimentation rate. Acne fulminans requires emergent evaluation by a dermatologist for initiation of therapy with systemic corticosteroids and isotretinoin. (29) In rare refractory cases, systemic treatment with dapsone, infliximab, cyclosporine, and azathioprine has been used as alternate or adjunctive therapy. (30)(31)(32)(33)

In any patient with an inflammatory type of acne, postinflammatory hyperpigmentation and persistent macular erythema often complicate the treatment of lesions and tend to persist for many months, even when the acne is controlled. Patients can be reassured, however, that these changes will eventually resolve once the condition is controlled. Continued use of topical retinoids can speed resolution of postinflammatory hyperpigmentation. (34) Unfortunately, scarring is permanent because it results from fibrous contraction after resolution of inflammation. The type and extent of scarring depend on

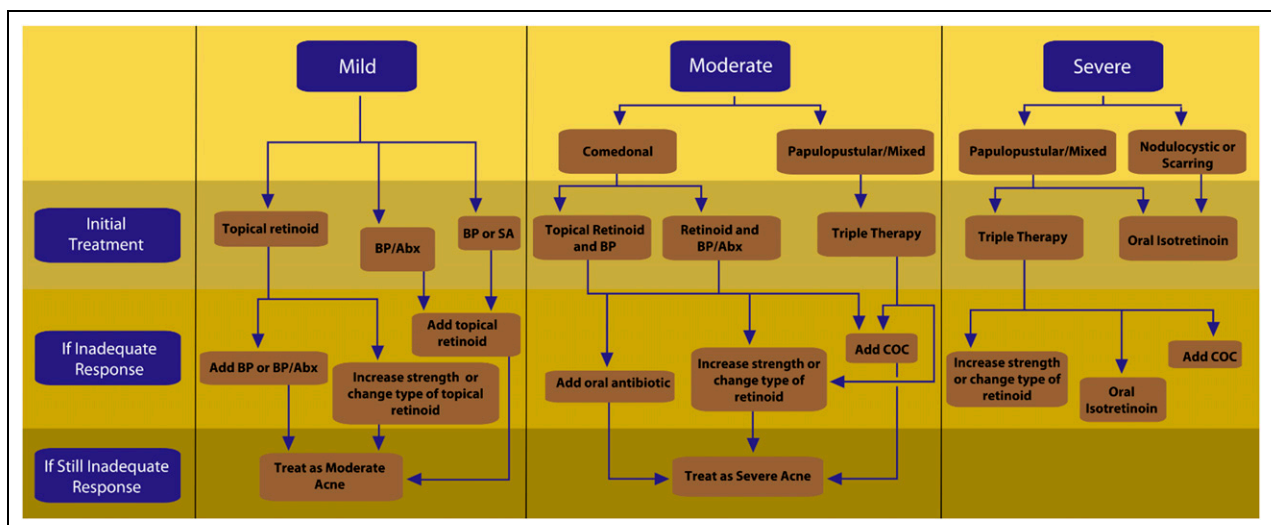


Figure 5. Treatment algorithm for adolescent acne. Triple therapy is benzoyl peroxide (BP), topical retinoid, and oral antibiotic. Abx=topical antibiotic (such as topical clindamycin or erythromycin); COC=combined oral contraceptive.

the acne severity and the patient's individual susceptibility to cicatrization. Scars on the face appear most commonly as sharply punched-out deep or shallow pits. On the trunk, the residual lesions typically are small hypopigmented macules. Hypertrophic and keloidal scars can occur in susceptible patients.

Evaluation

The most important part of an acne evaluation is the history. A list of useful questions and their rationale is presented in Table 2. Physical examination should include the back, chest, and facial skin. Additional examination should be guided by the history. The general severity of acne can be categorized as mild (Fig 6), moderate (Fig 7), or severe (Fig 8), per the guidelines described in Table 3. Most patients with acne do not have endocrinologic abnormalities; therefore, laboratory evaluation should be reserved for those patients whose acne

is associated with additional evidence of androgen excess. (35) Such evidence varies with the patient's age and sex but can include hirsutism, irregular menses, androgenetic alopecia, deepened voice, female clitoromegaly, male virilization, abrupt acne onset, or treatment-resistant acne.

Potential causes of androgen excess include polycystic ovary syndrome, congenital adrenal hyperplasia, gonadal or adrenal tumors, Cushing syndrome, and precocious puberty. Initial evaluation should include bone age determination and measurement of prolactin, free and total testosterone, DHEAS, and 17-hydroxyprogesterone, as well as the ratio of luteinizing hormone (LH) to follicle-stimulating hormone in females. Abnormalities warrant referral to a pediatric endocrinologist. In menstruating females, LH and FSH studies should be performed either just before or during a menstrual period, and patients should not be taking hormonal contraceptives.

Table 2. Key Elements of the Acne History

Question	Rationale
	For All Patients
How long has patient had acne? When did it begin?	Early- or late-onset acne may indicate androgen excess. Abrupt onset and treatment resistance may also be signs of androgen excess.
What over-the-counter and prescription medications have been tried? How were they applied and for how long? If applicable, why was use of medication discontinued?	Is the patient treatment naive? If resistant, could improper technique or an insufficient therapeutic trial be the reason for failure? Would a different strength, combination product, or vehicle help tolerability?
What kinds of cosmetics and/or hair products does the patient use? Is the patient involved in any occupational or recreational activities that can worsen acne?	Can exacerbating factors be minimized? Occlusion from beauty products and/or pressure applied from sporting gear, tight clothes, or greases may worsen acne. Noncomedogenic products should be used.
Is there a history of other medical problems?	Certain medical conditions are associated with recalcitrant acne. Adolescents with sensitive skin or a history of eczema may have less tolerance for drying or irritating topical acne medications.
Does the patient pick at their acne?	Picking at lesions worsens inflammation and is more likely to lead to scarring. Behavior modification can make a huge difference.
How much does the acne bother the patient?	Severity of acne is highly subjective. The patient's desire for therapy and motivation for improvement should be considered to select the most appropriate treatment.
	For Female Patients
Is the patient menstruating? If so, are menses regular?	Could androgen excess, such as polycystic ovary syndrome, be contributing to patient's acne?
Does the patient have premenstrual flares?	Premenstrual flares are common. Combined oral contraceptives are often helpful in this situation.
Is there a history of hirsutism, oligomenorrhea, clitoromegaly, or androgenetic alopecia?	Are there signs of androgen excess that would indicate the need for blood work and/or endocrine referral?
Does the patient use hormonal birth control?	Progesterone-only hormonal contraceptives can worsen acne. Combination estrogen-progesterone products improve acne.
Adapted with permission from Krowchuk DP. Managing adolescent acne: a guide for pediatricians. <i>Pediatr Rev.</i> 2005;26(7):250-261.	

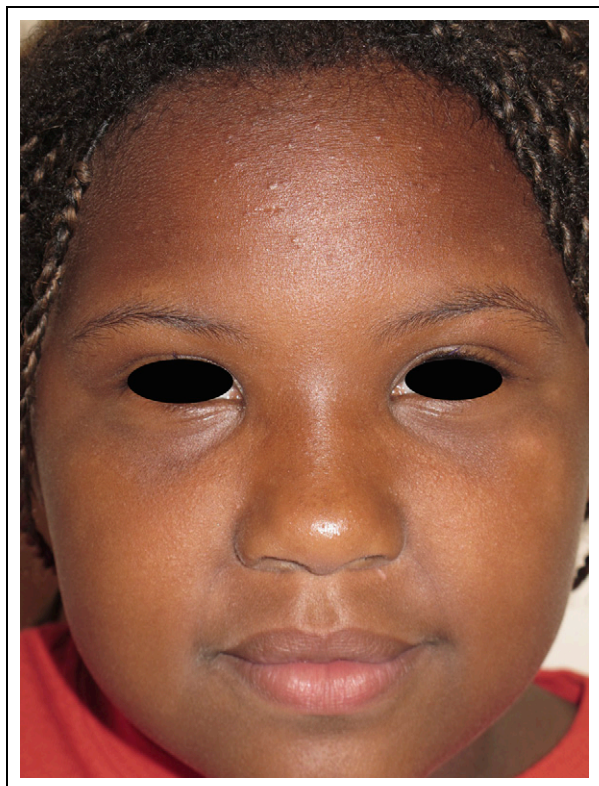

Figure 6. Mild acne.

Therapy

There is no single most appropriate therapy for acne vulgaris. Rather, treatment must be individualized based on response to previously attempted therapies, degree of activity of the acne, patient distress, likelihood of patient compliance, and severity of scarring. Patient education is vital, regardless of the therapy chosen. The clinician must dispel acne myths, highlight the essential need for prolonged adherence to therapy, emphasize the delayed and gradual nature of improvement, and prepare the patient for likely adverse effects and how to manage them. (36) When each of these components is not addressed, dissatisfaction with therapy is highly likely and patients may stop using a therapy that could have been safe and effective if given a proper trial. Therapies control acne but, with the possible exception of isotretinoin, do not cure it. A treatment algorithm is provided in Figure 5.

Topical Treatments

Topical treatments often are the first line of therapy for mild-to-moderate acne and also are useful as part of combination therapy for more severe acne. Commonly used topical medicines include antimicrobials, antibiotics, retinoids, and salicylic acid. Dosing, formulations, and

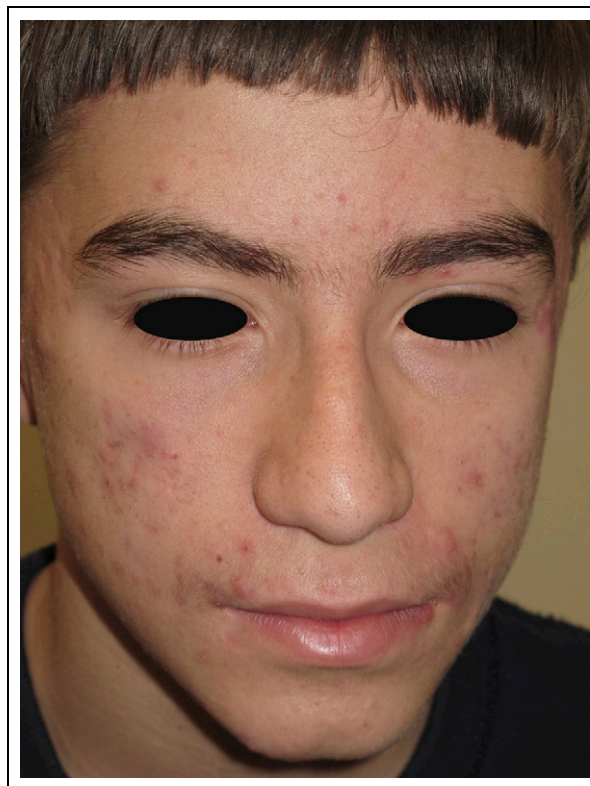

Figure 7. Moderate acne.

possible adverse effects for the most frequently prescribed topical medications are summarized in Table 4. Topical medications are preventive and require 8 to 12 weeks of use to judge their efficacy. The entire area affected by acne must be treated, not just current lesions, and long-term therapy usually is required.

Several fixed-dose combination therapies are available to treat acne (benzoyl peroxide–clindamycin, benzoyl peroxide–erythromycin, adapalene benzoyl peroxide, and tretinoin-clindamycin). These products, although generally more costly, often have greater adherence because of the once daily application. (37) Most manufacturers offer coupon or rebate programs to patients to improve affordability (see individual product websites for information).

BENZOYL PEROXIDE. Benzoyl peroxide is a common active ingredient in many over-the-counter (OTC) products. Benzoyl peroxide is bactericidal for *P. acnes* and also has comedolytic properties, possibly by decreasing formation of free fatty acids, thereby enhancing follicular desquamation and decreasing follicular plugging. Benzoyl peroxide is an excellent medication for patients with mild comedonal or inflammatory acne. Benzoyl peroxide also prevents the emergence of antibiotic-resistant *P. acnes*,

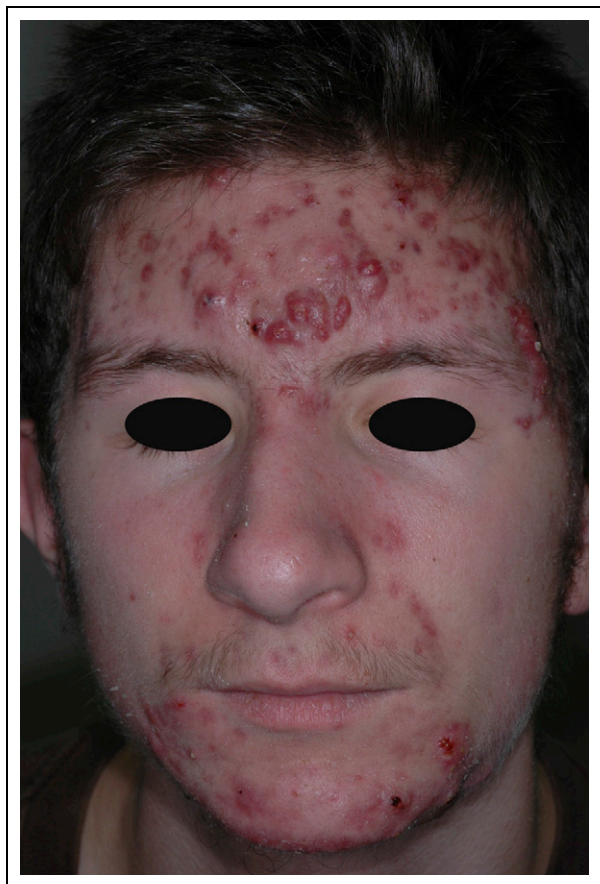

Figure 8. Severe acne.

making it a useful adjunctive therapy in patients being treated with topical or oral antibiotics. (38)(39)(40)

Benzoyl peroxide is available both with and without a prescription in concentrations ranging from 2.5% to 10%. The prescription form generally involves a gel vehicle for enhanced efficacy or combines the benzoyl peroxide with another topical agent, such as an antibiotic or a retinoid, for enhanced ease of use and improved patient

adherence. Products sold OTC include soaps, creams, washes, lotions, and gels. For most patients, a single daily application of 5% is sufficient. Increasing to 10% occasionally provides greater efficacy but also increases adverse effects, which include dryness, irritation, and erythema. Benzoyl peroxide creams are applied as a thin coat over all acne-prone areas. To apply the medication, a pea-sized amount may be dispensed on the finger and then dabbed on the forehead, cheeks, and chin. The cream is then spread over the entire surface except for areas prone to irritation, such as the eyes, alar folds, and angles of the mouth. Larger areas, such as the back and chest, can be treated in the shower or bath with a benzoyl peroxide wash. Alternatively, for more efficacious therapy, the gel or lotion formulation can be applied and allowed to remain in place for several hours (eg, overnight).

Adverse reactions include stinging after application, erythema, peeling skin, and dry skin. These reactions can be counteracted with the use of noncomedogenic emollients, decreased benzoyl peroxide strength, decreased frequency of application, or use of a lotion-based rather than gel-based product. Contact dermatitis is an uncommon but possible adverse effect and presents as erythema with small papules and vesicles that are pruritic. In such cases, the medication should be stopped immediately and alternate therapeutic options tried. Patients should be warned that benzoyl peroxide will bleach clothing, towels, and bedding. The drug is rated pregnancy category C by the US Food and Drug Administration (FDA), meaning that possible risk to the fetus cannot be excluded.

TOPICAL RETINOIDS. Topical retinoids are especially effective in promoting normal desquamation and will benefit patients who have both comedones and inflammatory lesions. These agents reduce obstruction of the follicle and thereby decrease the risk for rupture and secondary inflammation. (41)(42)(43) Retinoids also have a marked anti-inflammatory effect, inhibiting leukocyte activity and the release of proinflammatory cytokines. They help in the penetration of other active ingredients, such as

Table 3. Evaluation of Acne Severity

Grading	Predominant Lesion Type	Distribution	Scarring	Other Factors
Mild	Few to several comedones, few scattered papules	<1/4 th face, mostly T zone	None	None
Moderate	Many papules and pustules, variable comedones, 1–2 nodules	Roughly 1/2 face	Few, shallow	Involvement of the chest and back
Severe	Numerous papules and pustules and nodules; variable comedones; sinus tracts and/or cysts	Face, back, and/or chest	Moderate to extensive, hypertrophic and/or deep	Drainage, hemorrhage, pain

Table 4. Topical Prescription Acne Therapies

Type of Medication	Drug	Brand*: Available Strengths and Vehicles	Directions	Potential Adverse Effects and Comments	
Antibiotics	Clindamycin	Cleocin T [®] : 1% solution, gel, pledgets, lotion Clindets [®] : 1% pledgets	Clindagel [®] and Evoclin [®] : once daily All others: twice daily	Usually well tolerated Theoretical risk of pseudomembranous colitis Gel and pledgets are alcohol based and may be irritating Avoid in patients with clindamycin allergy Pledgets are single-use only; patients should use a fresh pad for each medication application	
		Evoclin [®] : 1% foam Clindagel [®] : 1% gel			
		Clindamax [®] : 1% gel, lotion Clindamycin (generic): 1% gel, solution, lotion, pledgets, foam			
		BenzaClin [®] : 1%/5% gel; 1%/5% gel pump	BenzaClin [®] and generic: twice daily, unless part of combination therapy, then use once daily Duac [®] and Acanya [®] : once daily		Contact dermatitis is rare and usually associated with itchy vesicles Benzoyl peroxide bleaches fabric (eg, towels, shirts)
	Clindamycin and benzoyl peroxide	Duac [®] : 1.2%/5% gel (kit with cleanser) Acanya [®] : 1%/2.5% gel Clindamycin and benzoyl peroxide (generic): 1%/5% gel			
		Erythromycin	Akne-mycin [®] : 2% ointment Ery [®] : 2% pledgets Erythromycin (generic): 2% gel, solution, pledget	Twice daily	Usually well tolerated Gel and pledgets are alcohol based and may be irritating Avoid in patients with erythromycin or macrolide allergy Pledgets are single-use only; patients should use a fresh pad for each medication application
	Erythromycin and benzoyl peroxide	Benzamycin [®] : 3%/5% gel	Twice daily, unless part of combination therapy, then use once daily	Contact dermatitis is rare and usually associated with itchy vesicles Benzoyl peroxide bleaches fabric (eg, towels, shirts)	
		Erythromycin and benzoyl peroxide (generic): 3%/5% gel			
	Azelaic acid	Azelex [®] : 20% cream	Once or twice daily	Slight transient burning common May cause hypopigmentation in darker skin types	
	Dapsone	Aczone [®] : 5% gel	Twice daily	Topical use safe in G6PD deficient patients	
Retinoids	Adapalene	Differin [®] : 0.1% cream, gel, lotion; 0.3% gel	Once daily at bedtime	One of the less irritating topical retinoids (less erythema, dry skin, peeling, burning)	
		Adapalene (generic): 0.1% cream, gel		Good choice in patients with sensitive skin Able to use with benzoyl peroxide More light-stable compared with other topical retinoids	

Continued

Table 4. (Continued)

Type of Medication	Drug	Brand*: Available Strengths and Vehicles	Directions	Potential Adverse Effects and Comments
	Adapalene and benzoyl peroxide	Epiduo [®] : 0.1%/2.5% gel	Once daily at bedtime	Convenient once daily fixed combination therapy Erythema, dry skin, peeling, stinging may occur Benzoyl peroxide bleaches fabric (eg, towels, shirts) Each component can be prescribed individually if cost for the combination is a concern
	Tazarotene	Tazorac [®] : 0.05% cream, gel; 0.1% cream, gel	Once daily at bedtime	More commonly associated with skin irritation (erythema, dry skin, peeling, stinging) Good choice for patients with oily skin Mild photosensitivity Pregnancy category X
	Tretinoin	Retin-A [®] : 0.025%, 0.05%, 0.1% cream; 0.01%, 0.025% gel Retin-A Micro [®] : 0.04%, 0.1% gel Avita [®] : 0.025% cream, gel Atralin [®] : 0.05% gel Tretin-X TM : 0.025%, 0.05% cream kit with cleanser; 0.0375% cream; 0.1% gel kit with cleanser; 0.01%, 0.025% gel Tretinoin (generic): 0.025%, 0.05%, 0.1% cream; 0.01%, 0.025% gel	Once daily at bedtime	Branded formulations able to use with benzoyl peroxide Skin irritation (erythema, dry skin, peeling, stinging) more common at higher strengths Generic formulations not stable with benzoyl peroxide or sunlight Generic tretinoin, Retin-A, Avita, and Tretin-X gels are alcohol based
	Tretinoin and clindamycin	Ziana [®] : 0.025%/1.2% gel Veltin [®] : 0.025%/1.2% gel	Once daily at bedtime	Mild skin irritation (erythema, dry skin, peeling, stinging) Use with benzoyl peroxide to decrease bacterial resistance

Medications listed are examples; the list is not intended to be exhaustive. G6BP=glucose-6-phosphate dehydrogenase.
*Manufacturer and location of brand name medications: Acanya[®], Akne-mycin[®], Atralin[®], BenzaClin[®], Benzamycin[®], Retin-A[®], Retin-A Micro[®] (Valeant Pharmaceuticals International, Bridgewater, NJ); Aczone[®], Azelex[®], Tazorac[®] (Allergan, Inc, Irvine, CA); Avita[®] (Mylan Pharmaceuticals, Morgantown, WV); Cleocin T[®] (Pfizer, Inc, New York, NY); Clindagel[®], Differin[®], Epiduo[®] (Galderma Laboratories, Inc, Fort Worth, TX); Clindamax[®] (PharmaDerm, Florham Park, NJ); Clindets[®], Duac[®], Evoclin[®], Veltin[®] (GlaxoSmithKline, Philadelphia, PA); Ery[®] (Perrigo, Allegan, MI); Tretin-XTM (Onset Dermatologics, Cumberland, RI); and Ziana[®] (Medicis Pharmaceuticals Corp, Scottsdale, AZ).

benzoyl peroxide and antibiotics. Retinoids are the preferred agents in maintenance therapy and should be used in most patients with acne. In patients with purely comedonal acne, they may be the only antiacne medication required. For patients with mild inflammatory acne,

a combination of a retinoid and topical benzoyl peroxide or benzoyl peroxide–antibiotic combination is more efficacious. In severe inflammatory acne, systemic antibiotics may be used in combination with benzoyl peroxide and a topical retinoid.

Tretinoin, a vitamin A derivative, was the first retinoid available for acne and comes in cream and gel formulations. The vehicle affects efficacy, tolerability, and compatibility. Newer formulations of tretinoin into microspheres and a polyolprepolymer appear to be as effective but less irritating than traditional formulations. These preparations also make the active ingredient more stable in the presence of light and benzoyl peroxide. (Generic tretinoin is inactivated by light and benzoyl peroxide.) There have been no epidemiologic studies supporting concerns about increased malformations occurring in infants born to women who used tretinoin during pregnancy. However, because tretinoin's chemical structure is nearly identical to that of isotretinoin, a known teratogen, tretinoin is classified as pregnancy category C and generally is avoided during pregnancy.

Adapalene is another topical retinoid available for acne treatment. This agent is a synthetic compound that binds to a specific retinoid receptor. (44) In a 0.1% gel formulation, it is as effective as tretinoin gel, 0.025%, but less irritating. (45)(46) Adapalene also is light-stable and less susceptible to oxidation by benzoyl peroxide. The method of application and other principles of use are similar to those of tretinoin. Adapalene also is classified as pregnancy category C.

Tazarotene is another receptor-specific synthetic retinoid that is formulated in 0.05% and 0.1% gels and creams. This agent regulates follicular corneocyte cohesion and normalization of keratinization. Designated as pregnancy category X, tazarotene is contraindicated in pregnancy. Contraceptive counseling should be provided for all women of childbearing potential who are prescribed this medication.

The most common adverse effects of all retinoids (tretinoin, adapalene, and tazarotene) are irritation, redness, and dryness, all peaking at approximately 2 weeks of use. In darker skin types, this inflammation can result in hyperpigmentation that can persist for months. To limit adverse effects, most patients are prescribed a low-strength preparation and titrated up according to efficacy and tolerability. As with benzoyl peroxide preparations, a pea-sized amount should be dispensed onto the finger, dabbed over the face, and spread in evenly. If dryness and irritation are severe, the medication can be applied every other night for several weeks until the skin adjusts. Application of a noncomedogenic moisturizer should be encouraged if tolerability is an issue. In addition, it is important to counsel patients to use a gentle cleanser, avoid harsh scrubs or astringents, and be cautious with wax hair removal or laser therapy on treated areas.

Patients must be warned that temporary worsening of acne can occur within the first month of starting

treatment and does not indicate medication failure. They should continue to treat through this phase, which will resolve spontaneously with continued medication use. They also may have increased sensitivity to sunlight and should be diligent about sun protection.

TOPICAL ANTIBIOTICS. Topical antibiotics reduce concentrations of *P. acnes* and inflammatory mediators, making them useful in treating mild to moderate inflammatory acne. In the United States, clindamycin and erythromycin are available in a number of topical formulations and have comparable efficacy. Sodium sulfacetamide is available also and is especially useful in patients whose acne has a rosacea component. (47) Dapsone gel, 5%, is a newer topical agent that has demonstrated efficacy against comedonal and inflammatory lesions. (48)(49) Patients do not need glucose-6-phosphate dehydrogenase testing before using it, although clinically insignificant hemolysis may occur in glucose-6-phosphate dehydrogenase-deficient patients. (50) Temporary orange or yellow discoloration of skin may occur if applied concomitantly with benzoyl peroxide and usually can be avoided by applying the medications at different times during the day. (51)

Antibiotics are well tolerated but should not be used as monotherapy because of increasing antibiotic resistance. Concurrent therapy with benzoyl peroxide reduces this problem, and several commercial combinations of benzoyl peroxide, 2.5% to 5%, with clindamycin or erythromycin are marketed. These conditions demonstrate greater efficacy than either drug alone. (38)(39)(52)(53)(54) If cost is an issue, OTC benzoyl peroxide and topical erythromycin or clindamycin can be used simultaneously in the morning. (55) Use in conjunction with a nightly retinoid also will speed the response by allowing greater penetration of the medication. In patients with mixed comedonal and inflammatory acne, the topical antibiotic should be used in combination with a topical retinoid and benzoyl peroxide.

SALICYLIC ACID. Salicylic acid is another common active ingredient in many different OTC formulations: washes, gels, creams, and pads. Salicylic acid is primarily a gentle comedolytic that can be useful in mild comedonal acne. It is less effective than topical retinoids but also better tolerated.

AZELAIC ACID. Azelaic acid is a dicarboxylic acid manufactured as a 20% topical cream that can be of benefit in mild inflammatory and comedonal acne. Azelaic acid reverses abnormal keratinization and inhibits the growth of *P. acnes*. (56) It also lightens postinflammatory hyperpigmentation. Azelaic acid is remarkably well tolerated.

When adverse effects occur, they usually are mild and include pruritus, tingling, burning, or erythema. With long-term use, azelaic acid can cause hypopigmentation, which may be problematic for darker-skinned patients. Azelaic acid is a good choice for patients who do not tolerate retinoids or as an adjunctive treatment in patients with prominent postinflammatory hyperpigmentation. (57)

Oral Therapies

SYSTEMIC ANTIBIOTICS. Oral antibiotics are the most common type of systemic acne therapy. They are effective for treating moderate or severe inflammatory acne. Antibiotics act via several mechanisms: decreasing *P. acnes*, inhibiting bacterial lipases, suppressing neutrophil chemotaxis (and therefore follicular inflammation), and reducing free fatty acid concentrations in sebum. (58) (59)(60)(61)(62) Tetracycline-class antibiotics are prescribed most commonly because they have documented efficacy and a long history of use in acne. (63)(64)(65) Other antibiotics, including erythromycin, clindamycin, trimethoprim-sulfamethoxazole, azithromycin, and cephalixin, should be reserved for select patients. Dosing, formulations, and possible adverse effects for the most commonly used oral antibiotics are described in Table 5.

General guidelines for oral antibiotic use in patients with acne include avoiding the oral agent if a topical agent will suffice and avoiding concomitant oral and topical treatment with dissimilar antibiotics to avoid emergence of cross-resistant *P. acnes*. (66) As with topical therapies, oral antibiotics require 8 to 12 weeks to achieve their maximum effect. Once disease activity has diminished and an effective topical combination routine is established, use of the antibiotic can be discontinued.

In patients who do not respond to oral antibiotics, the possibility of resistant *P. acnes* should be considered. To avoid development of resistant strains, patients should concomitantly use a benzoyl peroxide product while taking oral antibiotics. A multipronged approach to acne using benzoyl peroxide, a topical retinoid, and an oral antibiotic often is referred to as triple therapy. Patients who are also using hormonal birth control can be reassured that the antibiotics used to treat acne will not decrease birth control efficacy. (67) Overall, the commonly used antibiotics for acne are well tolerated, adverse effects are uncommon and typically reversible, and laboratory monitoring is not necessary.

Tetracycline-class antibiotics are the criterion standard of oral antibiotic therapy for acne. In the past, tetracycline itself was used traditionally because of its efficacy, safety, and affordability. The most commonly experienced adverse effect with tetracycline is gastrointestinal upset because the

medication cannot be taken with milk or food for adequate amounts to be absorbed into the body (ie, take at least 30 minutes before a meal or 2 hours after a meal). There is a risk of phototoxicity, and vaginitis or perianal itching secondary to *Candida albicans* occurs in roughly 5% of patients. To reduce the incidence of esophagitis, all of the tetracycline-class antibiotics should be taken with a full glass of water well before bedtime or lying down. Pseudotumor cerebri can complicate tetracycline-class therapy rarely. None of the tetracycline-class antibiotics are approved for use in children younger than 9 years or pregnant women because these drugs can cause tooth discoloration and bony abnormalities.

Recently, tetracycline shortages due to manufacturer delays have led to increased use of doxycycline and minocycline in treating acne. Doxycycline, like tetracycline, is also highly efficacious and inexpensive. (68) Photosensitivity reactions are more common than with other tetracyclines, and patients must be cautioned to use meticulous sun protection. One advantage of doxycycline is that it can be taken with food, which greatly decreases the incidence of gastrointestinal disturbances. This point should be emphasized with patients because many pharmacies place a “take on an empty stomach” label on all tetracycline-class antibiotics regardless of the specific drug prescribed. Taking doxycycline with food significantly increases its tolerability and hence patient adherence.

Minocycline is also used commonly in the treatment of acne. Minocycline generally is more expensive than the other tetracyclines. As a lipophilic derivative of tetracycline, its efficacy may be due to deeper penetration of the sebaceous follicle. (69) Minocycline also can be taken with food, and photosensitivity is rare. However, vertigo, dizziness, and headaches may occur. Rarely, a bluish dyspigmentation of oral tissues, nails, scars, teeth, and sclera can occur. Additional potentially serious but typically reversible adverse effects include a lupuslike syndrome, drug hypersensitivity reactions, autoimmune hepatitis, and serum sickness-like reactions. Although rare, these adverse effects should be discussed with patients and their families when minocycline is being considered.

For those patients who cannot take tetracyclines because of drug allergy, young age, or pregnancy, erythromycin can be considered. Gastrointestinal discomfort is common, but otherwise there are few adverse effects. Phototoxicity is not a concern. Efficacy is low compared with tetracycline-class antibiotics, and bacterial resistance limits the usefulness of erythromycin. (70)

ORAL CONTRACEPTIVE PILLS. Combined oral contraceptive pills that contain estrogen and progesterone are

Table 5. Oral Antibiotics Commonly Used to Treat Acne

Oral Antibiotics					
Class of Antibiotic	Drug	Brand*: Available Strengths and Formulations	Directions	Potential Adverse Effects and Comments	
Tetracyclines	Tetracycline	Tetracycline hydrochloride (generic): 250-mg, 500-mg capsule	250–500 mg daily to twice daily	Dental staining <8 years old Decreased absorption with dairy products or food Gastrointestinal upset Photosensitivity Vulvovaginal candidiasis Pseudotumor cerebri (rare) Recent unavailability	
		Minocycline	Minocin [®] : 50-mg, 75-mg, 100-mg capsule Dynacin [®] : 50-mg, 75-mg, 100-mg tablet	50–100 mg daily to twice daily Extended-release dosing	Dental staining <8 years old Gastrointestinal upset (less discomfort but still efficacious if take with food)
	Doxycycline	Solodyn [®] : 45-mg, 65-mg, 90-mg, 115-mg, 135-mg extended-release tablet	45–54 kg: 45 mg once daily	Photosensitivity less common than with other tetracyclines	
			Minocycline hydrochloride (generic): 50-mg, 75-mg, 100-mg tablet; 45-mg, 90-mg, 135-mg extended-release tablet	55–77 kg: 65 mg once daily 78–102 kg: 90 mg once daily 103–125 kg: 115 mg once daily 126–136 kg: 135 mg once daily	Blue-gray skin pigmentation Vulvovaginal candidiasis Lupuslike reaction (rare) Pseudotumor cerebri (rare)
		Doxycycline hyclate	100 mg daily to twice daily	Dental staining <8 years old	
			Vibramycin [®] : 50-mg/5-mL syrup, 100-mg capsule	Delayed release: 150 mg daily	Gastrointestinal upset (less discomfort but still efficacious if take with food)
			Doryx [®] : 150-mg delayed-release tablet		Esophagitis: take pills with full glass of liquid
			Doxycycline hyclate (generic): 50-mg, 100-mg capsule; 150-mg delayed release tablet		Photosensitivity
		Doxycycline monohydrate	Adoxa [®] : 150-mg capsule		Photo-onycholysis
			Monodox [®] : 50-mg, 75-mg, 100-mg capsule		Vulvovaginal candidiasis Pseudotumor cerebri (rare)
Doxycycline monohydrate (generic): 50-mg, 75-mg, 100-mg, 150-mg tablet or capsule					
Macrolides	Erythromycin	Erythromycin base	Child	Gastrointestinal upset common	
		Ery-Tab [®] : 250-mg, 333-mg, 500-mg delayed-release tablet	30–50 mg/kg/d divided every 6–8 hours; do not exceed 2 g/d (as base or stearate)	Used in younger children and tetracycline-allergic patients	

Continued

Table 5. (Continued)

Oral Antibiotics				
Class of Antibiotic	Drug	Brand*: Available Strengths and Formulations	Directions	Potential Adverse Effects and Comments
		PCE [®] : 333-mg, 500-mg tablet	or 3.2 g/d (as ethylsuccinate) Adolescent/adult	Vulvovaginal candidiasis
		Erythromycin base (generic): 250-mg, 500-mg tablet; 250-mg delayed-release capsule	Base or stearate: 250-500 mg every 6-12 hours	
		Erythromycin ethylsuccinate	Base, delayed release: 333 mg every 8 hours	
		E.E.S. [®] : 200-mg/5-mL suspension, 400-mg tablet	Ethylsuccinate: 400-800 mg every 6-12 hours	
		EryPed [®] : 200-mg/5-mL, 400-mg/5-mL suspension		
		Erythromycin ethylsuccinate (generic): 400-mg tablet		
		Erythromycin stearate		
		Erythrocin [®] : 250-mg, 500-mg tablet		

Medications listed are examples; the list is not intended to be exhaustive.
 *Manufacturer and location of brand name medications: Adoxa[®] (PharmaDerm, Florham Park, NJ); Doryx[®] (Warner Chilcott Laboratories, Dublin, Ireland); Dynacin[®], Solodyn[®] (Medicis Pharmaceuticals Corp, Scottsdale, AZ); Ery-tab[®], Erythrocin[®], PCE[®], E.E.S.[®], EryPed[®] (Arbor Pharmaceuticals, Atlanta, GA); Minocin[®] (Onset Dermatologics, Cumberland, RI); Monodox[®] (Aqua Pharmaceuticals, West Chester, PA); and Vibramycin[®] (Pfizer, Inc, New York, NY).

another treatment option for female patients with acne, regardless of whether serum androgen levels are abnormal. The primary goal of these therapies is to oppose the effects of androgens on the sebaceous glands. Currently, ethinyl estradiol–norgestimate, ethinyl estradiol–norethindrone, and ethinyl estradiol–drospirenone are approved by the FDA for use in the treatment of acne vulgaris, although many other oral contraceptives that contain estrogen and progesterone are efficacious as well. Results often take at least 3 months to become apparent and usually are maximal by 6 months. Acne may be exacerbated by endocrine disorders, such as polycystic ovarian syndrome or metabolic syndrome, and combined oral contraceptive pills may be particularly useful in these settings. Use of long-acting progestin implants or depot medroxyprogesterone acetate may actually worsen acne.

ISOTRETINOIN. Isotretinoin is an orally administered vitamin A derivative that is highly effective in treating recalcitrant nodulocystic acne and is the only acne therapy that has curative potential. The exact mechanism of

action is unknown, but isotretinoin markedly inhibits sebum synthesis, decreases *P. acnes* concentration, inhibits neutrophil chemotaxis, and has comedolytic effects. (71)(72)(73) Because it is a potent teratogen, the FDA mandates that only authorized physicians can prescribe isotretinoin and that all patients taking isotretinoin must enroll in a monitoring program with monthly clinic visits that, for female patients, include pregnancy tests.

Isotretinoin is the most effective drug for treatment of severe acne unresponsive to conventional therapy and can clear even severe acne in a 5- to 6-month treatment course. (74)(75) Many patients will remain clear after finishing therapy. For those whose acne recurs, the condition often can be managed with the conventional therapies that had failed previously.

Nearly all patients will experience generalized skin dryness while using isotretinoin, and cholesterol and liver enzyme abnormalities are common. A number of more serious adverse events, such as suicidal ideation, major depressive disorder, and inflammatory bowel disease, have been attributed to isotretinoin, although data implying causation are lacking. (76)(77)(78) Pediatricians should

be aware of these associations and the other adverse effects of isotretinoin.

Scar Treatments

Although an in-depth discussion of scar therapy is beyond the scope of this article, many patients are concerned about scarring, and clinicians must be aware that therapeutic options exist. Often, patients mistake postinflammatory hyperpigmentation and the macular erythema of resolving lesions for scarring. In these instances, the patient can be reassured that these color changes will fade over time but may require up to a year to diminish. Actual scars will continue to remodel for several years, gradually becoming subtler and less noticeable, although they will not disappear fully.

For deeper scars, options include chemical peels, microdermabrasion, injections, punch excision, or laser resurfacing. (79)(80)(81)(82)(83) Acne should be well controlled before scar-reducing procedures are pursued. Historically, patients treated with isotretinoin were counseled to avoid dermabrasion and other resurfacing techniques until 6 to 12 months after completion of therapy because of the perceived risk of developing excessive wound healing or keloidal scarring. (84)(85) Several recent studies, however, contradict these data and support the safety and efficacy of earlier intervention. (86)(87) Needless to say, patients interested in acne scar treatment should consult a specialist who has expertise using these therapies, such as a plastic surgeon or cosmetic dermatologist.

Follow-up and Maintenance

Most patients with acne should be seen 3 to 4 months after initiating a therapeutic regimen, although patients should be encouraged to contact the office sooner if questions or concerns arise regarding the appropriate use of their medications or adverse effects. This interval gives the medications ample time to achieve their maximum benefit and allows the clinician to judge their efficacy at follow-up, as long as the patient has been diligent about their use. If there is minimal or no response, inquiring into when and how the patient is using the medicines can help distinguish medication failure from nonadherence. If they are not using a medication, find out why. Often, a lower-strength or different vehicle can make a huge difference. For recalcitrant acne, consider referral to a dermatologist.

Once an effective therapeutic regimen has been established, maintenance of improvement becomes the focus. Topical acne medications are safe to use indefinitely and are the preferred long-term maintenance medications. (66)(88) Oral antibiotics generally should be used for

up to 6 to 12 weeks to get an adequate response but should be tapered thereafter as quickly as can be tolerated by the patient. (89)

Emotional Considerations

Acne is never inconsequential or trivial to those it affects and should not be dismissed as such. The psychological effect of this disease often is far greater than the blemishes on the skin would suggest, and what may seem minimal to a clinician can be devastating to the patient. Current treatment regimens focus on combination therapies to ensure the quickest and most effective results. Therefore, it is important that primary care physicians be current on acne standards of care to ensure the best outcomes for their patients.

Summary

- Acne is a common and distressing disorder that can affect patients of all ages and may persist beyond adolescence.
- Acne is a multifactorial disease in which follicular obstruction, androgens, inflammation, genetics, and bacteria all play a role.
- Current evidence does not definitively support the role of diet in acne. At this time, the consensus of pediatric dermatologists is not to restrict the diet based on the presence of acne. This practice may change as more clinical trials directly evaluating the role of diet in acne are conducted.
- Studies show that most patients with acne have normal hormone levels. Red flags that obligate an endocrine evaluation include treatment-resistant acne, acute acne onset or worsening, additional clinical indicators of androgen excess, and acne in patients 2 to 7 years old.
- There are no universally accepted published guidelines for determination of the severity of acne. Clinical judgment, number of papulopustules, body areas affected, the presence or absence of scarring and cysts, and patient distress all contribute to categorization and subsequent management strategies.
- Triple therapy, which consists of benzoyl peroxide, a topical retinoid, and an oral antibiotic, often is highly effective in treating moderate to severe acne.
- Topical retinoids are central to acne management and are the preferred maintenance medication for all patients with acne.

References

1. Fleischer AB Jr, Feldman SR, Rapp SR. Introduction: the magnitude of skin disease in the United States. *Dermatol Clin*. 2000;18(2):xv-xxi

2. Stern RS. Dermatologists and office-based care of dermatologic disease in the 21st century. *J Invest Dermatol Symp Proc*. 2004;9(2):126–130
3. Yentzer BA, Hick J, Reese EL, Uhas A, Feldman SR, Balkrishnan R. Acne vulgaris in the United States: a descriptive epidemiology. *Cutis*. 2010;86(2):94–99
4. Bickers DR, Lim HW, Margolis D, et al; American Academy of Dermatology Association; Society for Investigative Dermatology. The burden of skin diseases: 2004 a joint project of the American Academy of Dermatology Association and the Society for Investigative Dermatology. *J Am Acad Dermatol*. 2006;55(3):490–500
5. Goulden V, Stables GI, Cunliffe WJ. Prevalence of facial acne in adults. *J Am Acad Dermatol*. 1999;41(4):577–580
6. Collier CN, Harper JC, Cafardi JA, et al. The prevalence of acne in adults 20 years and older [published correction appears in *J Am Acad Dermatol*. 2008;58(5):874]. *J Am Acad Dermatol*. 2008;58(1):56–59
7. Freedberg IM, Tomic-Canic M, Komine M, Blumenberg M. Keratins and the keratinocyte activation cycle. *J Invest Dermatol*. 2001;116(5):633–640
8. Levell MJ, Cawood ML, Burke B, Cunliffe WJ. Acne is not associated with abnormal plasma androgens. *Br J Dermatol*. 1989;120(5):649–654
9. van der Meeren HL, Thijssen JH. Circulating androgens in male acne. *Br J Dermatol*. 1984;110(5):609–611
10. Chronnell CM, Ghali LR, Ali RS, et al. Human beta defensin-1 and -2 expression in human pilosebaceous units: upregulation in acne vulgaris lesions. *J Invest Dermatol*. 2001;117(5):1120–1125
11. Nagy I, Pivarcsi A, Kis K, et al. Propionibacterium acnes and lipopolysaccharide induce the expression of antimicrobial peptides and proinflammatory cytokines/chemokines in human sebocytes. *Microbes Infect*. 2006;8(8):2195–2205
12. Yamasaki K, Di Nardo A, Bardan A, et al. Increased serine protease activity and cathelicidin promotes skin inflammation in rosacea. *Nat Med*. 2007;13(8):975–980
13. Jugeau S, Tenaud I, Knol AC, et al. Induction of toll-like receptors by Propionibacterium acnes. *Br J Dermatol*. 2005;153(6):1105–1113
14. Kim J, Ochoa MT, Krutzik SR, et al. Activation of toll-like receptor 2 in acne triggers inflammatory cytokine responses. *J Immunol*. 2002;169(3):1535–1541
15. Vowels BR, Yang S, Leyden JJ. Induction of proinflammatory cytokines by a soluble factor of Propionibacterium acnes: implications for chronic inflammatory acne. *Infect Immun*. 1995;63(8):3158–3165
16. Karvonen SL, Räsänen L, Cunliffe WJ, Holland KT, Karvonen J, Reunala T. Delayed hypersensitivity to Propionibacterium acnes in patients with severe nodular acne and acne fulminans. *Dermatology*. 1994;189(4):344–349
17. Bataille V, Snieder H, MacGregor AJ, Sasieni P, Spector TD. The influence of genetics and environmental factors in the pathogenesis of acne: a twin study of acne in women. *J Invest Dermatol*. 2002;119(6):1317–1322
18. Szabó K, Kemény L. Studying the genetic predisposing factors in the pathogenesis of acne vulgaris. *Hum Immunol*. 2011;72(9):766–773
19. Du-Thanh A, Kluger N, Bensalleh H, Guillot B. Drug-induced acneiform eruption. *Am J Clin Dermatol*. 2011;12(4):233–245
20. Bett DG, Morland J, Yudkin J. Sugar consumption in acne vulgaris and seborrhoeic dermatitis. *BMJ*. 1967;3(5558):153–155
21. Bourne S, Jacobs A. Observations on acne, seborrhoea, and obesity. *BMJ*. 1956;1(4978):1268–1270
22. Fulton JE Jr, Plewig G, Kligman AM. Effect of chocolate on acne vulgaris. *JAMA*. 1969;210(11):2071–2074
23. Magin P, Pond D, Smith W, Watson A. A systematic review of the evidence for 'myths and misconceptions' in acne management: diet, face-washing and sunlight. *Fam Pract*. 2005;22(1):62–70
24. Eichenfield LF, Krakowski AC, Piggott C, Del Rosso J, Baldwin H, Friedlander SF, Levy M, Lucky A, Mancini AJ, Orlow SJ, Yan AC, Vaux KK, Webster G, Zaenglein AL, Thiboutot DM. Evidence-based recommendations for the diagnosis and treatment of pediatric acne. *Pediatrics*. 2013 May;131 Suppl 3:S163–86
25. Jansen T, Burgdorf WH, Plewig G. Pathogenesis and treatment of acne in childhood. *Pediatr Dermatol*. 1997;14(1):17–21
26. Cunliffe WJ, Baron SE, Coulson IH. A clinical and therapeutic study of 29 patients with infantile acne. *Br J Dermatol*. 2001;145(3):463–466
27. Hello M, Prey S, Léauté-Labrèze C, et al. Infantile acne: a retrospective study of 16 cases. *Pediatr Dermatol*. 2008;25(4):434–438
28. Lucky AW. A review of infantile and pediatric acne. *Dermatology*. 1998;196(1):95–97
29. Allison MA, Dunn CL, Person DA. Acne fulminans treated with isotretinoin and "pulse" corticosteroids. *Pediatr Dermatol*. 1997;14(1):39–42
30. Iqbal M, Kolodney MS. Acne fulminans with synovitis-acne-pustulosis-hyperostosis-osteitis (SAPHO) syndrome treated with infliximab. *J Am Acad Dermatol*. 2005;52(5 Suppl 1):S118–S120
31. Lages RB, Bona SH, Silva FV, Gomes AK, Campelo V. Acne fulminans successfully treated with prednisone and dapson. *An Bras Dermatol*. 2012;87(4):612–614
32. Tago O, Nagai Y, Matsushima Y, Ishikawa O. A case of acne fulminans successfully treated with cyclosporin a and prednisolone. *Acta Derm Venereol*. 2011;91(3):337–338
33. Woolfson H. Acne fulminans with circulating immune complexes and leukaemoid reaction treated with steroids and azathioprine. *Clin Exp Dermatol*. 1987;12(6):463–466
34. Bulengo-Ransby SM, Griffiths CE, Kimbrough-Green CK, et al. Topical tretinoin (retinoic acid) therapy for hyperpigmented lesions caused by inflammation of the skin in black patients. *N Engl J Med*. 1993;328(20):1438–1443
35. Cantatore-Francis JL, Glick SA. Childhood acne: evaluation and management. *Dermatol Ther*. 2006;19(4):202–209
36. Yentzer BA, McClain RW, Feldman SR. Do topical retinoids cause acne to "flare"? *J Drugs Dermatol*. 2009;8(9):799–801
37. Yentzer BA, Ade RA, Fountain JM, et al. Simplifying regimens promotes greater adherence and outcomes with topical acne medications: a randomized controlled trial. *Cutis*. 2010;86(2):103–108
38. Cunliffe WJ, Holland KT, Bojar R, Levy SF. A randomized, double-blind comparison of a clindamycin phosphate/benzoyl peroxide gel formulation and a matching clindamycin gel with respect to microbiologic activity and clinical efficacy in the topical treatment of acne vulgaris. *Clin Ther*. 2002;24(7):1117–1133
39. Eady EA, Bojar RA, Jones CE, Cove JH, Holland KT, Cunliffe WJ. The effects of acne treatment with a combination of benzoyl peroxide and erythromycin on skin carriage of erythromycin-resistant propionibacteria. *Br J Dermatol*. 1996;134(1):107–113
40. Eady EA, Farmery MR, Ross JI, Cove JH, Cunliffe WJ. Effects of benzoyl peroxide and erythromycin alone and in combination against antibiotic-sensitive and -resistant skin bacteria from acne patients. *Br J Dermatol*. 1994;131(3):331–336

41. Bikowski JB. Mechanisms of the comedolytic and anti-inflammatory properties of topical retinoids. *J Drugs Dermatol*. 2005;4(1):41–47
42. Dai X, Yamasaki K, Shirakata Y, Sayama K, Hashimoto K. All-trans-retinoic acid induces interleukin-8 via the nuclear factor-kappaB and p38 mitogen-activated protein kinase pathways in normal human keratinocytes. *J Invest Dermatol*. 2004;123(6):1078–1085
43. Varani J, Fisher GJ, Kang S, Voorhees JJ. Molecular mechanisms of intrinsic skin aging and retinoid-induced repair and reversal. *J Invest Dermatol Symp Proc*. 1998;3(1):57–60
44. Shroet B, Michel S. Pharmacology and chemistry of adapalene. *J Am Acad Dermatol*. 1997;36(6 Pt 2):S96–S103
45. Cunliffe WJ, Poncet M, Loesche C, Verschoore M. A comparison of the efficacy and tolerability of adapalene 0.1% gel versus tretinoin 0.025% gel in patients with acne vulgaris: a meta-analysis of five randomized trials. *Br J Dermatol*. 1998;139(suppl 52):48–56
46. Wolf JE. An update of recent clinical trials examining adapalene and acne. *J Eur Acad Dermatol Venereol*. 2001;15(suppl 3):23–29
47. Torok HM, Webster G, Dunlap FE, Egan N, Jarratt M, Stewart D. Combination sodium sulfacetamide 10% and sulfur 5% cream with sunscreens versus metronidazole 0.75% cream for rosacea. *Cutis*. 2005;75(6):357–363
48. Draelos ZD, Carter E, Maloney JM, et al. Two randomized studies demonstrate the efficacy and safety of dapsone gel, 5% for the treatment of acne vulgaris. *J Am Acad Dermatol*. 2007;56(3):439e1–e10.
49. Lucky AW, Maloney JM, Roberts J, et al; Dapsone Gel Long-Term Safety Study Group. Dapsone gel 5% for the treatment of acne vulgaris: safety and efficacy of long-term (1 year) treatment. *J Drugs Dermatol*. 2007;6(10):981–987
50. Piette WW, Taylor S, Pariser D, Jarratt M, Sheth P, Wilson D. Hematologic safety of dapsone gel, 5%, for topical treatment of acne vulgaris. *Arch Dermatol*. 2008;144(12):1564–1570
51. Dubina MI, Fleischer AB Jr. Interaction of topical sulfacetamide and topical dapsone with benzoyl peroxide. *Arch Dermatol*. 2009;145(9):1027–1029
52. Leyden JJ, Del Rosso JQ, Webster GF. Clinical considerations in the treatment of acne vulgaris and other inflammatory skin disorders: a status report. *Dermatol Clin*. 2009;27(1):1–15
53. Thiboutot D, Zaenglein A, Weiss J, Webster G, Calvaresi B, Chen D. An aqueous gel fixed combination of clindamycin phosphate 1.2% and benzoyl peroxide 2.5% for the once-daily treatment of moderate to severe acne vulgaris: assessment of efficacy and safety in 2813 patients. *J Am Acad Dermatol*. 2008;59(5):792–800
54. Webster GF, Graber EM. Antibiotic treatment for acne vulgaris. *Semin Cutan Med Surg*. 2008;27(3):183–187
55. Draelos ZD, Shalita AR, Thiboutot D, Oresajo C, Yatskayer M, Raab S. A multicenter, double-blind study to evaluate the efficacy and safety of 2 treatments in participants with mild to moderate acne vulgaris. *Cutis*. 2012;89(6):287–293
56. Cunliffe WJ, Holland KT. Clinical and laboratory studies on treatment with 20% azelaic acid cream for acne. *Acta Derm Venereol Suppl (Stockh)*. 1989;143:31–34
57. Kircik LH. Efficacy and safety of azelaic acid (AzA) gel 15% in the treatment of post-inflammatory hyperpigmentation and acne: a 16-week, baseline-controlled study. *J Drugs Dermatol*. 2011;10(6):586–590
58. Beveridge GW, Powell EW. Sebum changes in acne vulgaris treated with tetracycline. *Br J Dermatol*. 1969;81(7):525–527
59. Del Rosso JQ. A status report on the use of subantimicrobial-dose doxycycline: a review of the biologic and antimicrobial effects of the tetracyclines. *Cutis*. 2004;74(2):118–122
60. Esterly NB, Koransky JS, Furey NL, Trevisan M. Neutrophil chemotaxis in patients with acne receiving oral tetracycline therapy. *Arch Dermatol*. 1984;120(10):1308–1313
61. Sapadin AN, Fleischmajer R. Tetracyclines: nonantibiotic properties and their clinical implications. *J Am Acad Dermatol*. 2006;54(2):258–265
62. Skidmore R, Kovach R, Walker C, et al. Effects of subantimicrobial-dose doxycycline in the treatment of moderate acne. *Arch Dermatol*. 2003;139(4):459–464
63. Dreno B, Moysé D, Alirezai M, et al; Acne Research and Study Group. Multicenter randomized comparative double-blind controlled clinical trial of the safety and efficacy of zinc gluconate versus minocycline hydrochloride in the treatment of inflammatory acne vulgaris. *Dermatology*. 2001;203(2):135–140
64. Fry L, Ramsay CA. Tetracycline in acne vulgaris: clinical evaluation and the effect of sebum production. *Br J Dermatol*. 1966;78(12):653–660
65. Lane P, Williamson DM. Treatment of acne vulgaris with tetracycline hydrochloride: a double-blind trial with 51 patients. *BMJ*. 1969;2(5649):76–79
66. Zaenglein AL, Thiboutot DM. Expert committee recommendations for acne management. *Pediatrics*. 2006;118(3):1188–1199
67. Helms SE, Bredle DL, Zajic J, Jarjoura D, Brodell RT, Krishnarao I. Oral contraceptive failure rates and oral antibiotics. *J Am Acad Dermatol*. 1997;36(5 Pt 1):705–710
68. Plewig G, Petrozzi JW, Berendes U. Double-blind study of doxycycline in acne vulgaris. *Arch Dermatol*. 1970;101(4):435–438
69. Hubbell CG, Hobbs ER, Rist T, White JW Jr. Efficacy of minocycline compared with tetracycline in treatment of acne vulgaris. *Arch Dermatol*. 1982;118(12):989–992
70. Strauss JS, Krowchuk DP, Leyden JJ, et al; American Academy of Dermatology/American Academy of Dermatology Association. Guidelines of care for acne vulgaris management. *J Am Acad Dermatol*. 2007;56(4):651–663
71. Leyden JJ, McGinley KJ. Effect of 13-cis-retinoic acid on sebum production and *Propionibacterium acnes* in severe nodulocystic acne. *Arch Dermatol Res*. 1982;272(3-4):331–337
72. Leyden JJ, McGinley KJ, Foglia AN. Qualitative and quantitative changes in cutaneous bacteria associated with systemic isotretinoin therapy for acne conglobata. *J Invest Dermatol*. 1986;86(4):390–393
73. Stewart ME, Benoit AM, Stranieri AM, Rapini RP, Strauss JS, Downing DT. Effect of oral 13-cis-retinoic acid at three dose levels on sustainable rates of sebum secretion and on acne. *J Am Acad Dermatol*. 1983;8(4):532–538
74. Strauss JS. Isotretinoin (Accutane) for the management of severe nodulocystic acne. *Iowa Med*. 1984;74(4):170–172
75. Strauss JS, Rapini RP, Shalita AR, et al. Isotretinoin therapy for acne: results of a multicenter dose-response study. *J Am Acad Dermatol*. 1984;10(3):490–496
76. Bernstein CN, Nugent Z, Longobardi T, Blanchard JF. Isotretinoin is not associated with inflammatory bowel disease: a population-based case-control study. *Am J Gastroenterol*. 2009;104(11):2774–2778
77. Crockett SD, Porter CQ, Martin CF, Sandler RS, Kappelman MD. Isotretinoin use and the risk of inflammatory bowel disease: a case-control study. *Am J Gastroenterol*. 2010;105(9):1986–1993
78. McGrath EJ, Lovell CR, Gillison F, Darvay A, Hickey JR, Skevington SM. A prospective trial of the effects of isotretinoin on

quality of life and depressive symptoms. *Br J Dermatol*. 2010;163(6):1323–1329

79. Cho SB, Lee JH, Choi MJ, Lee KY, Oh SH. Efficacy of the fractional photothermolysis system with dynamic operating mode on acne scars and enlarged facial pores. *Dermatol Surg*. 2009;35(1):108–114

80. Hu S, Chen MC, Lee MC, Yang LC, Keoprasom N. Fractional resurfacing for the treatment of atrophic facial acne scars in asian skin. *Dermatol Surg*. 2009;35(5):826–832

81. Lee DH, Choi YS, Min SU, Yoon MY, Suh DH. Comparison of a 585-nm pulsed dye laser and a 1064-nm Nd:YAG laser for the treatment of acne scars: a randomized split-face clinical study. *J Am Acad Dermatol*. 2009;60(5):801–807

82. Leheta T, El Tawdy A, Abdel Hay R, Farid S. Percutaneous collagen induction versus full-concentration trichloroacetic acid in the treatment of atrophic acne scars. *Dermatol Surg*. 2011;37(2):207–216

83. Min SU, Choi YS, Lee DH, Yoon MY, Suh DH. Comparison of a long-pulse Nd:YAG laser and a combined 585/1,064-nm laser for the treatment of acne scars: a randomized split-face clinical study. *Dermatol Surg*. 2009;35(11):1720–1727

84. Bernestein LJ, Geronemus RG. Keloid formation with the 585-nm pulsed dye laser during isotretinoin treatment. *Arch Dermatol*. 1997;133(1):111–112

85. Zachariae H. Delayed wound healing and keloid formation following argon laser treatment or dermabrasion during isotretinoin treatment. *Br J Dermatol*. 1988;118(5):703–706

86. Bagatin E, dos Santos Guadanhim LR, Yarak S, Kamamoto CS, de Almeida FA. Dermabrasion for acne scars during treatment with oral isotretinoin. *Dermatol Surg*. 2010;36(4):483–489

87. Picosse FR, Yarak S, Cabral NC, Bagatin E. Early chemabrasion for acne scars after treatment with oral isotretinoin. *Dermatol Surg*. 2012;38(9):1521–1526

88. Thiboutot DM, Shalita AR, Yamauchi PS, et al. Adapalene gel, 0.1%, as maintenance therapy for acne vulgaris: a randomized, controlled, investigator-blind follow-up of a recent combination study. *Arch Dermatol*. 2006;142(5):597–602

89. Thiboutot D, Gollnick H, Bettoli V, et al; Global Alliance to Improve Outcomes in Acne. New insights into the management of acne: an update from the Global Alliance to Improve Outcomes in Acne group. *J Am Acad Dermatol*. 2009;60(5 suppl):S1–S50

PIR Quiz

This quiz is available online at <http://pedsinreview.org>. NOTE: Learners can take *Pediatrics in Review* quizzes and claim credit online only. No paper answer form will be printed in the journal.

New Minimum Performance Level Requirements

Per the 2010 revision of the American Medical Association (AMA) Physician's Recognition Award (PRA) and credit system, a minimum performance level must be established on enduring material and journal-based CME activities that are certified for *AMA PRA Category 1 Credit™*. In order to successfully complete 2013 *Pediatrics in Review* articles for *AMA PRA Category 1 Credit™*, learners must demonstrate a minimum performance level of 60% or higher on this assessment, which measures achievement of the educational purpose and/or objectives of this activity.

In *Pediatrics in Review*, *AMA PRA Category 1 Credit™* may be claimed only if 60% or more of the questions are answered correctly. If you score less than 60% on the assessment, you will be given additional opportunities to answer questions until an overall 60% or greater score is achieved.

1. A 4-month-old otherwise healthy female presents with a facial rash consisting of comedones. Of the following, which is the most appropriate initial management for this infant?
 - A. Azithromycin by mouth.
 - B. Isotretinoin by mouth.
 - C. Ketoconazole cream.
 - D. No treatment at this time.
 - E. Tretinoin and benzoyl peroxide creams.
2. A 14-year-old female has comedones, papules, and pustules on her face and upper back. You prescribe a course of topical therapy to be applied once daily and schedule a return appointment to coincide with the time period in which improvement is expected. If the patient is compliant with treatment, how long after initial treatment is improvement expected?
 - A. One to two weeks.
 - B. Four to six weeks.
 - C. Eight to twelve weeks.
 - D. Four to five months.
 - E. Six to eight months.

3. A teenage patient who is using benzoyl peroxide for facial acne presents with pruritic erythematous papules and vesicles on her face. What is the most appropriate management for this patient?
- Apply a noncomedogenic emollient.
 - Decrease benzoyl peroxide from b.i.d. to once daily.
 - Decrease the strength of benzoyl peroxide.
 - Discontinue benzoyl peroxide and begin alternative therapy.
 - Discontinue benzoyl peroxide gel and begin the lotion form.
4. A 15-year-old boy has comedones and papules on his face and chest. What is the most appropriate initial course of treatment?
- Oral azithromycin.
 - Topical retinoid.
 - Topical retinoid and topical benzoyl peroxide.
 - Topical retinoid, topical benzoyl peroxide and oral azithromycin.
 - Topical retinoid, topical benzoyl peroxide and topical clindamycin.
5. LG is a 15-year-old otherwise healthy female athlete with acne who has erythematous papules and pustules on her face and chin. The girl's father inquires about what could be done to help with his daughter's problem. Which of the following interventions is most likely to be effective in improving LG's skin condition?
- Apply cocoa butter before bedtime.
 - Avoid fatty and fried foods.
 - Eliminate chocolate from her diet.
 - Increase frequency of face washing.
 - Remove hockey helmet in between plays.

HealthyChildren.org Parent Resources From the AAP

- English: <http://www.healthychildren.org/English/ages-stages/teen/Pages/Teens-and-Acne.aspx>
- Spanish: <http://www.healthychildren.org/spanish/ages-stages/teen/paginas/teens-and-acne.aspx>
- English: <http://www.healthychildren.org/English/ages-stages/teen/nutrition/Pages/Food-and-Adolescent-Acne.aspx>
- Spanish: <http://www.healthychildren.org/spanish/ages-stages/teen/nutrition/paginas/food-and-adolescent-acne.aspx>

Acne and Its Management
S. Alison Basak and Andrea L. Zaenglein
Pediatrics in Review 2013;34;479
DOI: 10.1542/pir.34-11-479

Updated Information & Services	including high resolution figures, can be found at: http://pedsinreview.aappublications.org/content/34/11/479
References	This article cites 89 articles, 8 of which you can access for free at: http://pedsinreview.aappublications.org/content/34/11/479#BIBL
Subspecialty Collections	This article, along with others on similar topics, appears in the following collection(s): Dermatology http://pedsinreview.aappublications.org/cgi/collection/dermatology_sub
Permissions & Licensing	Information about reproducing this article in parts (figures, tables) or in its entirety can be found online at: http://pedsinreview.aappublications.org/site/misc/Permissions.xhtml
Reprints	Information about ordering reprints can be found online: http://pedsinreview.aappublications.org/site/misc/reprints.xhtml

American Academy of Pediatrics

DEDICATED TO THE HEALTH OF ALL CHILDREN™

