

Neuroimaging: what neuroradiological features distinguish abusive from non-abusive head trauma?

A systematic review

A M Kemp,¹ T Jaspán,² J Griffiths,³ N Stoodley,⁴ M K Mann,⁵ V Tempest,⁶ S A Maguire²

¹School of Medicine, Cardiff University, Cardiff, UK

²Nottingham University Hospitals NHS Trust, Nottingham, UK

³Community Child Health, Abertawe Bro Morgannwg University Trust, Swansea, UK

⁴North Bristol NHS Trust, Bristol, UK

⁵Child Health, School of Medicine, Cardiff University, Cardiff, UK

⁶Support Unit for Research Evidence, Cardiff University, Cardiff, UK

Correspondence to

Professor Alison Kemp, School of Medicine, Cardiff University, UHW, Heath Park, Cardiff CF14 4XN, UK; kempam@cardiff.ac.uk

Accepted 11 August 2011

Published Online First 30 September 2011

ABSTRACT

Objectives To identify the evidence base behind the neuroradiological features that differentiate abusive head trauma (AHT) from non-abusive head trauma (nAHT).

Design Systematic review.

Setting Literature search of 14 databases, websites, textbooks, conference abstracts and references (1970–February 2010). Studies had two independent reviews (three if disputed) and critical appraisal.

Patients Primary comparative studies of children <11 years old hospitalised with AHT and nAHT diagnosed on CT or MRI.

Main outcome measures Neuroradiological features that differentiated AHT from nAHT.

Results 21 studies of children predominantly <3 years old were analysed. Subdural haemorrhages (SDH) were significantly associated with AHT (OR 8.2, 95% CI 6.1 to 11). Subarachnoid haemorrhages (EDH) were significantly associated with nAHT (OR for AHT 0.1, 95% CI 0.07 to 0.18). Multiple (OR 6, 95% CI 2.5 to 14.4), interhemispheric (OR 7.9, 95% CI 4.7 to 13), convexity (OR 4.9, 95% CI 1.3 to 19.4) and posterior fossa haemorrhages (OR 2.5, 95% CI 1 to 6) were associated with AHT. Hypoxic-ischaemic injury (HII) (OR 3.7, 95% CI 1.4 to 10) and cerebral oedema (OR 2.2, 95% CI 1.0 to 4.5) were significantly associated with AHT, while focal parenchymal injury was not a discriminatory feature. SDH of low attenuation were more common in AHT than in nAHT.

Conclusion Multiple SDH over the convexity, interhemispheric haemorrhages, posterior fossa SDH, HII and cerebral oedema are significantly associated with AHT and should be considered together with clinical features when identifying the condition.

INTRODUCTION

Abusive head trauma (AHT) is the most serious form of physical child abuse with an estimated annual incidence of 21 per 100 000 infants, an associated 30% mortality and 50% morbidity in survivors.¹ Studies estimate that 25–30% of children under the age of 2 years who are hospitalised with head injury have AHT.^{2–4} In the absence of a plausible explanation of non-intentional trauma, there is a strong likelihood of AHT, however making this diagnosis with confidence remains a challenge.

Neuroimaging is undertaken in these infants for clinical diagnostic purposes either because they present with unexplained neurological or encephalopathic signs or a history of head trauma,⁵ or

What is already known on this topic

- ▶ Abusive head trauma (AHT) is known to cause intracranial traumatic injury.
- ▶ Subdural haemorrhage (SDH) is an indicator of suspected AHT in infants presenting with unexplained traumatic head injury or where the explanation given is not plausible.
- ▶ Other intracranial injuries can coexist, however the weight of scientific evidence behind these features has yet to be defined.

What this study adds

- ▶ This is the first meta-analysis of neuroradiological features of AHT describing the evidence-base behind these features.
- ▶ Multiple SDH over the convexity, interhemispheric haemorrhages, posterior fossa SDH, hypoxic-ischaemic injury and cerebral oedema are significantly associated with AHT.
- ▶ Data to inform decisions about the likelihood of AHT in the clinical and legal child protection arenas are presented.

they are undergoing a comprehensive investigation for suspected physical abuse.⁶ The neuroimaging must be interpreted carefully, in the context of the historical or clinical features, giving due consideration to causes such as non intentional trauma, birth related injury, bleeding disorders, encephalitis, meningitis, congenital abnormality or metabolic conditions such as glutaric aciduria.⁷

CT and MRI techniques have advanced considerably over the past 30 years, facilitating the visualisation of extra-axial and intra-cerebral lesions in these children. Neuroradiologists describe various imaging patterns that are indicative of AHT. However, we are not aware of any published systematic reviews that evaluate the strength of the scientific evidence behind these features and have therefore conducted this systematic review and meta-analysis to identify and describe the weight of evidence behind neuroradiological features that are associated with AHT.

METHODS

We searched 14 databases, four websites, textbooks and conference abstracts (figure 1) with over 100 keyword combinations from 1970 to February

2010 (see online supplementary appendix 1). We performed a recursive search of the literature from reference lists of articles retrieved. Relevant foreign language articles were translated.

The literature includes a variety of terms for AHT, such as inflicted head trauma, non-accidental head injury, shaken baby syndrome and inflicted head injury. Our literature search encompassed all of these terms. However, for consistency we adopted the term AHT to describe “an inflicted injury to the head and its contents” in line with the recent proposal by the American Academy of Pediatrics Committee on Child Abuse and Neglect.⁸

Inclusion criteria were that the studies had to be published, peer reviewed, primary comparative studies of children under 11 years of age who were hospitalised with head injury and had AHT or non-abusive head trauma (nAHT). Studies were included where intra-cranial injury had been diagnosed on CT or MRI. We excluded review articles and expert opinion and postmortem studies.

Quality standards

We excluded studies that were methodologically weak due to significant bias, confounding factors, case attrition or incomplete ascertainment. It was essential that the included studies had a high surety of child abuse. To guarantee this, we used our previously published definitions of abuse and only included studies in categories 1–3 (table 1). We chose this approach whereby a definition of abuse was based upon the outcome of a legal or multi-agency child protection investigation or stated criteria where diagnosis was based upon additional features and did not rely on the neuroradiological findings, to minimise the risk of circularity in a condition where there is no ‘gold standard’ diagnostic test. nAHT was defined as a witnessed traumatic event, where the cause of injury was stated or where child abuse had been actively excluded.

The criteria were applied by two independent reviewers with experience in child protection, paediatric neuroradiology, neurology and ophthalmology. All were trained in critical

appraisal and met on a monthly basis to discuss the review process and to ensure consistency of approach. A third review was conducted for discrepancies. Data extraction standards were derived from guidance from the NHS Centre for Reviews and Dissemination.⁹ We wrote to authors to elucidate certain points. We were privileged to have access to original datasets that provided clarification of data.^{10–12}

Statistics

We conducted a meta-analysis of studies that ascertained a defined population where there was consecutive case enrolment over a defined time period of all children with AHT and nAHT and present a descriptive analysis when this was not possible. We grouped studies according to the primary items of interest: subdural haemorrhage (SDH), subarachnoid haemorrhage (SAH), extradural haemorrhage (EDH), hypoxic-ischaemic injury (HII), parenchymal injury, cerebral oedema and closed head injury; secondary items included the number, location, distribution and attenuation/signal characteristics (on CT) of extra-axial haemorrhages.

We used OR as a measure of effect with 95% CIs. We pooled data using a random effects model to allow for both intra and inter study variances and to give a more conservative estimate of the effect. The level of heterogeneity was expressed using both the Q test (Cochrane’s χ^2) with a cut off of $p < 0.1$ and the I^2 index

Table 1 Definitions of child abuse

Categories	Criteria used to define abuse
1	Abuse confirmed at case conference, family, civil or criminal court proceedings or admitted by perpetrator or witnessed
2	Abuse confirmed by stated criteria including multidisciplinary assessment
3	Abuse defined by stated criteria
4	Abuse stated but no supporting detail given
5	Suspected abuse

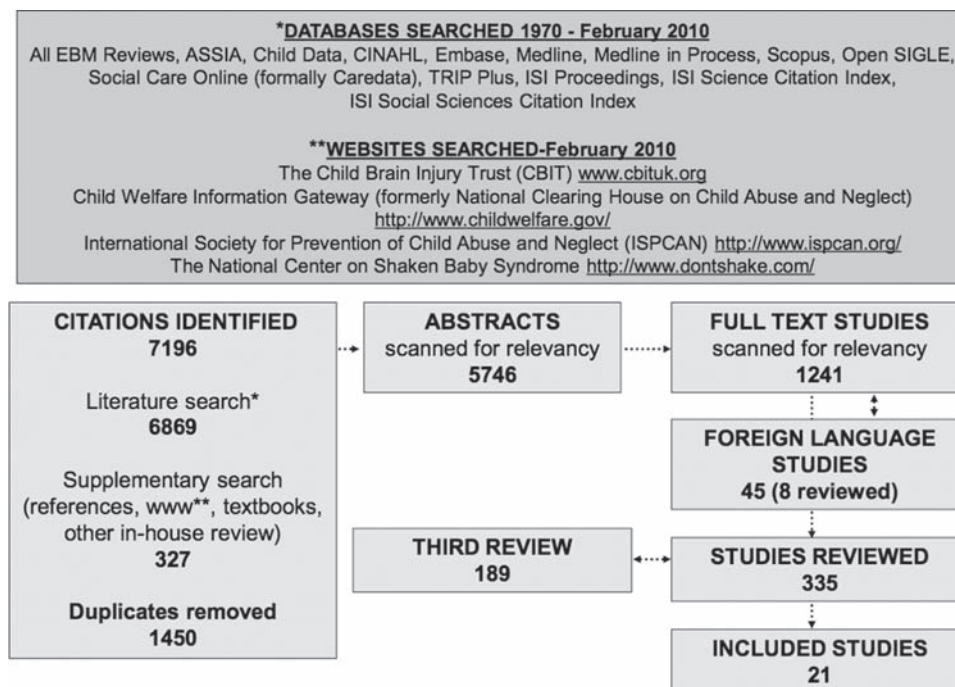


Figure 1 Systematic review search strategy and review process.

which describes the percentage of total variation across studies that is not due to chance but rather a result of heterogeneity, where I^2 of 25%, 50% and 75% represented low, moderate and high levels of heterogeneity, respectively.¹³ MIX: meta-analysis made easy version 1.7 for Windows software was used to present data in forest plots (ordered according to the weight of each study) for each outcome, showing the calculated OR with 95% CI.

RESULTS

Twenty-one studies met the inclusion criteria (table 2), representing data from initial neuroimaging of 2353 children. There

were 893 cases of AHT and 1460 of nAHT. Ninety-six per cent of children with nAHT had non intentional head trauma, while a small number of children had sustained their pathology from organic causes (18) or birth injury (44).

Authors used different terminology to describe their study type. However, after reviewing study methodology we identified 18 comparative studies with consecutive case enrolment of children from a defined population who were hospitalised over a defined time period^{3 4 10–12 14–26} and one case control study.²⁷ These studies were eligible for meta-analyses. Two comparative case series^{28 29} had selective case enrolment and were not suitable for meta-analysis, however they provided useful data that were

Table 2 Summary of included studies

Author	Study type*	Category of abuse	Category of head trauma	AHT: no. children	nAHT: no. children	Age group (years)	Imaging
Adamo <i>et al</i> ²⁶	Cross-sectional	2	HI	54	164 (suspected abuse actively excluded)	0–3	All had CT
Bechtel <i>et al</i> ¹⁰	Cross-sectional	1+2	HI	15	67 (2 MVC, 65 falls (73% ≤4 ft))	0–2	All had CT
Datta <i>et al</i> ¹⁴	Cross-sectional	1	SDH	49	14 (3 trauma, 11 medical causes)	0–2	All had CT and/or MRI
Duhaime <i>et al</i> ³	Cross-sectional	1	HI	24	76 (7 MVC, 69 other trauma); social worker review of all cases	0–2	CT and/or MRI as clinically indicated
Ettaro <i>et al</i> ¹¹	Comparative case series (consecutive enrolment of all children)	3	HI	89	288 (50 MVC, 238 other trauma) (excluded concussion/contusion/cerebral laceration)	0–3	All had CT and/or MRI
Ewing-Cobbs <i>et al</i> ¹⁵	Prospective longitudinal study (consecutive case enrolment)	1	TBI	31	29 (18 MVC, 11 other trauma)	0–6	All had CT and/or MRI
Feldman <i>et al</i> ¹⁶	Prospective comparative case series (consecutive case enrolment)	2	SDH	39 (12 indeterminate cause)	15 (9 MVC, 3 falls >10 ft, 3 other trauma)	0–3	All had CT
Goldstein <i>et al</i> ¹⁷	Cross-sectional	1	TBI	14	26 (16 MVC, 10 other trauma)	0–16	All had CT and/or MRI
Hettler <i>et al</i> ¹⁸	Cross-sectional	1+3	TBI	49	114 (8 MVC, 58 falls >3 ft, 37 falls <3 ft, 11 other)	0–3	All had CT
Hymel <i>et al</i> ²⁷	Case-control	1	TBI	39	39 accidental head injury stated with active exclusion of abuse in cases of TBI	0–4	All had CT
Ichord <i>et al</i> ¹⁹	Consecutive cohort study	3	TBI	30	22 (4 MVC, 18 falls) (excluded coagulopathy, penetrating injury, burns, arrest and CPR)	0–3	All had MRI
Keenan <i>et al</i> ²⁰	Cross-sectional	1	TBI	80	72 (43 MVC, 17 falls, 12 other trauma)	0–2	All had CT and/or MRI
Kelly <i>et al</i> ²¹	Cross-sectional	1+3	SDH	41	23 (8 MVC, 14 falls (12 >1 m), 1 other) (excluded post-operative conditions, haematological disease)	0–2	All had CT and/or MRI
McKinney <i>et al</i> ²²	Cross-sectional	1	HI	11	38 (abuse actively excluded)	0–3	All had CT and/or MRI
Reece <i>et al</i> ⁴	Cross-sectional	1, 2, 3	HI	51	144 (MVC, witnessed injuries)	0–3	CT and/or MRI as clinically indicated
Shugerman <i>et al</i> ²³ (SDH and EDH cases)	Cross-sectional	1	SDH	28 SDH 2 EDH	25 SDH, 32 EDH defined on discharge diagnosis, uncertain cases excluded	0–3	All had CT
Tung <i>et al</i> ²⁸	Retrospective comparative case series	1	SDH	9	38 (2 MVC, 17 other trauma, 19 birth injury)	0–3	All had CT
Tzioumi <i>et al</i> ²⁴	Cross-sectional	1	SDH	21	17 (5 MVC, 5 significant falls, 5 other trauma, 2 medical cause)	0–2	All had CT
Vinchon <i>et al</i> ¹²	Cross-sectional	2	HI	57	93 (12 MVC, 55 trauma, 21 birth injury, 5 medical cause)	0–2	All had CT and/or MRI
Vinchon <i>et al</i> ²⁹	Prospective comparative case series	2	HI	12	8 (4 trauma, 4 birth related)	<1	All had CT and MRI
Wells <i>et al</i> ²⁵	Retrospective consecutive case series (equivalent to cross-sectional)	2	TBI	148 (36 intent uncertain)	109 witnessed trauma	0–3	All had CT

*Study type is given according to author definition when stated. Where enrolment was consecutive and included all children from a defined population, this is stated and deemed equivalent to a cross-sectional study design.

AHT, abusive head trauma; CPR, cardiopulmonary resuscitation; EDH, extradural haemorrhage; HI, head injury; MVC, motor vehicle crash; nAHT, non-abusive head trauma; SDH, subdural haemorrhage; TBI, traumatic brain injury.

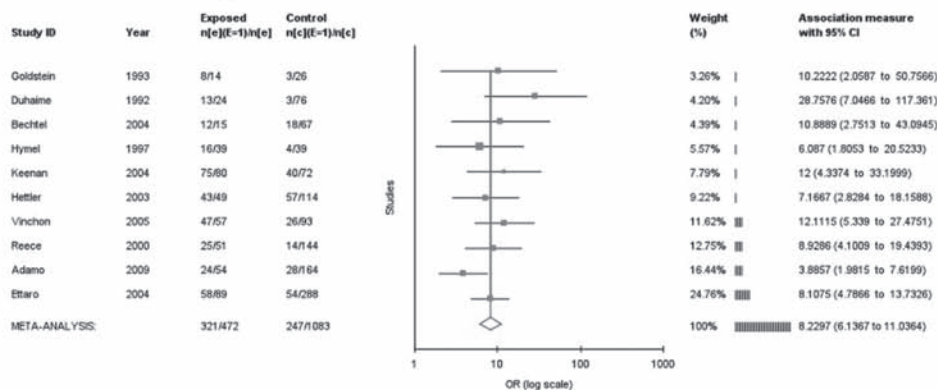
subject to a descriptive analysis. Eight studies ascertained all children with head injuries (HI),^{3 4 10–12 22 26 29} seven included children with traumatic brain injuries (TBI)^{15 17–20 25 27} and six included those with SDH,^{14 16 21 23 24 28} one of which also included children with EDH.²³ Eighteen studies addressed a similar age range and provided an analysis of children less than 3 years old.^{3 4 10–12 14 16 18–26 28 29} One study¹⁷ included children up to 16 years of age, however exclusion of this study from the meta-analyses made no significant differences to the overall results. Details from cases ranked 1–3 for a security of diagnosis for abuse were included in the meta-analyses. Two studies^{16 25} included details of 12 and 36 cases where abuse was suspected but not confirmed; when these cases were added into the abuse group, thus broadening the category of abuse, there was no difference to the overall results.

Eleven studies stated that neuroimaging included an initial CT scan and/or MRI,^{3 4 11 12 14 15 17 20–22 29} nine CT alone^{10 16 18 23–28} and one MRI alone.¹⁹ All children included in the study received neuroimaging; in two studies the authors stated that investigations were performed according to clinical indications.^{3 4} Eight studies incorporated an independent radiological review^{14 15 19 20 22 25 27 28} or selective review of discrepant radiology reports,²³ while the remainder appeared to utilise the initial radiology report.

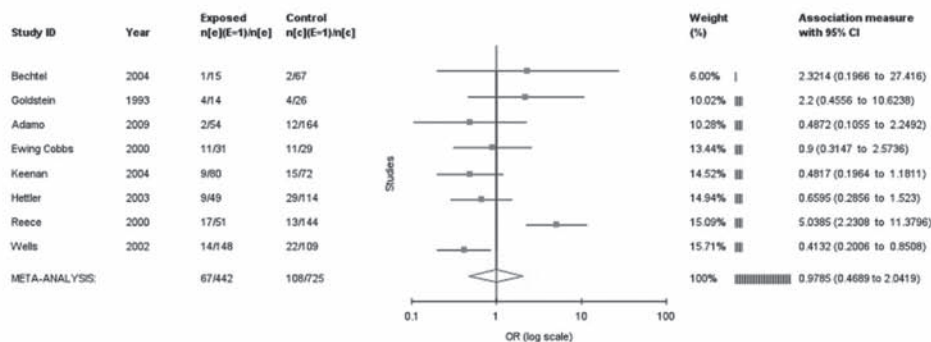
Extra-axial haemorrhages

It was possible to calculate the OR for SDH, SAH and EDH in AHT for studies where the inclusion criteria were children with TBI or HI (figure 2).

Subdural haemorrhage



Subarachnoid haemorrhage



Extradural haemorrhage

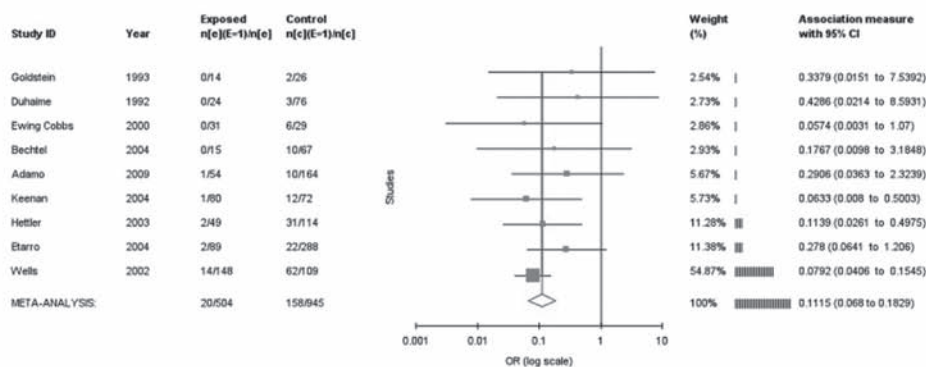


Figure 2 Meta-analysis of extra-axial haemorrhage as an indicator of abusive head trauma.

Subdural haemorrhage

The clear association of SDH with AHT was confirmed by an OR of 8.2 (95% CI 6.1 to 11; $p < 0.0001$), with studies having a low level of heterogeneity ($Q=9.7$ ($df=9$), $p=0.36$, $I^2=8\%$) (figure 2). The highest OR was derived from the Duhaime study.³ However, when this study was excluded from the calculation, the OR was not significantly altered.

Subarachnoid haemorrhage

SAH was described in eight studies of children with HI or TBI (figure 2). The OR for AHT was 0.98 (95% CI 0.47 to

2.0; $p=0.95$). The heterogeneity was high ($Q=26$ ($df=7$), $p < 0.001$, $I^2=73.4\%$). Reece *et al* was the only study to identify a significant association between SAH and AHT.⁴ When this study was excluded from the calculation, the heterogeneity fell ($Q=5.7$ ($df=6$), $p=0.46$, $I^2=0\%$), but there was still no significant association with nAHT (OR for AHT 0.6, 95% CI 0.4 to 0.9).

Extradural haemorrhage

Nine studies confirmed a significant association between EDH and nAHT (figure 2). The overall OR for EDH and

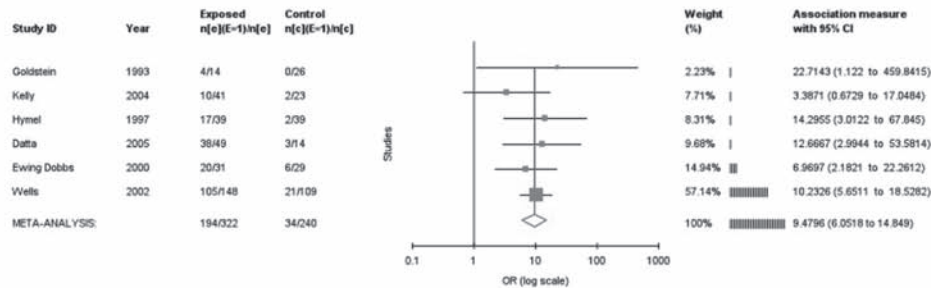

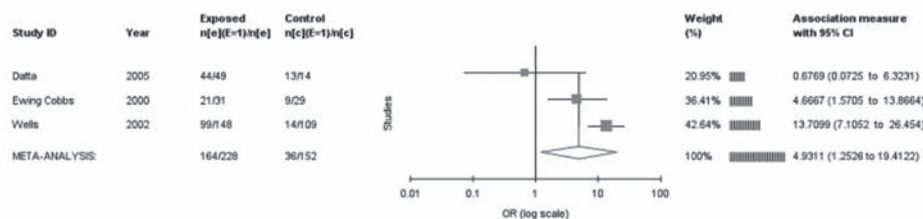
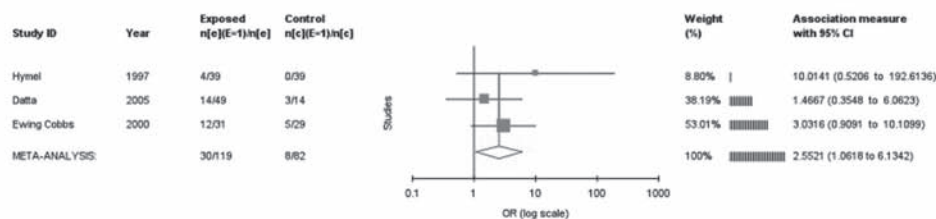
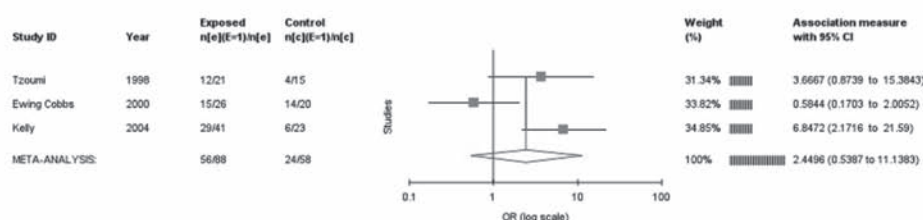
Interhemispheric haemorrhage**Multiple haemorrhages****Convexity haemorrhage****Infratentorial/posterior fossa haemorrhage****Bilateral SDH**

Figure 3 Meta-analysis of the characteristics of extra-axial haemorrhage as an indicator of abusive head trauma. SDH, subdural haemorrhage.

AHT was 0.1 (95% CI 0.07 to 0.18; $p < 0.0001$) ($Q = 5.2$ ($df = 8$), $p = 0.7$, $I^2 = 0\%$).

Distribution, appearance and numbers of extra-axial haemorrhages

Studies selected different characteristics of extra-axial haemorrhages for comparison (figure 3). Meta-analyses of studies that described the number and distribution of extra-axial haemorrhages showed that interhemispheric haemorrhages were significantly associated with AHT, with an OR of 9.5 (95% CI 6.1 to 14.9; $p < 0.001$) and heterogeneity between studies was low ($Q = 2.6$ ($df = 5$), $p = 0.7$, $I^2 = 0\%$). There were only two studies that counted children with multiple extra-axial haemorrhages, both demonstrating a strong association with AHT and an overall OR of 6 (95% CI 2.5 to 14.4; $p < 0.001$) ($Q = 0.06$ ($df = 1$), $p = 0.8$, $I^2 = 0\%$). SDH over the convexities had an OR of 4.9 (95% CI 1.3 to 19.4; $p = 0.02$), but the heterogeneity of this latter group of studies was high ($Q = 8.1$ ($df = 2$), $p = 0.017$, $I^2 = 75.3\%$).

Infra-tentorial/posterior fossa haemorrhages were associated with AHT with an overall OR for AHT of 2.5 (95% CI 1 to 6;

$p = 0.04$) ($Q = 1.5$ ($df = 2$), $p = 0.47$, $I^2 = 0\%$). In three studies it was possible to calculate the OR for bilateral SDH (OR 2.8, 95% CI 0.8 to 9.6; $p = 0.09$), which did not reach significance. The heterogeneity between studies was also high ($Q = 6.3$ ($df = 2$), $p = 0.04$, $I^2 = 68\%$).

Attenuation of extra-axial haemorrhages on CT imaging

The terminology used to describe the attenuation of extra-axial haemorrhages on CT varied considerably between studies and data were presented in different formats which precluded meta-analysis. Older studies inferred the age of the lesion from the appearance of SDH; for example, high attenuation collections were described as acute haemorrhages and low attenuation lesions as chronic SDH. Later studies described the SDH or collections in terms of their radiological appearance (table 3).

Table 3 shows that, overall, multiple SDH of different attenuations were reported on initial CT, predominantly in AHT.^{14 16 21 25 26} Studies emphasised the finding that low attenuation haemorrhages were more commonly seen in

Table 3 Attenuation of subdural haemorrhages on neuroimaging in children with AHT and in those with nAHT

Author Neuroimaging	Children with AHT Data as described in each study	nAHT Data as described in each study	Interpretation
Adamo <i>et al</i> ²⁶ Initial CT	24/54 children with HI had SDH due to AHT 58% of subdural collections were hypodense	28/164 children with HI had SDH 14% of subdural collections were hypodense	Patients who presented with hypodense and hyperdense SDH were more likely to have AHT (OR 6.39, 95% CI 3.4 to 11.9) Specifically, patients with hypodense SDH were more likely to have AHT (OR 20.6, 95% CI 6.7 to 63)
Datta <i>et al</i> ¹⁴ Initial CT 63/64 (1 MRI) (follow-up MRI (1–12 days) in 25)	32/49 children with SDH due to AHT had multiple SDH In 26/32 the SDH were of different attenuation (6 cases only seen on MRI)	3/14 children with SDH had multiple SDH which were the same hyperdense attenuation (2 motor vehicle crashes and 1 coagulation disorder)	Children with SDH from AHT were more likely to have multiple SDH of different attenuation
Ewing-Cobbs <i>et al</i> ¹⁵ Initial CT 59/60 (day 1) Follow-up MRI 24/31 AHT and 14/29 NAHT (mean 2.6 days post admission)	26/31 children had 52 SDH 43 acute 6 subacute 3 chronic 4/31 children with AHT had subdural hygromas	20/29 children had 20 SDH 14 acute 6 subacute No subdural hygromas recorded	Low attenuation SDH were only reported in AHT
Feldman <i>et al</i> ¹⁶ Initial CT	22/39 children with SDH were acute 5/39 children had acute and chronic SDH 12/39 had chronic SDH	15/15 children had acute SDH	Multiple SDH of different attenuations and those of low attenuation were only seen in AHT, while nAHT SDH were all of high attenuation
Hymel <i>et al</i> ²⁷ Initial CT	8/39 children with AHT had low attenuation large (non-acute) extra-axial fluid	0/39 children with accidental closed head injury had (non-acute) extra-axial fluid	Low attenuation extra-axial fluid was seen exclusively in AHT (Fisher's exact test $p = 0.005$)
Kelly <i>et al</i> ²¹ Initial CT	22/41 children with SDH had SDH which were either non-acute or (when multiple) of greater than one age	None of 23 nAHT had SDH of different ages	SDH of different attenuations or of low attenuation were only seen in AHT
Wells <i>et al</i> ²⁵ Initial CT images	35/148 children had acute intracranial haemorrhage in association with low attenuation subdural hygroma	Low attenuation subdural hygromas were not recorded in any of 109 nAHT cases	SDH of different attenuations more likely to be seen in AHT
Tung <i>et al</i> ²⁸ Non-contrast CT: on day 1 for 11 NAHT and at presentation for AHT	Homogeneous (uniform attenuation) hyper-attenuating SDH in 3/9 (33%) children Heterogeneous (different attenuations in the same haematoma) SDH in 6/9 (67%) cases	Homogeneous hyperdense SDH on 28/38 (74%) scans ($p = 0.045$) Heterogeneous SDH in 7/38 (18%) cases of nAHT ($p = 0.008$)	nAHT SDH were predominantly high attenuation SDH SDH of mixed attenuation reported in both AHT and nAHT but more significantly associated with AHT
Vinchon <i>et al</i> ²⁹ Initial CT	Mixed attenuation collections in 11/12	Mixed attenuation collections in 5/8 nAHT cases	SDH of mixed attenuation reported in AHT and nAHT

AHT, abusive head trauma; HI, head injury; nAHT, non-abusive head trauma; SDH, subdural haemorrhage.

AHT than in nAHT.^{15 16 21 25–27} Two studies^{28 29} reported SDH of mixed attenuation (different attenuation in the same SDH): Tung *et al* stated they were seen significantly more often in AHT than in nAHT, while Vinchon noted that they were equally prevalent in both conditions.

Intra-cerebral lesions

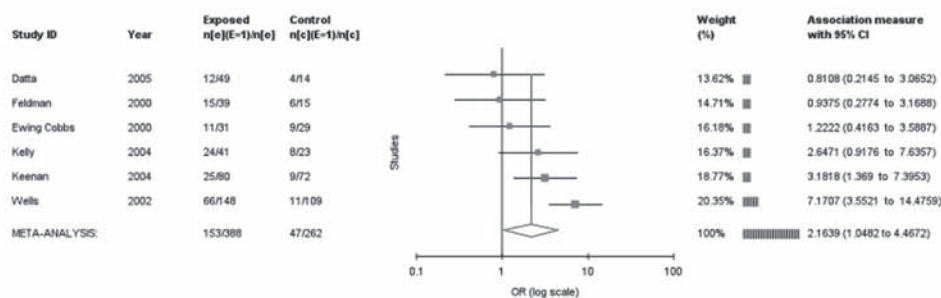
Cerebral oedema was significantly associated with AHT (OR 2.16, 95% CI 1.04 to 4.46; $p=0.04$); the heterogeneity was moderate ($Q=15.8$ ($df=5$), $p=0.008$, $I^2=68\%$). The studies failed to describe the extent or distribution of the oedema (figure 4).

Studies recorded different components of focal parenchymal injury, namely haemorrhage or contusion, or simply referred to parenchymal injury. The overall OR suggests that focal parenchymal injury is not a discriminatory feature for AHT (OR 0.96, 95% CI 0.6 to 1.6; $p=0.86$) ($Q=20$ ($df=11$), $p=0.04$, $I^2=46\%$).

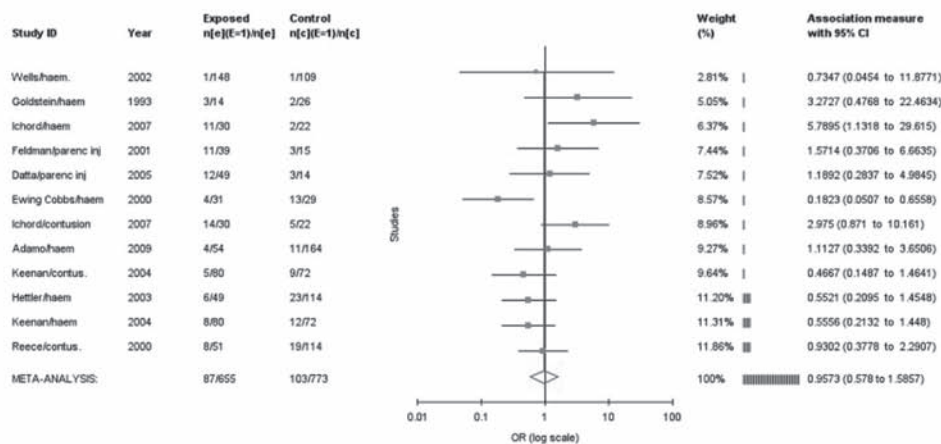
Three studies reported shear injury: Hymel *et al*²⁷ and Ichord *et al*¹⁹ both noted one case in the AHT and nAHT groups, respectively, while Ewing-Cobbs *et al*¹⁵ commented on an unexpected exclusive association with nAHT (9/29 versus 0/31; $p=0.001$). Only one study¹⁴ commented on diffuse axonal injury that was reported in 1/49 cases with AHT.

Three studies addressed HII in children with head trauma.^{19 20 22} The study of Ichord *et al* was the only one based purely upon MRI findings and stated that the HII changes were predominantly bilateral and generalised in 9/22 cases of AHT in comparison to 1/30 cases of nAHT. Children with HII had a significantly greater association with seizures ($p=0.01$, Fisher's exact test), a lower Glasgow Coma Score on admission ($p=0.002$, Mann-Whitney), a higher requirement for ventilation on admission and a higher requirement for subsequent rehabilitation ($p<0.001$, Fisher's exact test). The overall OR for HII in association with AHT was 3.7 (95% CI 1.4 to 10;

Cerebral oedema



Focal parenchymal injury



Hypoxic ischaemic injury

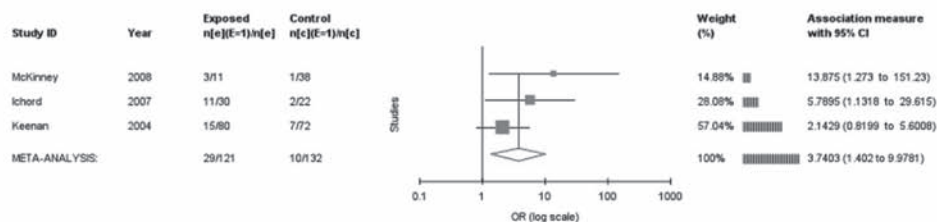


Figure 4 Meta-analysis of intracranial features as an indicator of abusive head trauma.

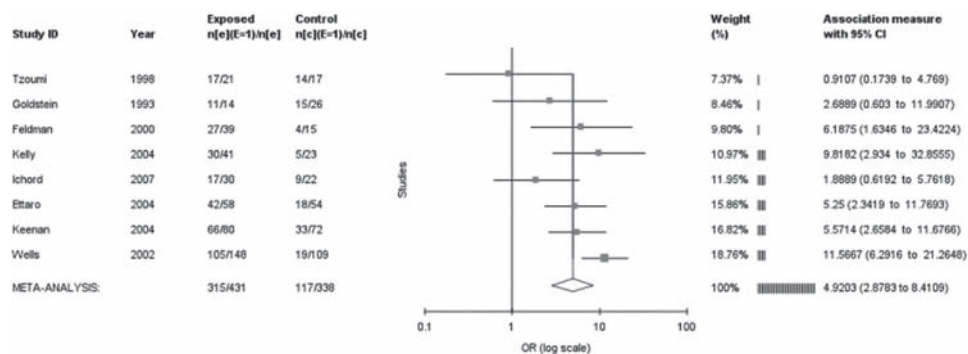


Figure 5 Meta-analysis of closed head injury as an indicator for abusive head trauma.

$p=0.01$); heterogeneity between the three studies was low ($Q=2.6$ ($df=2$), $p=0.27$, $I^2=23.7\%$).

Closed head injury

In eight studies where the comparison group were predominantly traumatic cases of head injury and the authors had documented coexisting skull fractures, it was possible to calculate an OR for closed head injury (intracranial injury without skull fracture confirmed on skull x-ray or CT) (figure 5). The OR for closed head injury in AHT was 4.6 (95% CI 2.9 to 7.5; $p<0.001$), with moderate heterogeneity ($Q=18$ ($df=8$), $p=0.02$, $I^2=55\%$).

Multiple associated findings

All studies confirmed that children in either group could present with multiple features on neuroimaging; however, only three studies attempted to determine whether different combinations of features were associated with AHT. Wells *et al*²⁵ undertook a multiple logistic regression analysis and identified four significant variables: (1) convexity SDH; (2) interhemispheric SDH; (3) low attenuation subdural fluid; and (4) absent skull fracture. The authors evaluated combinations of these features on initial CT imaging and their predictive powers for AHT. Using a 0.45 cut-off point in their logistic model, the prediction for AHT had a sensitivity of 84% (95% CI 78% to 90%) and specificity of 83% (95% CI 74% to 89%). Ewing-Cobbs *et al*¹⁵ showed that combinations of SAH and/or SDH with interhemispheric haemorrhage had a strong association with AHT (OR 11, 95% CI 3 to 41; $p<0.001$).

Ichord *et al*¹⁹ compared the MRI profile of traumatic injuries (extra-axial haemorrhages, cortical contusion, parenchymal injury, white matter haemorrhage and shearing injury) and HII. They showed that bilateral HII in association with, but not co-localising with, traumatic injuries was more common in AHT (9/22) than in nAHT (1/31) ($p<0.001$) in comparison with three other combinations, namely: (1) mixed traumatic and ischaemic lesions anatomically contiguous or co-localising, (2) traumatic lesions without associated ischaemic lesions and (3) indeterminate focal lesions, which did not appear to be discriminatory.

DISCUSSION

We have described the weight of evidence behind the neuroradiology of AHT and confirmed that there are a number of features that are significantly associated with the diagnosis. At a time when debate continues about clinicians' ability to distinguish AHT from nAHT, statistical confirmation of these associations may lead to less disagreement in the clinical, forensic

and legal setting. Features significantly associated with AHT included SDH, that were frequently multiple, located within the interhemispheric fissure, over the convexity and in the posterior fossa. AHT was more likely in the context of a closed head injury, while SAH were found to be non-discriminatory and EDH were significantly associated with nAHT.

Included studies showed that HII was significantly associated with AHT, as was cerebral oedema, whereas focal parenchymal injury was not a discriminatory feature. Shearing injury and diffuse axonal injury were rarely reported, precluding analysis. With the exception of the study of Ichord *et al*,¹⁹ this analysis is based predominantly upon CT imaging, which remains the recommended first line investigation for suspected AHT. The evidence base will inevitably increase in the future once more large scale studies of MRI findings are published. Early MRI is increasingly recommended alongside CT as it enables more sensitive detection and characterisation of intracerebral disruptive lesions, oedema and HII and can identify extra-axial haemorrhages in locations obscure to CT imaging³⁰ and the anatomical compartment(s) in which the extra-axial haemorrhage lie(s).

This systematic review has the merit of analysing several similar studies that drew upon populations of children less than 3 years of age. The limitations include variation in the composition of nAHT groups, inclusion criteria and imaging techniques used, together with small study numbers and data sets that support some of the meta-analyses. However, the heterogeneity of the meta-analyses was generally low to moderate. The forest plots summarise the current comparative studies in this field and reflect consistency in their findings.

Children with head trauma from either cause may present with different combinations of neuroradiological features. While the data could not be combined into a comprehensive multivariate analysis, three studies^{15 19 25} suggested that certain combinations of the indicative features have the potential to predict AHT.

The more recent studies that included diffusion weighted MRI findings^{19 22} provide confirmation of the association between HII and AHT.^{31–34} Although this association is increasingly recognised, the proposed mechanism of HII remains poorly understood. Multiple factors are proposed, such as respiratory insufficiency in an infant who is subjected to delayed medical attention, repeated traumatic events or damage to the respiratory control centres in the brainstem.^{19 31} Ichord *et al* confirmed the association of ventilatory support in children with HII and AHT, which the authors proposed may support some of these theories. They also confirmed the greater association

of seizures in children with AHT and suggested that the seizures may be related to the HII and exacerbate further damage to the brain itself through excitotoxic mechanisms or by inducing further respiratory insufficiency.¹⁹

A descriptive analysis of the attenuation of SDH on CT imaging supports an association of multiple SDH of different attenuation, and low attenuation SDH, with AHT. In the past these findings have been interpreted as indicative of repetitive or previous episodes of inflicted head injury.^{14,27} However, thinking behind this interpretation is changing. Vinchon *et al*²⁹ listed several factors that affect the neuroimaging appearance of SDH, all of which may change over different time scales. These include the degradation of haemoglobin, the state of hydration of the red blood cells, the integrity of cell membranes, the protein content of the blood clot, the rate of sedimentation and concentration of red blood cells and the amount of cerebrospinal (CSF) fluid within the collection. Such factors can all potentially affect the appearance of acute subdural collections on scans and there is no reason to believe that all extra-axial haematomas evolve or resolve at the same rate. Dias *et al*³⁵ urged caution when interpreting a hypodense collection as chronic: they describe a low attenuation subdural collection that was not present on a scan performed within 3 h of injury but appeared on a second scan 17 h later. Vinchon *et al*²⁹ highlight the lack of evidence in this field and suggest that further research is required to explore time-related changes in MRI signals in the sedimentary component of extra-axial haemorrhages utilising T1-weighted and FLAIR sequences.

SDH of mixed attenuation were reported in both AHT and nAHT, a finding that has previously been interpreted as re-bleeding into a chronic SDH, akin to that described in the elderly due to leakage from the vascularised pseudomembranes that develop in an organising SDH.^{36–38} However, there is no evidence that the resolution of SDH in infancy bears any similarity to that in the elderly adult. It is currently proposed that a “mixed-density SDH reflects the combination of high attenuation blood from acute haemorrhage or clot retraction and lower density fluid from unclotted blood, serum, or CSF”.²⁸ Case studies describe traumatic tears in the arachnoid membrane leading to ingress of CSF which may mix with the high attenuation blood within an acute SDH.^{39,40} Vinchon *et al* undertook a series of CT scans in infants who had motor vehicle crashes and showed how mixed attenuation SDH developed within 24 h of the traumatic event.⁴¹ Serial MR imaging is likely to be of benefit when interpreting these lesions over time.¹²

In a previous systematic review we confirmed the positive association with AHT of clinical features including retinal haemorrhages, apnoea, rib fractures and absence of skull fractures.⁴² To date, there have been no large studies that have carried out a multivariate analysis of combined clinical and neuroradiological findings to determine their specificity for AHT. Clinical and forensic assessment must include a history, detailing the biomechanical parameters of proposed explanations for injury, a thorough examination and investigations to describe associated clinical findings. Careful interpretation of the full clinical picture, together with the neuroradiological findings on CT and early MRI, should facilitate greater diagnostic confidence. Standardised reporting and data collection for all young children with head injury would enable large scale epidemiological studies to compare neuroradiological changes as they relate to clinical features for AHT and nAHT.

In conclusion, this systematic review confirms that there are neuro-radiological features that are significantly associated with

AHT. While these findings have clinical application and can be used to inform child protection, and family and Criminal Court decisions, further prospective comparative studies are indicated in the context of rapidly developing neuroimaging techniques.

Acknowledgements The authors are extremely grateful to Dr K Bechtel, Dr L Ettaro and Professor M Vinchon for kindly providing access to raw data from the relevant studies. This work is based on reviews conducted by the Welsh Child Protection Systematic Review Group: T Abdelnour, M Barber, R Brooks, L Cole, S Datta, J deWaterNaude, M Gawne-Cain, C Graham, J Griffiths, T Jaspan, N John, R Jones, K Kontos, A Liu, A Mott, A Naughton, M Northey, L Price, I Prosser, S Rajaram, A Rawlinson, J Saunders, M Schmidt, J Sibert, D Slade, N Stoodley and P Watts. The authors would also like to acknowledge the statistical advice provided by Dr Zoe Lawson and Dr Daniel Farewell, Department of General Practice and Epidemiology, Cardiff University.

Funding This study was funded by the National Society for the Prevention of Cruelty to Children (NSPCC), the Royal College of Paediatrics and Child Health (RCPCH) and the Wales Office of Research and Development.

Competing interests None.

Provenance and peer review Not commissioned; externally peer reviewed.

REFERENCES

1. Jayawant S, Rawlinson A, Gibbon F, *et al*. Subdural haemorrhages in infants: population based study. *BMJ* 1998;**317**:1558–61.
2. Dashti SR, Decker DD, Razzaq A, *et al*. Current patterns of inflicted head injury in children. *Pediatr Neurosurg* 1999;**31**:302–6.
3. Duhaime AC, Alario AJ, Lewander WJ, *et al*. Head injury in very young children: mechanisms, injury types, and ophthalmologic findings in 100 hospitalized patients younger than 2 years of age. *Pediatrics* 1992;**90**:179–85.
4. Reece RM, Sege R. Childhood head injuries: accidental or inflicted? *Arch Pediatr Adolesc Med* 2000;**154**:11–15.
5. National Collaborating Centre for Acute Care. Head Injury. Triage, Assessment, Investigation and Early Management of Head Injury in Infants, Children and Adults. London: National Collaborating Centre for Acute Care, 2003. <http://www.nice.org.uk/nicemedia/live/11836/36260/36260.pdf> (accessed 18 July 2011).
6. Child Protection Companion. http://www.rcpch.ac.uk/sites/default/files/asset_library/Health%20Services/ChildProtCompL.pdf (accessed 18 July 2011)
7. Kemp AM. Investigating subdural haemorrhage in infants. *Arch Dis Child* 2002;**86**:98–102.
8. Christian CW, Block R. Abusive head trauma in infants and children. *Pediatrics* 2009;**123**:1409–11.
9. NHS Centre for Reviews and Dissemination. *Undertaking Systematic Reviews of Research on Effectiveness. CRD's Guidance for Those Carrying out or Commissioning Reviews CRD report no. 4*. Second edition. York: University of York 2001.
10. Bechtel K, Stoessel K, Leventhal JM, *et al*. Characteristics that distinguish accidental from abusive injury in hospitalized young children with head trauma. *Pediatrics* 2004;**114**:165–8.
11. Ettaro L, Berger RP, Songer T. Abusive head trauma in young children: characteristics and medical charges in a hospitalized population. *Child Abuse Negl* 2004;**28**:1099–111.
12. Vinchon M, Defoort-Dhellemmes S, Desurmont M, *et al*. Accidental and nonaccidental head injuries in infants: a prospective study. *J Neurosurg* 2005;**102**:380–4.
13. Higgins JP, Thompson SG, Deeks JJ, *et al*. Measuring inconsistency in meta-analyses. *BMJ* 2003;**327**:557–60.
14. Datta S, Stoodley N, Jayawant S, *et al*. Neuroradiological aspects of subdural haemorrhages. *Arch Dis Child* 2005;**90**:947–51.
15. Ewing-Cobbs L, Prasad M, Kramer L, *et al*. Acute neuroradiologic findings in young children with inflicted or noninflicted traumatic brain injury. *Childs Nerv Syst* 2000;**16**:25–33; discussion 34.
16. Feldman KW, Bethel R, Shugerman RP, *et al*. The cause of infant and toddler subdural hemorrhage: a prospective study. *Pediatrics* 2001;**108**:636–46.
17. Goldstein B, Kelly MM, Bruton D, *et al*. Inflicted versus accidental head injury in critically injured children. *Crit Care Med* 1993;**21**:1328–32.
18. Hettler J, Greenes DS. Can the initial history predict whether a child with a head injury has been abused? *Pediatrics* 2003;**111**:602–7.
19. Ichord RN, Naim M, Pollock AN, *et al*. Hypoxic-ischemic injury complicates inflicted and accidental traumatic brain injury in young children: the role of diffusion-weighted imaging. *J Neurotrauma* 2007;**24**:106–18.
20. Keenan HT, Runyan DK, Marshall SW, *et al*. A population-based comparison of clinical and outcome characteristics of young children with serious inflicted and noninflicted traumatic brain injury. *Pediatrics* 2004;**114**:633–9.
21. Kelly P, Hayes I. Infantile subdural haematoma in Auckland, New Zealand: 1988–1998. *N Z Med J* 2004;**117**:U1047.

22. **McKinney AM**, Thompson LR, Truwit CL, *et al*. Unilateral hypoxic-ischemic injury in young children from abusive head trauma, lacking craniocervical vascular dissection or cord injury. *Pediatr Radiol* 2008;**38**:164–74.
23. **Shugerman RP**, Paez A, Grossman DC, *et al*. Epidural hemorrhage: is it abuse? *Pediatrics* 1996;**97**:664–8.
24. **Tzioumi D**, Oates RK. Subdural hematomas in children under 2 years. Accidental or inflicted? A 10-year experience. *Child Abuse Negl* 1998;**22**:1105–12.
25. **Wells RG**, Vetter C, Laud P. Intracranial hemorrhage in children younger than 3 years: prediction of intent. *Arch Pediatr Adolesc Med* 2002;**156**:252–7.
26. **Adamo MA**, Drazin D, Smith C, *et al*. Comparison of accidental and nonaccidental traumatic brain injuries in infants and toddlers: demographics, neurosurgical interventions, and outcomes. *J Neurosurg Pediatr* 2009;**4**:414–19.
27. **Hymel KP**, Rumack CM, Hay TC, *et al*. Comparison of intracranial computed tomographic (CT) findings in pediatric abusive and accidental head trauma. *Pediatr Radiol* 1997;**27**:743–7.
28. **Tung GA**, Kumar M, Richardson RC, *et al*. Comparison of accidental and nonaccidental traumatic head injury in children on noncontrast computed tomography. *Pediatrics* 2006;**118**:626–33.
29. **Vinchon M**, Noulé N, Tchofo PJ, *et al*. Imaging of head injuries in infants: temporal correlates and forensic implications for the diagnosis of child abuse. *J Neurosurg* 2004;**101**:44–52.
30. **Kemp AM**, Rajaram S, Mann M, *et al*. What neuroimaging should be performed in children in whom inflicted brain injury (iBI) is suspected? A systematic review. *Clin Radiol* 2009;**64**:473–83.
31. **Geddes JF**, Hackshaw AK, Vowles GH, *et al*. Neuropathology of inflicted head injury in children. I. Patterns of brain damage. *Brain* 2001;**124**:1290–8.
32. **Johnson DL**, Boal D, Baule R. Role of apnea in nonaccidental head injury. *Pediatr Neurosurg* 1995;**23**:305–10.
33. **Kemp AM**, Stoodley N, Cobley C, *et al*. Apnoea and brain swelling in non-accidental head injury. *Arch Dis Child* 2003;**88**:472–6; discussion 472–6.
34. **Shannon P**, Smith CR, Deck J, *et al*. Axonal injury and the neuropathology of shaken baby syndrome. *Acta Neuropathol* 1998;**95**:625–31.
35. **Dias MS**, Backstrom J, Falk M, *et al*. Serial radiography in the infant shaken impact syndrome. *Pediatr Neurosurg* 1998;**29**:77–85.
36. **Fobben ES**, Grossman RI, Atlas SW, *et al*. MR characteristics of subdural hematomas and hygromas at 1.5 T. *AJR Am J Roentgenol* 1989;**153**:589–95.
37. **Friede RL**, Schachenmayr W. The origin of subdural neomembranes. II. Fine structure of neomembranes. *Am J Pathol* 1978;**92**:69–84.
38. **Schachenmayr W**, Friede RL. The origin of subdural neomembranes. I. Fine structure of the dura-arachnoid interface in man. *Am J Pathol* 1978;**92**:53–68.
39. **Joy HM**, Anscombe AM, Gawne-Cain ML. Blood-stained, acute subdural hygroma mimicking a subacute subdural haematoma in non-accidental head injury. *Clin Radiol* 2007;**62**:703–6.
40. **Zouros A**, Bhargava R, Hoskinson M, *et al*. Further characterization of traumatic subdural collections of infancy. Report of five cases. *J Neurosurg* 2004;**100**:512–18.
41. **Vinchon M**, Noizet O, Defoort-Dhellemmes S, *et al*. Infantile subdural hematomas due to traffic accidents. *Pediatr Neurosurg* 2002;**37**:245–53.
42. **Maguire S**, Pickard N, Farewell D, *et al*. Which clinical features distinguish inflicted from non-inflicted brain injury? A systematic review. *Arch Dis Child* 2009;**94**:860–7.



Neuroimaging: what neuroradiological features distinguish abusive from non-abusive head trauma? A systematic review

A M Kemp, T Jaspan, J Griffiths, et al.

Arch Dis Child 2011 96: 1103-1112 originally published online September 30, 2011
doi: 10.1136/archdischild-2011-300630

Updated information and services can be found at:
<http://adc.bmj.com/content/96/12/1103.full.html>

These include:

References

This article cites 39 articles, 18 of which can be accessed free at:
<http://adc.bmj.com/content/96/12/1103.full.html#ref-list-1>

Email alerting service

Receive free email alerts when new articles cite this article. Sign up in the box at the top right corner of the online article.

Topic Collections

Articles on similar topics can be found in the following collections

[Child abuse](#) (149 articles)
[Injury](#) (173 articles)
[Neurological injury](#) (66 articles)
[Trauma](#) (171 articles)

Notes

To request permissions go to:
<http://group.bmj.com/group/rights-licensing/permissions>

To order reprints go to:
<http://journals.bmj.com/cgi/reprintform>

To subscribe to BMJ go to:
<http://group.bmj.com/subscribe/>