

# PEDIATRICS®

OFFICIAL JOURNAL OF THE AMERICAN ACADEMY OF PEDIATRICS

## **Retinal Hemorrhage in Abusive Head Trauma**

Alex V. Levin

*Pediatrics* 2010;126;961; originally published online October 4, 2010;

DOI: 10.1542/peds.2010-1220

The online version of this article, along with updated information and services, is located on the World Wide Web at:

<http://pediatrics.aappublications.org/content/126/5/961.full.html>

PEDIATRICS is the official journal of the American Academy of Pediatrics. A monthly publication, it has been published continuously since 1948. PEDIATRICS is owned, published, and trademarked by the American Academy of Pediatrics, 141 Northwest Point Boulevard, Elk Grove Village, Illinois, 60007. Copyright © 2010 by the American Academy of Pediatrics. All rights reserved. Print ISSN: 0031-4005. Online ISSN: 1098-4275.

American Academy of Pediatrics

DEDICATED TO THE HEALTH OF ALL CHILDREN™



# Retinal Hemorrhage in Abusive Head Trauma

**AUTHOR:** Alex V. Levin, MD, MHSC

*Pediatric Ophthalmology and Ocular Genetics, Wills Eye Institute, and Departments of Ophthalmology and Pediatrics, Jefferson Medical College of Thomas Jefferson University, Philadelphia, Pennsylvania*

**KEY WORDS**

abuse, ophthalmology/optometry, retinal hemorrhage

**ABBREVIATIONS**

RH—retinal hemorrhage

AHT—abusive head trauma

ILM—internal limiting membrane

ICP—intracranial pressure

CRV—central retinal vein

CRVO—central retinal vein obstruction

[www.pediatrics.org/cgi/doi/10.1542/peds.2010-1220](http://www.pediatrics.org/cgi/doi/10.1542/peds.2010-1220)

doi:10.1542/peds.2010-1220

Accepted for publication Jul 21, 2010

Address correspondence to Alex V. Levin, MD, MHSC, Pediatric Ophthalmology and Ocular Genetics, Wills Eye Institute, Suite 1210, 840 Walnut St, Philadelphia, PA 19107.

E-mail: [alevin@willseye.org](mailto:alevin@willseye.org)

PEDIATRICS (ISSN Numbers: Print, 0031-4005; Online, 1098-4275).

Copyright © 2010 by the American Academy of Pediatrics

**FINANCIAL DISCLOSURE:** *The author has indicated he has no financial relationships relevant to this article to disclose.*

## abstract

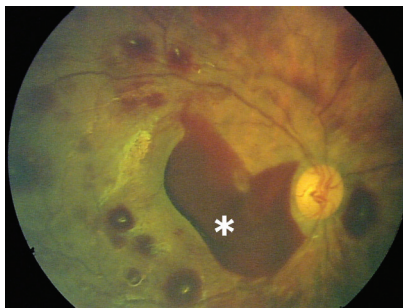
Retinal hemorrhage is a cardinal manifestation of abusive head trauma. Over the 30 years since the recognition of this association, multiple streams of research, including clinical, postmortem, animal, mechanical, and finite element studies, have created a robust understanding of the clinical features, diagnostic importance, differential diagnosis, and pathophysiology of this finding. The importance of describing the hemorrhages adequately is paramount in ensuring accurate and complete differential diagnosis. Challenges remain in developing models that adequately replicate the forces required to cause retinal hemorrhage in children. Although questions, such as the effect of increased intracranial pressure, hypoxia, and impact, are still raised (particularly in court), clinicians can confidently rely on a large and solid evidence base when assessing the implications of retinal hemorrhage in children with concern of possible child abuse. *Pediatrics* 2010;126:961–970

Aikman<sup>1</sup> was the first to associate retinal hemorrhage (RH) with child abuse in 1928. The association between RH and subarachnoid and subdural hemorrhage was noted long before child abuse was recognized by ophthalmologists.<sup>2,3</sup> In 1971, Guthkelch<sup>4</sup> was the first to describe RH in the setting of abusive “shaking.” The following year, in the first of 2 landmark articles, Caffey<sup>5,6</sup> began discussion about what would later be known as shaken-baby syndrome, a form of abusive head trauma (AHT) characterized by the application of repeated acceleration-deceleration forces with or without evidence of blunt head impact.<sup>7</sup> Numerous research publications have since created an enormous evidence base that informs us regarding RH as a marker for AHT, differential diagnosis, and diagnostic limitations.

## ANATOMY

Describing RH adequately is critical for appropriate differential diagnosis, which requires a three-dimensional view of the entire retina with the indirect ophthalmoscope used by ophthalmologists, preferably through dilated pupils (fixed and dilated pupils of a neurologically injured child or pharmacologically). Non-ophthalmologists are fairly accurate in describing presence or absence of RH, but false-negative and false-positive findings uncommonly may occur.<sup>8,9</sup> If there is a need to preserve pupillary reactivity for neurologic monitoring, options for allowing prompt dilated examination include short-acting mydriatics (eg, phenylephrine 2.5%), dilating each eye on consecutive days, or ophthalmic consultation through miotic pupils (least preferable).

The retina is multilayered. It extends from the optic nerve to the peripheral retinal edge (ora serrata) located just behind the iris root. The inner-most layer is the internal limiting membrane (ILM). Blood that is in front of the ILM is termed



**FIGURE 1**

Numerous RHs, mostly intraretinal, throughout the posterior pole. \* indicates preretinal (subhyaloid) blood. No retinal folds or retinoschisis can be seen, although the schisis cavity may be hidden by blood. This is a view of the posterior pole.

preretinal or subhyaloid: in front of the retina but behind the well-formed vitreous gel (hyaloid) that fills the globe behind the lens (Fig 1). Blood that is within the layers of the retina is intraretinal and further categorized as superficial (nerve-fiber layer) and deeper intraretinal hemorrhage (Fig 1). Superficial blood streams between nerve fibers leading to the synonyms “flame” or “splinter” hemorrhage. Deeper intraretinal hemorrhage is termed “dot” or, if larger, “blot” hemorrhage. There are no strict guidelines to define size cut offs for these 2 terms. Blood lying under the retina is subretinal.

One can also describe the number and distribution of RH. Blood that is immediately around the optic nerve head is peripapillary. Temporal to the optic nerve is a thinner specialized area of the retina, the fovea, for maximal vision. The fovea is the center of the macula, which contains a higher density of cone cells. RH that is in the macula and/or peripapillary retina is said to be in the posterior pole. Blood extending out from the posterior pole is mid-peripheral and, if more anteriorly and closer to the ora, peripheral.

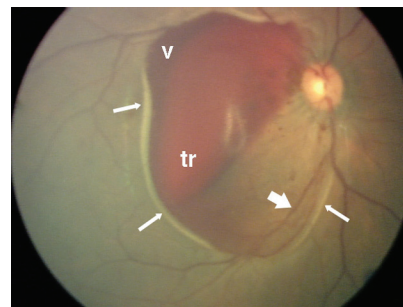
## RH IN SHAKEN-BABY SYNDROME

The incidence of RH in shaken-baby syndrome (SBS) is ~85%<sup>9,10</sup> but higher in children who have died versus unim-

paired survivors.<sup>11</sup> There is an association between severity of brain injury and RH severity. Rarely, RH can occur without intracranial hemorrhage or cerebral edema.<sup>12,13</sup> Approximately two-thirds of victims have RHs that are too numerous to count and are multilayered. These RHs extend out to the retinal periphery, with no particular anatomic pattern, and cover the majority of the retinal surface.

Macular retinoschisis (splitting of the retinal layers), was first described by Greenwald et al.<sup>14</sup> Blood accumulates at the level of cleavage, most often between the ILM and nerve-fiber layer. Blood can extend through the ILM into the vitreous (Fig 2). Follow-up is essential, because vitreous hemorrhage may compromise vision if it does not resorb. Otherwise, RH and schisis do not usually affect visual outcome.

RH cannot be dated with precision. Massive numbers of superficial or small-dot hemorrhages can resolve sometimes within 24 hours. There is some evidence that mild increases of hemorrhage, or appearance of hemorrhage not previously present, can occur early during hospitalization in very ill children,<sup>15</sup> which underscores the need for prompt ophthalmology consultation, preferably within 24 hours.



**FIGURE 2**

Traumatic retinoschisis of the macula in AHT. Arrows indicate the retinal fold at the edge of schisis with underlying hypopigmentation; tr, blood within the schisis cavity; v, blood escaping from the schisis cavity into the vitreous. Note the blood vessel (thick, short arrow) traveling from the optic nerve up onto the surface of the elevated schisis cavity and then down.

Retinal photography is not required but may be a useful adjunct, if available, for documentation.

### **PATHOPHYSIOLOGY**

Challenges to investigating pathophysiology include our inability to prospectively study live human infants and difficulties in establishing biofidelic modeling systems. Hypotheses have suggested factors including single blunt head impact, increased intracranial pressure (ICP), increased intrathoracic pressure, and hypoxia. Debate, largely in the courtroom, has raised other possible causes such as short falls or cardiopulmonary resuscitation with chest compression, which are often in the presenting history, as alternate explanations for RH seen clinically. Research along multiple lines has allowed recognition of the vital importance of vitreoretinal traction and specific effects of the repetitive acceleration-deceleration forces that characterize this form of abuse as the primary etiologic factor. Recognition of this etiology allows high levels of specificity and sensitivity in associating an abusive etiology, particularly when the child is younger than 3 years, when there is no evidence of direct globe trauma, and when the hemorrhages are multilayered and widespread with or without retinoschisis.<sup>16–18</sup>

### **Clinical Studies of Affected Children**

Numerous publications have documented retinal findings in SBS. There is a predilection for hemorrhages to be found in the peripheral retina, perivascular areas, and posterior pole, all of which are areas of maximal vitreoretinal attachment in infants and young children.<sup>9,10,16</sup> Whether there is evidence of blunt head impact does not correlate with the presence of RH.<sup>10</sup> Even when RH is not used as a diagnostic factor in determining if an injury was a result of abuse, there is a distinct association between RH and SBS.<sup>16,19,20</sup> The incidence of

RH in SBS is dramatically higher than in all forms of accidental blunt head injury, even lethal motor vehicle accidents. Hemorrhages are much more severe in SBS than accidental single-impact injury, with which hemorrhages are usually few and confined to posterior pole.<sup>11,16,17,19,21,22</sup> Severe hemorrhagic retinopathy has been reported in lethal motor vehicle crashes, usually with elements of repeated acceleration-deceleration (eg, rollovers).<sup>23</sup> The incidence of RH in studies of AHT declines when victims of single-impact head trauma are included.<sup>16</sup>

Macular retinoschisis, a result of vitreous traction on the macula,<sup>24–26</sup> often with vitreous still attached at the apices of circumferential traumatic retinal pleats (perimacular folds) that surround the schisis, seems to be almost uniquely associated with SBS; it has only been reported otherwise in the setting of 2 single cases of fatal head crush injury,<sup>27,28</sup> fatal motor vehicle accidents,<sup>25</sup> and an 11-meter fall.<sup>29</sup> Even in these rare circumstances the lesions seemed somewhat different than those seen in SBS. The clinical scenarios readily distinguish themselves. A larger study of pediatric head crush injury did not reveal such lesions.<sup>30</sup> It may be that direct ocular shear during crush injury rarely replicates the vitreoretinal traction that characterizes SBS.<sup>31</sup>

Results of postmortem studies of SBS victims also support results of the clinical studies.<sup>18,32–34</sup> In 1 study, hemorrhage in orbital tissues was noted, which suggests that globe movement during repeated acceleration-deceleration causes disruption of orbital vessels and tissues.<sup>35</sup> These findings were significantly less common in a group of accidental injuries unless there was direct orbital trauma or accidental repeated acceleration-deceleration forces. Even in the those cases, RH was distinctly less promi-

nent than SBS. Intrasceral hemorrhage can occur at the optic nerve-globe junction, another fulcrum point prone to tissue damage during repeated movement of the globe during SBS.<sup>36,37</sup>

The powerful association of severe hemorrhagic retinopathy with the unique repetitive acceleration-deceleration forces of SBS, as opposed to single-impact events, together with the findings of RH in areas of maximal vitreoretinal traction, strongly support causation by vitreoretinal traction. A few articles have been used to argue otherwise. The results of 1 study of 26 Japanese children with intracranial and retinal hemorrhage, seizures, and ruptured bridging veins after a fall backward from sitting on a tatami mat differ strongly from those of the overwhelming majority of world literature that suggests that serious injury is extremely rare after short falls. Rather, this may reflect serious underdiagnosis of abuse at the time (1984) in that country.<sup>11</sup> Even if one accepts the author's attribution of the injuries to the stated falls, RH was only peripapillary and not widespread. Another study in which serious injuries from short falls were suggested suffered from many flaws including the absence of retinal examinations by ophthalmologists.<sup>38,39</sup> Although the author argued to the contrary,<sup>40</sup> research has shown that nonophthalmologists do well at identifying the absence or presence of RH but do not often offer descriptions as detailed as the examiner in the article and do not have the tools (indirect ophthalmoscope) to do so.<sup>8,39</sup> RH may be more common with epidural intracranial hemorrhage after single-impact trauma but confined to the posterior pole,<sup>41</sup> which indicates again that single acceleration-deceleration does not result in severe RH unless forces rise to the

level of fatal impacts or crush, and even then, such RHs are uncommon.

### Animal Models

Animal models have been limited by small eye size, which requires huge amounts of force to proportionately replicate SBS events. These forces would inevitably cause such tissue disruption, they are impractical. RH has been demonstrated even in rodents submitted to repeated acceleration-deceleration.<sup>42</sup> Animals that have been killed by shaking by other animals likely also represent poor models because of the unusual mechanism of injury.<sup>43</sup> In a pig model of unidirectional single acceleration-deceleration injury without impact, peripheral retinal and ciliary body hemorrhages have been found.<sup>44</sup> In cats, induction of shearing forces at the vitreoretinal interface induces disruption of vascular autoregulation with vascular dilation and porosity.<sup>45</sup> Prostaglandins, powerful mediators of vascular autoregulation, are felt to be a major etiologic mechanism in birth RH.<sup>46,47</sup> The orbital trauma of SBS includes damage to cranial nerves that carry autonomic supply to retinal vessels for autoregulation,<sup>35</sup> which suggests that the biochemical mediation of RH in SBS may occur via disrupted vascular autoregulation either from vitreoretinal traction at blood vessels and/or direct autonomic nerve disruption within the orbit.

### Mechanical and Finite Element Models

There is no mechanical eye model that has been used to investigate the pathophysiology of RH in SBS. Finite element analysis has been conducted.<sup>48-50</sup> By constructing a virtual globe and orbit, using available known tissue biomechanical properties and anatomy the model is then exercised using forces obtained from human shaking of bio-

delic infant dummies, hoping to predict sites within the eye where maximal tissue shear and stress will occur. One group found predicted high-stress areas corresponding with RH patterns seen in SBS victims.<sup>50</sup> The importance of damage to orbital tissues from repeated globe movements has also been suggested.<sup>48,49</sup> Applicability of finite element analysis is limited by poor age-appropriate human data regarding ocular and orbital tissue biochemical properties.

### Other Hypotheses

Despite the enormous multidimensional body of literature informing us of the critical role of vitreoretinal traction in generating RH in AHT, other factors have been suggested. Research has revealed little evidence to support their role in causing severe hemorrhagic retinopathy, which once again leads back to the importance of repeated acceleration-deceleration forces with or without head impact. In evaluating literature in these areas, one must avoid the pitfalls of applying data from adults to children, using data generated before SBS came into medical consciousness, and generalizing causation from studies in which clinical description of RH was nonspecific or mild to the more severe and extensive hemorrhages seen in most SBS cases.

RH alone should rarely if ever be used to diagnose child abuse without other supportive historical, physical, radiologic, and laboratory evidence that would also exclude or identify factors that offer alternative examples (eg, fatal motor vehicle accident, leukemia). A complete discussion of the differential diagnosis of RH is beyond the scope of this article. There is an enormous number of ocular and systemic entities that are associated with RH (Table 1). Ocular entities such as retinal hemangioma, cytomegalovirus infection,

**TABLE 1** Causes of RH in Children

|  |
|--|
| Abusive head injury                        |
| Accidental head trauma                     |
| Anemia                                     |
| Birth                                      |
| Blunt ocular trauma                        |
| Carbon monoxide poisoning                  |
| Cerebral aneurysm                          |
| Coagulopathy                               |
| Cytomegalovirus retinitis                  |
| Extracorporeal membrane oxygenation        |
| Glutaric aciduria                          |
| Hypernatremia/hyponatremia                 |
| Hypertension (associated with exudates)    |
| Increased ICP                              |
| Intraocular surgery                        |
| Leukemia                                   |
| Meningitis                                 |
| Osteogenesis imperfecta (with head trauma) |
| Papillitis                                 |
| Retinal hemangioma                         |
| Retinopathy of prematurity                 |
| Thrombocytopenia                           |

This is an incomplete list. None of the conditions listed cause severe hemorrhagic retinopathy except as noted in the text.

and juvenile X-linked retinoschisis are readily distinguished on the basis of their concomitant clinical ocular features. Systemic disorders associated with RH almost exclusively result in only a small number of preretinal or intraretinal hemorrhages in the posterior pole. Notable exceptions include normal birth and leukemia. The latter is readily distinguished by blood testing and the usual presence of leukemic retinal infiltrates. The hemorrhages associated with birth have been reviewed elsewhere.<sup>11</sup> Superficial hemorrhages are almost always gone by 1 week (usually by 3 days), and dot/blot hemorrhages are usually gone by 6 weeks (usually by 4 weeks). Therefore, such birth hemorrhages within these time frames cannot be distinguished from those in SBS, but those thereafter cannot be caused by birth. Retinoschisis has not been reported from birth despite studies of tens of thousands of newborns worldwide.

Let us now consider factors that are often present in cases of ill children in whom abuse is considered.



### Increased ICP

Papilledema is the hallmark of increased ICP. Small nerve-fiber layer hemorrhages on and around the optic nerve head and occasional prepapillary hemorrhages are common. Papilledema, and the secondary hemorrhages, are thought to result from disruption of axoplasmic flow and capillary nonperfusion. With raised ICP there is a concomitant dilation of the optic nerve sheath.<sup>51–53</sup> This, along with anatomic data,<sup>54</sup> confirms communication of intracranial subdural and subarachnoid spaces with the optic nerve sheath. The central retinal artery and vein enter/exit the optic nerve from the orbit in the anterior third of the orbital optic nerve. It has been hypothesized that transmission of increased ICP into the optic nerve sheath can compress the central retinal vein (CRV), which would lead to resistance of venous outflow from the retina while arterial inflow proceeds unimpeded, which would hypothetically cause RHs. The critical question is whether the extensive RHs seen in the majority of AHT cases can be caused in this fashion.

There are multiple lines of evidence that inform us that extensive RHs do not result from increased ICP. Papilledema occurs in <10% of cases of SBS.<sup>9,10</sup> To my knowledge, there has been no pediatric report of extensive RHs caused by increased ICP in the absence of abuse despite thousands of eye examinations of children with acute increased ICP from many other causes, although such examinations are not routine. Studies have confirmed the absence of extensive RHs caused by increased ICP.<sup>55,56</sup> In 1 study there was no correlation between signs of increased ICP and RHs in SBS.<sup>10</sup>

If hemorrhages were caused by CRV compression, one would expect to see RH patterns of CRV obstruction (CRVO), a well-known and easily recognized

ophthalmic entity in which severe intraretinal and preretinal RHs radiate out centripetally from the optic nerve, with dilated and tortuous retinal veins. This is rarely seen in cases of SBS and is generally uncommon in children.<sup>57</sup> In 3 large studies of AHT, CRVO was not observed.<sup>9,10,16</sup> Experimentally increased ICP in animals does not cause widespread RHs and rarely any hemorrhages at all.<sup>58</sup> Extensive RHs were not observed even when the CRV was occluded by increased intraocular pressure via a suction cup on the eye in human children.<sup>59</sup> It may be that there is compensatory decreased arterial pressure that protects the retina.<sup>60</sup> In other causes of restrained venous egress from the eye (see below), RHs are not seen.

Despite the evidence that fails to demonstrate an association of increased ICP and widespread RHs, there is some evidence that increased ICP plays at least some role, albeit not in isolation. Blood within the optic nerve sheath is sometimes used to imply transmitted ICP from the brain. The association of intracranial blood with intraocular blood (Terson syndrome) is common in adults with spontaneous subarachnoid hemorrhage, almost always with increased ICP. Optic nerve sheath blood is found in most cases of Terson syndrome and is commonly found in cases of SBS.<sup>32,35,61–63</sup> Yet, Terson syndrome is uncommon in children with non-AHT intracranial hemorrhage.<sup>64</sup> One study of 46 eyes from adults with fatal acutely raised ICP showed that hemorrhages beyond the peripapillary area were uncommon, but some did extend to the midperiphery or more peripherally.<sup>65</sup> The pattern was not that of CRVO. The authors of the study hypothesized that because of the unvalved orbital venous drainage and multiple venous collaterals, CRVO was unlikely the cause of RHs. They

pointed out that if the CRV is obstructed before it communicates with more anterior anastomotic channels (retinochoroidal), then choroidal drainage and ancillary vessels will allow adequate venous drainage. Intraocular hemorrhage is 2 to 3 times less common than optic nerve sheath hemorrhage, because although pressure within the sheath may damage vessels within the sheath, it may still be insufficient to cause CRVO and retinochoroidal anastomosis obstruction. Because retinochoroidal anastomoses lie outside the subarachnoid space, near the sclerodural junction, they may not be as susceptible to compression. Only if obstruction is anterior enough for the retinochoroidal anastomosis to also be obliterated could CRVO occur. The authors did observe a preferential dilation of the anterior optic nerve sheath (ampulla). They thought that this may become “compounded by the reflex systemic hypertension that commonly occurs in cases of severe” ICP.<sup>65</sup> But once again, the RH pattern they observed is not what is seen in cases of SBS, the patients are adults, and we know from other work that in SBS, optic nerve sheath dilation need not involve the anterior sheath, can be discontinuous or absent, and is not necessarily correlated with RH.<sup>35</sup> In an animal model, more anterior obstruction of the CRV was required to cause more extensive RHs.<sup>66</sup>

There have been a few reports of retinal or optic nerve neovascularization after SBS.<sup>67,68</sup> One report was of a peripheral retinal nonperfusion that, similar to neovascularization, can be a long-term outcome of adult CRVO in SBS.<sup>69</sup> Whether SBS neovascularization results from low-grade venous outflow obstruction is unknown. It may just as likely be induced by local vascular insufficiency caused by vitreoretinal traction.<sup>69</sup>

### *Increased Intrathoracic Pressure*

The rib fractures in SBS have led to theories that increased intrathoracic pressure results in restriction of CRV flow, which results in RHs. One group found no association between RH and rib fractures with SBS, although statistical analysis could not be performed.<sup>10</sup> Multiple conditions associated with increased intrathoracic pressure, such as seizures, cough, respiratory distress, or vomiting, are not associated with RH in children.<sup>70–76</sup> Other than a few hemorrhages in the posterior pole, RHs seem to be exceedingly rare after cardiopulmonary resuscitation with chest compressions,<sup>77–80</sup> including in a pig model.<sup>81</sup> Rare case reports that have suggested otherwise were complicated by multiple confounding systemic factors or poor evaluations to rule out abuse.<sup>82</sup> RHs can be seen in Purtscher retinopathy, a condition that often is caused by severe crush chest injury in adults and is characterized by polygonal white retinal patches. Such patches can rarely be seen in SBS.<sup>83</sup>

### *Hypoxia*

That hypoxia might be related in some way to hemorrhagic retinopathy in scenarios that resemble SBS came largely from the work of Geddes et al.<sup>84</sup> In that article, despite a long section discussing RH, there was no mention of a study of eyes or data directly referable to RH. Geddes et al, despite other interpretations,<sup>85</sup> clearly retracted this hypothesis under oath in court.<sup>86</sup> A detailed rebuttal of the hypoxia theory can be found elsewhere.<sup>87</sup> Clinically, thousands of hypoxic children are examined every year, but to my knowledge, there have been no documented cases of severe RH. Because there has been no formal prospective study, one must draw inference from related publications. In newborns, there is no correlation between RH and cyanosis.<sup>88</sup> RH seems not to be a manifestation

of acute life-threatening events or sudden unexplained infant death.<sup>18,89,90</sup> Other clinical situations with hypoxia, such as cyanotic congenital heart disease and vascular fistulas, are not associated with severe RH, although pediatric studies are not often available.<sup>91,92</sup> Hypoxia may play a role in possible progression of RH, but this is after the chain of abusive events that led to bleeding has taken place.<sup>15</sup> Although there are many laboratory models that have used isolated tissue preparations that show a vascular effect of hypoxia, many clinical animal models of retinal hypoxia have not demonstrated RH.<sup>45,93,94</sup>

### *Sodium Balance*

Children with severe brain injury may experience either centrally mediated or even iatrogenic major acute sodium shifts. In a study of children with vomiting, several of whom had sodium metabolism imbalances, no RHs were seen.<sup>72</sup> Two articles reported a total of 3 children with abnormal sodium levels and extensive RHs. In all 3 cases AHT was either the diagnosis or under continued consideration.<sup>95,96</sup> A child with hyponatremic seizures had a mild hemorrhagic retinopathy confined to the posterior pole.<sup>97</sup> Disorders of sodium balance have been postulated to be causative of intracranial hemorrhage.<sup>98–101</sup> Whether similar factors could be operant in the retina and lead to significant hemorrhagic retinopathy has not been widely studied or confirmed.

### *Bacterial Meningitis*

Infectious meningitis is a concern for children with systemic collapse and intracranial fluid collections. The diagnosis can be readily made with appropriate cultures. Yet, the topic has been raised in courtrooms as a possible etiologic factor even when culture results were negative or revealed only presumed contaminant organisms. There is little evidence to support cau-

sation of RH except in fulminant meningitis with grossly purulent cerebrospinal fluid, when there may be CRV necrosis leading to CRVO.<sup>102,103</sup> In other reports there were no hemorrhages, no details, or small numbers of hemorrhages confined to the posterior pole.<sup>104–106</sup> One teenager had a sub-ILM hemorrhage with some overlap with features of retinoschisis without folds but did not have other RHs and also had coagulopathy.<sup>107</sup>

### *Coagulopathy*

Mild or even moderate coagulopathy often accompanies severe brain injury.<sup>108</sup> Although there has not been a study of the retina in children with brain injury plus coagulopathy, severe hemorrhagic retinopathy, without leukemia, has not been reported from coagulopathy alone. One group reported subdural hemorrhage and posterior pole RHs in a child with a platelet-aggregation defect.<sup>109</sup> A 5-year-old died of HIV with multiple systemic complications and severe hemorrhagic retinopathy at autopsy, with many findings including coagulopathy that could have been contributory factors.<sup>110</sup> A child with severe vitamin K deficiency has been reported with somewhat extensive RHs.<sup>111</sup> Congenital protein C or S deficiency or disseminated intravascular coagulation can present with vitreous and intracranial hemorrhage in neonates.<sup>112,113</sup> Other case reports have shown no RHs in children with coagulopathy.<sup>114,115</sup>

In the absence of systematic study, it seems that RH only occurs with obvious severe coagulopathy that would be readily attributable to factors other than trauma with appropriate diagnostic testing. The question of whether severe disseminated intravascular coagulation in a severely traumatized child could aggravate hemorrhagic retinopathy and, if so, to what degree remains unknown. One would be remiss to attribute an ex-

tensive hemorrhagic retinopathy to coagulopathy in the absence of widespread hemorrhage involving a number of other organ systems.

### Anemia

The overwhelming majority of researchers who have reported retinal manifestations of anemia have studied adults. It seems that severe anemia with thrombocytopenia is required to develop RH, usually mild and confined to the posterior pole.<sup>116–118</sup> To my knowledge there has only been 1 article to report retinal findings in a case of anemia caused by blood loss.<sup>118</sup> In another study, RH was always seen in the presence of either papilledema, optic atrophy, or retinal exudates. Biousee et al<sup>119</sup> purported to have reviewed the world's literature and found the youngest child with RHs resulting from anemia to have been 4 years old with no intracranial hemorrhage, erythroblastopenia, and a hemoglobin level of 7.18/dL. Mansour<sup>120</sup> reported that RHs caused by aplastic anemia are less common in children. There is a case report of retinoschisis-like sub-ILM hemorrhage in a 6-year-old with aplastic anemia.<sup>121</sup> It seems that severe hemorrhagic retinopathy does not result from isolated anemia in children without readily identifiable causes unrelated to trauma.

### Unknowns

It is important to note that there are many factors in the development of RHs, but their influence remains un-

known. For example, 5% of the general population in North America has thrombophilia. Thrombophilia has been associated with adult CRVO.<sup>122</sup> Trauma predisposes to thrombosis. What would be the retinal effects of thrombophilia in a child who sustains a short fall that otherwise would not be expected to cause RH? I have cared for such a child with severe RH who was presumed to be abused despite the presence of anticardiolipin antibody and history of a short fall.

Subclinical vitamin C deficiency also exists in the general population.<sup>123</sup> Although I am unaware of a well-documented case of significant RHs caused by vitamin C deficiency, the question remains as to the role it might play. Some have even argued, with limited evidence, that routine immunization could lead to decreased vitamin C levels as a result of elevated histamine levels.<sup>124</sup> Most of the studies on vitamin C deficiency, however, used serum levels. Accurate study will require the use of lymphocyte vitamin C levels.<sup>125</sup> Normal values have recently been generated for children (data not shown). Despite these questions, there is little, if any, evidence to support thrombophilia or vitamin C deficiency<sup>126</sup> as a viable cause of severe hemorrhagic retinopathy. Additional research is required.

Last, we do not know the effect of multiple simultaneous factors. Outlier cases often raise the question of a single factor causing an SBS-like picture

when there are multiple factors present, the cumulative effect of which is unknown.<sup>82,96</sup> Thousands of children are examined annually by ophthalmologists when many of these factors, such as increased ICP, coagulopathy, anemia, and hypoxia, coexist, yet significant hemorrhagic retinopathy is not found. Studying the influence of concomitant factors in the setting of head injury is difficult, and perhaps these factors may contribute to the potential for worsening of RHs once the cascade of events is set in motion by the initial trauma.

### CONCLUSIONS

The overwhelming body of literature supports a conclusion that severe hemorrhagic retinopathy in otherwise previously well children without obvious history to the contrary (eg, fatal head crush) suggests that the child has been submitted to abusive repetitive acceleration-deceleration trauma with or without head impact. Some continue to challenge this literature and attempt to raise controversy.<sup>127–130</sup> Further research is indicated to answer remaining queries. Until such time, physicians should keep an open mind to and appropriately search and test for alternate explanations while appropriately weighting the strong available evidence to ensure that a child remains protected from harm.

### ACKNOWLEDGMENT

This work was funded, in part, by the Foerderer Fund.

### REFERENCES

1. Aikman J. Cerebral hemorrhage in infant, aged eight months: recovery [in French]. *Arch Pediatr*. 1928;45:56–58
2. Hollenhorst R, Stein H. Ocular signs and prognosis in subdural and subarachnoid bleeding in young children. *AMA Arch Ophthalmol*. 1958;60(2):187–192
3. Till K. Subdural haematoma and effusion in infancy. *Br Med J*. 1968;3(5615):400–402
4. Guthkelch AN. Infantile subdural haematoma and its relationship to whiplash injuries. *Br Med J*. 1971;2(5759):430–431
5. Caffey J. On the theory and practice of shaking infants. *Am J Dis Child*. 1972;124(2):161–169
6. Caffey J. The whiplash shaken infant syndrome: manual shaking by the extremities with whip-lash-induced intracranial and intraocular bleedings, linked with residual permanent brain damage and mental retardation. *Pediatrics*. 1974;54(4):396–403
7. Christian CW, Block R; American Academy of Pediatrics, Committee on Child Abuse and Neglect. Abusive head trauma in infants and children. *Pediatrics*. 2009;123(5):1409–1411
8. Morad Y, Kim Y, Mian M, Huyer D, Levin A. Non-ophthalmologists' accuracy in diagnosing retinal hemorrhages in the shaken



- baby syndrome. *J Pediatr.* 2003;142(4):431–434
9. Kivlin J, Simons K, Lazorit S, Ruttum M. Shaken baby syndrome. *Ophthalmology.* 2000;107(7):1246–1254
  10. Morad Y, Kim Y, Armstrong D, Huyer D, Mian M, Levin A. Correlation between retinal abnormalities and intracranial abnormalities in the shaken baby syndrome. *Am J Ophthalmol.* 2002;134(3):354–359
  11. Levin A. Retinal haemorrhage and child abuse. In: David T, ed. *Recent Advances in Paediatrics. Vol 18.* London, United Kingdom: Churchill Livingstone; 2000:151–219
  12. Morad Y, Avni I, Benton S, et al. Normal computerized tomography of brain in children with shaken baby syndrome. *J AAPOS.* 2004;8(5):445–450
  13. Morad Y, Avni I, Capra L, et al. Shaken baby syndrome without intracranial hemorrhage on initial computed tomography. *J AAPOS.* 2004;8(6):521–527
  14. Greenwald M, Weiss A, Oesterle C, Friendly D. Traumatic retinoschisis in battered babies. *Ophthalmology.* 1986;93(5):618–625
  15. Gilles E, McGregor M, Levy-Clarke G. Retinal hemorrhage asymmetry in inflicted head injury: a clue to pathogenesis? *J Pediatr.* 2003;143(4):494–499
  16. Bechtel K, Stoessel K, Leventhal JM, et al. Characteristics that distinguish accidental from abusive injury in hospitalized young children with head trauma. *Pediatrics.* 2004;114(1):165–168
  17. Binenbaum G, Mirza-George N, Christian CW, Forbes BJ. Odds of abuse associated with retinal hemorrhages in children suspected of child abuse. *J AAPOS.* 2009;13(3):268–272
  18. Riffenburgh R. Ocular hemorrhage in autopsies of child abuse victims. *Clin Surg Ophthalmol.* 2005;23(5):178–186
  19. Dashti S, Decker D, Razaq A, Cohen A. Current patterns of inflicted head injury in children. *Pediatr Neurosurg.* 1999;31(6):302–306
  20. Duhaime A, Alario A, Lewander W, et al. Head injury in very young children: mechanism, injury types, and ophthalmologic findings in 100 hospitalized patients younger than 2 years of age. *Pediatrics.* 1992;90(2 pt 1):179–185
  21. Vinchon M, Defoort-Dhellemmes S, Desurmont M, Dhellemmes P. Accidental and nonaccidental head injuries in infants: a prospective study. *J Neurosurg.* 2005;102(4 suppl):380–384
  22. Vinchon M, Noizet O, Defoort-Dhellemmes S, Soto-Ares G, Dhellemmes P. Infantile subdural hematoma due to traffic accidents. *Pediatr Neurosurg.* 2002;37(5):245–253
  23. Kivlin JD, Currie ML, Greenbaum VJ, Simons KB, Jentzen J. Retinal hemorrhages in children following fatal motor vehicle crashes: a case series. *Arch Ophthalmol.* 2008;126(6):800–804
  24. Scott AW, Farsiou S, Enyedi LB, Wallace DK, Toth CA. Imaging the infant retina with a hand-held spectral-domain optical coherence tomography device. *Am J Ophthalmol.* 2009;147(2):364.e2–373.e2
  25. Muni RH, Kohly RP, Sohn EH, Lee TC. Hand-held spectral domain optical coherence tomography finding in shaken-baby syndrome. *Retina.* 2010;30(4 suppl):S45–S50
  26. Muni RH, Kohly RP, Charonis AC, Lee TC. Retinoschisis detected with handheld spectral-domain optical coherence tomography in neonates with advanced retinopathy of prematurity. *Arch Ophthalmol.* 2010;128(1):57–62
  27. Lueder GT, Turner JW, Paschall R. Perimacular retinal folds simulating nonaccidental injury in an infant. *Arch Ophthalmol.* 2006;124(12):1782–1783
  28. Lantz PE, Sinal SH, Stanton CA, Weaver RG Jr. Perimacular retinal folds from childhood head trauma. *BMJ.* 2004;328(7442):754–756
  29. Moran K, Reddie I, Jacobs M. Severe hemorrhagic retinopathy and traumatic retinoschisis in a 2 year old infant, after an 11 metre fall onto concrete. *Acta Paediatr.* 2008;97(suppl 459):149
  30. Gnanaraj L, Gilliland M, Yahya R, et al. Ocular manifestations of crush head injury in children. *Eye (Lond).* 2007;21(1):5–10
  31. Levin AV. Retinal hemorrhages of crush head injury: learning from outliers. *Arch Ophthalmol.* 2006;124(12):1773–1774
  32. Matschke J, Püschel K, Glatzel M. Ocular pathology in shaken baby syndrome and other forms of infantile non-accidental head injury. *Int J Legal Med.* 2009;123(3):189–197
  33. Munger C, Peiffer R, Bouldin T, Klystra J, Thompson R. Ocular and associated neuropathologic observations in suspected whiplash shaken infant syndrome: a retrospective study of 12 cases. *Am J Forensic Med Pathol.* 1993;14(3):193–200
  34. Brownstein S, Dorey M. The spectrum of postmortem ocular findings in victims of shaken baby syndrome. *Can J Ophthalmol.* 2002;37(1):4
  35. Wygnanski-Jaffe T, Levin AV, Shafiq A, et al. Postmortem orbital findings in shaken baby syndrome. *Am J Ophthalmol.* 2006;142(2):233–240
  36. Elnor S, Elnor V, Arnall M, Albert D. Ocular and associated systemic findings in suspected child abuse: a necropsy study. *Arch Ophthalmol.* 1990;108(8):1094–1101
  37. Lin K, Glasgow B. Bilateral periopticointracranial hemorrhages associated with traumatic child abuse. *Am J Ophthalmol.* 1999;127(4):473–475
  38. Plunkett J. Fatal pediatric head injuries caused by short-distance falls. *Am J Forensic Med Pathol.* 2001;22(1):1–12
  39. Levin A. Fatal pediatric head injuries caused by short-distance falls. *Am J Forensic Med Pathol.* 2001;22(4):417–418
  40. Plunkett J. Author's response to Drs. Spivack and Levin. *Am J Forensic Med Pathol.* 2001;22(4):418
  41. Forbes B, Christina C, Cox M. Retinal hemorrhages in patients with epidural hematomas. *J AAPOS.* 2008;12(2):177–180
  42. Bonnier C, Mesplès B, Carpentier S, Henin D, Gressens P. Delayed white matter injury in a murine model of shaken baby syndrome. *Brain Pathol.* 2002;12(3):320–328
  43. Serbanescu I, Brown S, Ramsay D, Levin A. Natural animal shaking: a model for inflicted neurotrauma in children? *Eye (Lond).* 2008;22(5):715–717
  44. Coats B, Binenbaum G, Peiffer RL, Forbes BJ, Margulies SS. Ocular hemorrhages in neonatal porcine eyes from single, rapid rotational events. *Invest Ophthalmol Vis Sci.* 2010;51(9):4792–4797
  45. Nagaoka T, Sakamoto T, Mori F, Sato E, Yoshida A. The effect of nitric oxide on retinal blood flow during hypoxia in cats. *Invest Ophthalmol Vis Sci.* 2002;43(9):3037–3044
  46. Gonzalez Viejo I, Ferrer Novella C, Pueyo Subias M, et al. Hemorrhagic retinopathy in newborns: frequency, form of presentation, associated factors and significance. *Eur J Ophthalmol.* 1995;5(4):247–250
  47. Schoenfeld A, Buckman G, Nissenkorn I, Cohen S, Ben-Sira I, Ovadia J. Retinal hemorrhages in the newborn following labor induced by oxytocin or dinoprostone. *Arch Ophthalmol.* 1985;103(7):932–934
  48. Cirovic S, Bholá RM, Hose DR, Howard IC, Lawford PV, Parsons MA. A computational study of the passive mechanisms of eye restraint during head impact trauma. *Comput Methods Biomech Biomed Engin.* 2005;8(1):1–6
  49. Cirovic S, Bholá RM, Hose DR, Howard IC, Lawford PV, Parsons MA. Mechanistic hypothesis for eye injury in infant shaking: an experimental and computational study. *Forensic Sci Med Pathol.* 2005;1(1):53–59

50. Rangarajan N, Kamalakkannan S, Hasija H, et al. Finite element model of ocular injury in shaken baby syndrome. *J AAPOS*. 2009;13(4):364–369
51. Blaivas M, Theodoro D, Sierzanski PR. Elevated intracranial pressure detected by bedside emergency ultrasonography of the optic nerve sheath. *Acad Emerg Med*. 2003;10(4):376–381
52. Hansen H, Helmke K. Validation of the optic nerve sheath response to changing cerebrospinal fluid pressure: ultrasound findings during intrathecal infusion tests. *J Neurosurg*. 1997;87(1):34–40
53. Hansen H, Helmke K, Kunze K. Optic nerve sheath enlargement in acute intracranial hypertension. *Neuroophthalmology*. 1994;14(6):345–354
54. Hansen H, Helmke K. The subarachnoid space surrounding the optic nerves: an ultrasound study of the optic nerve sheath. *Surg Radiol Anat*. 1996;18(4):323–328
55. Tzekov C, Cherninkova S, Gudeva T. Neuroophthalmological symptoms in children treated for internal hydrocephalus. *Pediatr Neurosurg*. 1991;17(6):317–320
56. Nazir S, O'Brien M, Qureshi N, Slape L, Green T, Phillips P. Sensitivity of papilloedema as a sign of shunt failure in children. *J AAPOS*. 2009;13(1):63–66
57. Hoffman R, Mamalis N, Frasier L. Ophthalmology: photographic examples. In: Frasier L, Rauth-Farley K, Alexander R, Parrish R, eds. *Abusive Head Trauma in Infants and Children*. St Louis, MO: G.W. Medical Publishing, Inc; 2006:151–159
58. Hayreh S. Pathogenesis of oedema of the optic disc. *Doc Ophthalmol*. 1968;24(2):289–411
59. Firsching R, Schutze M, Motschmann M, Behrens-Baumann W. Venous ophthalmodynamometry: a noninvasive method for assessment of intracranial pressure. *J Neurosurg*. 2000;93(1):33–36
60. Hedges T, Weinstein J. Cerebrovascular responses to increased intracranial pressure. *J Neurosurg*. 1964;21:292–297
61. Case ME. Inflicted traumatic brain injury in infants and young children. *Brain Pathol*. 2008;18(4):571–582
62. Lambert S, Johnson T, Hoyt C. Optic nerve sheath hemorrhages associated with the shaken baby syndrome. *Arch Ophthalmol*. 1986;104(10):1509–1512
63. Marshall D, Brownstein S, Dorey M, Addison D, Carpenter B. The spectrum of post-mortem ocular findings in victims of shaken baby syndrome. *Can J Ophthalmol*. 2001;36(7):377–384
64. Schloff S, Mullaney P, Armstrong D, et al. Retinal findings in children with intracranial hemorrhage. *Ophthalmology*. 2002;109(8):1472–1476
65. Muller P, Deck J. Intraocular and optic nerve sheath hemorrhage in cases of sudden intracranial hypertension. *J Neurosurg*. 1974;41(2):160–166
66. Fujino T, Curtin V, Norton E. Experimental central retinal vein occlusion: a comparison of intraocular and extraocular occlusion. *Arch Ophthalmol*. 1969;81(3):395–406
67. Brown S, Shami M. Optic disc neovascularization following severe retinoschisis due to the shaken baby syndrome. *Arch Ophthalmol*. 1999;117(6):838–839
68. Caputo G, de Haller R, Metge F, Dureau P. Ischemic retinopathy and neovascular proliferation secondary to shaken baby syndrome. *Retina*. 2008;28(3 suppl):S42–S46
69. Goldenberg DT, Wu D, Capone A, Jr, Dresner KA, Trese MT. Nonaccidental trauma and peripheral retinal nonperfusion. *Ophthalmology*. 2010;117(3):561–566
70. Sandramouli S, Robinson R, Tsaloumas M, Willshaw H. Retinal haemorrhages and convulsions. *Arch Dis Child*. 1997;76(5):449–451
71. Goldman M, Dağan Z, Yair M, Elbaz U, Lahat E, Yair M. Severe cough and retinal hemorrhage in infants and young children. *J Pediatr*. 2006;148(6):835–836
72. Herr S, Pierce M, Berger R, Ford H, Pitetti R. Does Valsalva retinopathy occur in infants? An initial investigation in infants with vomiting caused by pyloric stenosis. *Pediatrics*. 2004;113(6):1658–1661
73. Curcoy AI, Trenchs V, Morales M, Serra A, Pineda M, Pou J. Do retinal hemorrhages occur in infants with convulsions? *Arch Dis Child*. 2009;94(11):873–875
74. Mei-Zahav M, Uziel Y, Raz J, Ginot N, Wolach B, Fainmesser P. Convulsions and retinal haemorrhage: should we look further? *Arch Dis Child*. 2002;86(5):334–335
75. Tyagi A, Scotcher S, Kozeis N, Willshaw H. Can convulsions alone cause retinal haemorrhages in infants? *Br J Ophthalmol*. 1998;82(2):659–660
76. Altman RL, Forman S, Brand DA. Ophthalmologic findings in infants after an apparent life-threatening event. *Eur J Ophthalmol*. 2007;17(4):648–653
77. Goetting M, Sowa B. Retinal haemorrhage after cardiopulmonary resuscitation in children: an etiologic evaluation. *Pediatrics*. 1990;85(4):585–588
78. Gilliland M, Luckenbach M. Are retinal hemorrhages found after resuscitation attempts? A study of the eyes of 169 children. *Am J Forensic Med Pathol*. 1993;14(3):187–192
79. Odom A, Christ E, Kerr N, et al. Prevalence of retinal hemorrhages in pediatric patients after in-hospital cardiopulmonary resuscitation: a prospective study. *Pediatrics*. 1997;99(6). Available at: [www.pediatrics.org/cgi/content/full/99/6/e3](http://www.pediatrics.org/cgi/content/full/99/6/e3)
80. Kanter R. Retinal hemorrhage after cardiopulmonary resuscitation or child abuse. *J Pediatr*. 1986;108(3):430–432
81. Fackler J, Berkowitz I, Green R. Retinal hemorrhage in newborn piglets following cardiopulmonary resuscitation. *Am J Dis Child*. 1992;146(11):1294–1296
82. Weedn V, Mansour A, Nichols M. Retinal hemorrhage in an infant after cardiopulmonary resuscitation. *Am J Forensic Med Pathol*. 1990;11(1):79–82
83. Tomasi L, Rosman P. Purtscher retinopathy in the battered child syndrome. *Am J Dis Child*. 1975;129(11):1335–1337
84. Geddes J, Tasker R, Hackshaw A, et al. Dural haemorrhage in non-traumatic infant deaths: does it explain the bleeding in “shaken baby syndrome?” [published correction appears in *Neuropathol Appl Neurobiol*. 2003;29(3):322] *Neuropathol Appl Neurobiol*. 2003;29(1):14–22
85. Squier W. Nonaccidental trauma: clinical aspects and epidemiology of child abuse. *Pediatr Radiol*. 2009;39(7):758
86. Richards P, Bertocci G, Bonshek R, et al. Shaken baby syndrome. *Arch Dis Child*. 2006;91(3):205–206
87. Punt J, Bonshek R, Jaspán T, McConachie N, Punt N, Ratcliffe J. The “unified hypothesis” of Geddes et al. is not supported by the data. *Pediatr Rehabil*. 2004;7(3):173–184
88. Giles C. Retinal hemorrhages in the newborn. *Am J Ophthalmol*. 1960;49:1005–1011
89. Pitetti R, Maffei F, Chang K, Hickey R, Berger R, Pierce M. Prevalence of retinal hemorrhages and child abuse in children who present with an apparent life-threatening event. *Pediatrics*. 2002;110(3):557–562
90. Bajanowski T, Vennemann M, Bohnert M, Rauch E, Brinkmann B, Mitchell EA; GeSID Group. Unnatural causes of sudden unexpected deaths initially thought to be sudden infant death syndrome. *Int J Legal Med*. 2005;119(4):213–216
91. Petersen R, Rosenthal A. Retinopathy and papilledema in cyanotic congenital heart disease. *Pediatrics*. 1972;49(2):243–249
92. Sanders M, Hoyt W. Hypoxic ocular sequelae of carotid-cavernous fistulae:

- study of the causes of visual failure before and after neurosurgical treatment in a series of 25 cases. *Br J Ophthalmol*. 1969;53(2):82–97
93. Kaur C, Sivakumar V, Foulds W. Early response of neurons and glial cells to hypoxia in the retina. *Invest Ophthalmol Vis Sci*. 2006;47(3):1126–1141
  94. Zheng L, Gong B, Hatala DA, Kern TS. Retinal ischemia and reperfusion causes capillary degeneration: similarities to diabetes. *Invest Ophthalmol Vis Sci*. 2007;48(1):361–367
  95. Krugman S, Zorc J, Walker A. Hyponatremic seizures in infancy: association with retinal hemorrhages and physical child abuse? *Pediatr Emerg Care*. 2000;16(6):423–425
  96. Fenton S, Murray D, Thornton P, Kennedy S, O'Keefe M. Bilateral massive retinal hemorrhages in a 6-month-old infant: a diagnostic dilemma. *Arch Ophthalmol*. 1999;117(10):1432–1440
  97. Rubin D, Christian C. Retinal hemorrhages in infants with hyponatremic seizures. *Pediatr Emerg Care*. 2001;17(4):313–314
  98. Finberg L. Pathogenesis of lesions in the nervous system in hypernatremic states: I. Clinical observations of infants. *Pediatrics*. 1959;23(1 pt 1):40–45
  99. Finberg L, Harrison H. Hyponatremia in infants. *Pediatrics*. 1955;16(1):1–12
  100. Han B, Lee M, Yoon H. Cranial ultrasound and CT findings in infants with hypernatremic dehydration. *Pediatr Radiol*. 1997;27(9):739–742
  101. Handy T, Hanzlick R, Shields L, Reichard R, Goudy S. Hyponatremia and subdural hematoma in the pediatric age group: is there a causal relationship? *J Forensic Sci*. 1999;44(6):1114–1118
  102. Gilliland M, Luckenbach M, Chenier T. Systemic and ocular findings in 169 prospectively studied child deaths: retinal hemorrhages usually mean child abuse. *Forensic Sci Int*. 1994;68(2):117–132
  103. Lopez J, Roque J, Torres J, Levin A. Severe retinal hemorrhages in infants with aggressive fatal *Streptococcus pneumoniae* meningitis. *J AAPOS*. 2010;14(1):97–98
  104. Fraser S, Horgan S, Bardavio J. Retinal haemorrhage in meningitis. *Eye (Lond)*. 1995;9(pt 5):659–660
  105. Dinakaran S, Chan T, Rogers N, Brosnahan D. Retinal hemorrhage in meningococcal septicemia. *J AAPOS*. 2002;6(4):221–223
  106. Hobbs C. Subdural haematoma and effusion in infancy: an epidemiological study. *Arch Dis Child*. 2005;90(9):952–955
  107. Sung V, Murray D, Price N. Subhyaloid or subinternal limiting membrane haemorrhage in meningococcal meningitis. *Br J Ophthalmol*. 2000;84(10):1206–1207
  108. Hymel K, Abshire T, Luckey D, Jenny C. Coagulopathy in pediatric abusive head trauma. *Pediatrics*. 1997;99(3):371–375
  109. Russell-Eggitt I, Thompson D, Khair K, Liesner R. Hermansky-Pudlak syndrome presenting with subdural haematoma and retinal haemorrhages in infancy. *J R Soc Med*. 2000;93(11):591–592
  110. Lertsumitkul S, Whitcup S, Chan C. Ocular manifestations of disseminated intravascular coagulation in a patient with the acquired immunodeficiency syndrome. *Arch Ophthalmol*. 1997;115(5):676–677
  111. Goldman HI, Deposito F. Hypoprothrombinemic bleeding in young infants: association with diarrhea, antibiotics, and milk substitutes. *Am J Dis Child*. 1966;111(4):430–432
  112. Khan NM, Al-Dohayan ND, Al-Batiniji FS. Bilateral leukocoria in a patient with homozygous protein C deficiency. *Saudi Med J*. 2007;28(7):1129–1132
  113. Wiznia R, Price J. Vitreous hemorrhages and disseminated intravascular coagulation in the newborn. *Am J Ophthalmol*. 1976;82(2):222–226
  114. Larsen P, Wallace J, Frankel L, Crisp D. Factor XIII deficiency and intracranial hemorrhages in infancy. *Pediatr Neurol*. 1990;6(4):277–278
  115. Bray G, Luban N. Hemophilia presenting with intracranial hemorrhage: an approach to the infant with intracranial bleeding and coagulopathy. *Am J Dis Child*. 1987;141(11):1215–1217
  116. Carraro M, Rossetti L, Gerli G. Prevalence of retinopathy in patients with anemia or thrombocytopenia. *Eur J Haematol*. 2001;67(4):238–244
  117. Cosnett J, Macleod I. Retinal haemorrhages in severe anaemias: their diagnostic significance. *Br Med J*. 1959;2(5158):1002–1004
  118. Foster R. The incidence of retinal haemorrhages in severe anaemia. *Trans R Soc Trop Med Hyg*. 1970;64(1):99–101
  119. Biousse V, Rucker J, Vignal C, Crassard I, Katz B, Newman N. Anemia and papilloedema. *Am J Ophthalmol*. 2003;135(4):437–446
  120. Mansour A. Aplastic anemia simulating central retinal vein occlusion. *Am J Ophthalmol*. 1985;100(3):478–479
  121. Wong V, Bodey G. Hemorrhagic retinoschisis due to aplastic anemia. *Arch Ophthalmol*. 1968;80(4):433–435
  122. Van Cott E, Laposata M, Hartnett M. Prothrombin gene mutation G20210A, homocysteine, antiphospholipid antibodies and other hypercoagulable states in ocular thrombosis. *Blood Coagul Fibrinolysis*. 2004;15(5):393–397
  123. Johnston C, Thompson M. Vitamin C status of an out-patient population. *J Am Coll Nutr*. 1998;17(4):366–370
  124. Clemetson C. Histamine and ascorbic acid in human blood. *J Nutr*. 1980;110(4):662–668
  125. Emadi-Konjin P, Verjee Z, Levin A, Adeli K. Measurement of intracellular vitamin C level in human lymphocytes by reverse phase high performance liquid chromatography (HPLC). *Clin Biochem*. 2005;38(5):450–456
  126. Fung E, Nelson E. Could vitamin C deficiency have a role in shaken baby syndrome? *Pediatr Int*. 2004;46(6):753–755
  127. Geddes JF, Plunkett J. The evidence base for shaken baby syndrome. *BMJ*. 2004;328(7442):719–720
  128. Squier W. Shaken baby syndrome: the quest for evidence. *Dev Med Child Neurol*. 2008;50(1):10–14
  129. Clarke MP. Vitreoretinal traction is a major factor in causing the haemorrhagic retinopathy of abusive head injury? *No. Eye (Lond)*. 2009;23(9):1761–1763
  130. Chong N. Perimacular retinal folds and nonaccidental injury: yes, no, or maybe? *Eye (Lond)*. 2007;21(1):3–4

---

## ERRATA

**Levin AV. Retinal Hemorrhage in Abusive Head Trauma. *Pediatrics*. 2010;126(5): 961–970**

An error occurred in this article by Levin (doi: 10.1542/peds.2010-1220). The author did not identify any conflict of interest; however, in accordance with the policies of *Pediatrics*, Dr Levin declares that he has received compensation as an expert witness for both the prosecution and the defense in cases related to child abuse and shaken-baby syndrome.

doi:10.1542/peds.2010-3370

**Adams HR, Szilagyi PG, Gebhardt L, Lande MB. Learning and Attention Problems Among Children With Pediatric Primary Hypertension. *Pediatrics*. 2010;126(6): e1425–e1429**

Errors occurred in this article by Adams et al (doi: 10.1542/peds.2010-1899). There were various errors in Tables 1 and 2. These errors are summarized below:

Table 1, page e1427:

1. The second column's heading reads: "No Hypertension ( $N = 100$ ).” This should have read: "No Hypertension ( $N = 101$ ).”
2. The third column's heading reads: "Hypertension ( $N = 101$ ).” This should have read: "Hypertension ( $N = 100$ ).”
3. The "Male/female, %" sample size reported reads: "70/30.” This should have read: "71/30.”

Table 2, page e1427:

1. The second column's heading reads: "No Hypertension ( $N = 100$ ).” This should have read: "No Hypertension ( $N = 101$ ).”
2. The third column's heading reads: "Hypertension ( $N = 101$ ).” This should have read: "Hypertension ( $N = 100$ ).”

doi:10.1542/peds.2010-3606



## Retinal Hemorrhage in Abusive Head Trauma

Alex V. Levin

*Pediatrics* 2010;126;961; originally published online October 4, 2010;

DOI: 10.1542/peds.2010-1220

|   |   |
|---|---|
| <b>Updated Information &amp; Services</b> | including high resolution figures, can be found at:<br><a href="http://pediatrics.aappublications.org/content/126/5/961.full.html">http://pediatrics.aappublications.org/content/126/5/961.full.html</a>  |
| <b>References</b>                         | This article cites 128 articles, 30 of which can be accessed free at:<br><a href="http://pediatrics.aappublications.org/content/126/5/961.full.html#ref-list-1">http://pediatrics.aappublications.org/content/126/5/961.full.html#ref-list-1</a>                          |
| <b>Citations</b>                          | This article has been cited by 2 HighWire-hosted articles:<br><a href="http://pediatrics.aappublications.org/content/126/5/961.full.html#related-urls">http://pediatrics.aappublications.org/content/126/5/961.full.html#related-urls</a>                                 |
| <b>Subspecialty Collections</b>           | This article, along with others on similar topics, appears in the following collection(s):<br><b>Ophthalmology</b><br><a href="http://pediatrics.aappublications.org/cgi/collection/ophthalmology">http://pediatrics.aappublications.org/cgi/collection/ophthalmology</a> |
| <b>Errata</b>                             | An erratum has been published regarding this article. Please see:<br><a href="http://pediatrics.aappublications.org/content/127/2/398.1.full.html">http://pediatrics.aappublications.org/content/127/2/398.1.full.html</a>  |
| <b>Permissions &amp; Licensing</b>        | Information about reproducing this article in parts (figures, tables) or in its entirety can be found online at:<br><a href="http://pediatrics.aappublications.org/site/misc/Permissions.xhtml">http://pediatrics.aappublications.org/site/misc/Permissions.xhtml</a>     |
| <b>Reprints</b>                           | Information about ordering reprints can be found online:<br><a href="http://pediatrics.aappublications.org/site/misc/reprints.xhtml">http://pediatrics.aappublications.org/site/misc/reprints.xhtml</a>   |

PEDIATRICS is the official journal of the American Academy of Pediatrics. A monthly publication, it has been published continuously since 1948. PEDIATRICS is owned, published, and trademarked by the American Academy of Pediatrics, 141 Northwest Point Boulevard, Elk Grove Village, Illinois, 60007. Copyright © 2010 by the American Academy of Pediatrics. All rights reserved. Print ISSN: 0031-4005. Online ISSN: 1098-4275.

American Academy of Pediatrics

DEDICATED TO THE HEALTH OF ALL CHILDREN™

