

PediatricsⁱⁿReview[®]

Childhood Brain Tumors

John Crawford

Pediatrics in Review 2013;34;63

DOI: 10.1542/pir.34-2-63

The online version of this article, along with updated information and services, is located on the World Wide Web at:

<http://pedsinreview.aappublications.org/content/34/2/63>

Pediatrics in Review is the official journal of the American Academy of Pediatrics. A monthly publication, it has been published continuously since 1979. Pediatrics in Review is owned, published, and trademarked by the American Academy of Pediatrics, 141 Northwest Point Boulevard, Elk Grove Village, Illinois, 60007. Copyright © 2013 by the American Academy of Pediatrics. All rights reserved. Print ISSN: 0191-9601.

American Academy of Pediatrics

DEDICATED TO THE HEALTH OF ALL CHILDREN™



Childhood Brain Tumors

John Crawford, MD, MS*

Author Disclosure
Dr Crawford has disclosed no financial relationships relevant to this article. This commentary does contain a discussion of an unapproved/investigative use of a commercial product/device.

Educational Gap

Brain tumors are the most common solid tumor of childhood and the No. 1 cause of death among all childhood cancers. The pediatrician is pivotal in both the diagnosis and long-term management of brain tumors. A lack of awareness of the clinical signs and symptoms of brain tumors may delay diagnosis and worsen patient outcomes.

Objectives

After completing this article, readers should be able to:

1. Recognize the presenting signs of brain tumor (eg, headache, deteriorating school performance, ataxia, emesis).
2. Recognize the signs and symptoms of craniopharyngioma.

Introduction

Each year, more than 4,000 brain and central nervous system (CNS) tumors are reported in children age 0 to 19 years in the United States, according to the most recent data from the Central Brain Tumor Registry of the United States. (1) Although the incidence of five per 100,000 person-years is rare compared with other childhood malignancies, brain tumors are the most common solid tumor of childhood. Most importantly, brain tumors are the No. 1 cause of death among all childhood cancers, according to surveillance, epidemiology, and survival data. (2) Childhood brain tumors represent an anatomically and biologically diverse group of neoplasms that can present with both common and unusual symptoms. A lack of awareness of the clinical signs and symptoms of brain tumors may lead to a delayed diagnosis by clinicians.

The pediatrician is pivotal in both the diagnosis and long-term management of brain tumors. This primary care-focused review will offer a practical overview of childhood brain tumors, including diagnosis, classification, management, and both early and late effects. Potential late effects of therapy include neurocognitive deficits, endocrinopathies, vasculopathies, and development of secondary neoplasms. A greater awareness of the clinical and neurologic warning signs associated with the presence of a brain tumor may allow earlier diagnosis and possibly affect outcomes.

Brain Tumor Classification, Epidemiology, and Pathogenesis

The current classification of primary brain tumors is based on histologic criteria presented by the World Health Organization (WHO). (3) Brain tumors are broadly classified according to the cell of origin and most commonly are neuroepithelial derived. WHO classification categories of primary brain tumors include tumors of the neuroepithelium, cranial nerves, meninges, and sella, as well as those of hematopoietic and germ cell origin.

Among the neuroepithelial tumors, gliomas are the most common brain tumors of childhood, occurring at an incidence of 1.16 per 100,000 person-years. (1) Gliomas are astrocyte-derived tumors and are graded 1 through 4, according to increasing degree of aggressiveness. Juvenile pilocytic astrocytoma and diffuse fibrillary astrocytoma represent the majority of low-grade gliomas (WHO grades I and II), whereas anaplastic

Abbreviations

CNS: central nervous system
CSF: cerebrospinal fluid
CT: computed tomography
MRI: magnetic resonance imaging
NF-1: neurofibromatosis type 1
NF-2: neurofibromatosis type 2
WHO: World Health Organization

*University of California San Diego and Rady Children's Hospital, San Diego, CA.

astrocytoma and glioblastoma multiforme represent the malignant variants (WHO grades III and IV).

Although there is no histologic distinction between adult and pediatric gliomas, there are striking differences in their epidemiology. Glioblastoma multiforme represents the most common glioma of adulthood (3.19 per 100,000 person-years), whereas juvenile pilocytic astrocytoma is the most common glioma of childhood (0.8 per 100,000 person-years). (1)

Three commonly encountered neurogenetic syndromes diagnosed in childhood (neurofibromatosis type 1 [NF-1], neurofibromatosis type 2 [NF-2], and tuberous sclerosis) have a predisposition for low-grade glioma formation based on their respective genetic mutations. In the case of NF-1, children may develop low-grade gliomas of the optic pathway, cerebrum, cerebellum, and spinal cord. Children who have NF-2 are also at risk for glioma formation but more commonly develop meningiomas, ependymomas, and acoustic schwannomas. Children who have tuberous sclerosis may develop subependymal giant cell astrocytomas (WHO grade I) that can obstruct the foramen of Monro, leading to obstructive hydrocephalus.

Aside from a few genetic syndromes with a predisposition for developing CNS tumors (ie, NF-1, NF-2, tuberous sclerosis, Li-Fraumeni syndrome, Gardner syndrome, Turcot syndrome, Gorlin syndrome), brain tumor pathogenesis is largely unknown. Brain tumor genesis is most likely a consequence of inherited, acquired, and epigenetic phenomena.

In general, patient characteristics such as age and gender are not associated with a predisposition to a brain tumor, with a few exceptions. For instance, CNS germ cell tumors occur more commonly in boys (twofold), and pituitary tumors are more common in girls (threefold). Although environmental and other epigenetic causes are under intense investigation, there is no proven cause of childhood brain tumors aside from the known associated genetic syndromes mentioned earlier.

Tumors of young children (age 0–4 years) most commonly are of embryonal origin and often are located in the posterior fossa. The differential diagnosis of posterior fossa tumors in this age group, listed by decreasing frequency, include medulloblastoma, juvenile pilocytic astrocytoma, ependymoma, and atypical teratoid rhabdoid tumor. In older children, juvenile pilocytic astrocytoma is the most common posterior fossa tumor, followed by medulloblastoma.

Across all ages, medulloblastoma (WHO grade IV) is the most common malignant brain tumor of childhood (0.51 per 100,000 person-years) and the most common primary brain tumor in children age 0 to 4 years.

Medulloblastoma is derived from tumor stem cells of the external granular layer of the cerebellum and can be categorized according to distinct histologic variants (classic, nodular desmoplastic, and anaplastic large-cell). Recent studies have divided medulloblastoma into distinct molecular subgroups that can potentially be used to predict survival and provide risk-adapted therapies. (4)(5)

A histopathologic and neuroradiographic mimicker of medulloblastoma, the atypical teratoid rhabdoid tumor is a highly malignant tumor related to the rhabdoid tumor of the kidney that most often occurs in children age younger than 2 years. (6) Atypical teratoid rhabdoid tumor is categorized molecularly by a mutation/deletion of the hSNF5/INI-1 gene on chromosome 22q11.2 and can occur outside of the CNS in the kidney and soft tissues. Atypical teratoid rhabdoid tumors can occur in both infratentorial and supratentorial locations. The diagnosis is confirmed by an immunohistochemical lack of INI-1 protein expression that distinguishes it from the histologically similar medulloblastoma. The distinction between medulloblastoma and atypical teratoid tumor is critically important because atypical teratoid rhabdoid tumors can be more aggressive, may have poorer survival rates, and may require more aggressive therapy than classic medulloblastomas.

Ependymomas are the second most common embryonal tumor of childhood (0.29 per 100,000 person-years) and are derived from ependymal cells within the CNS. Ependymoma can be of varying grades (WHO grades I and III) and locations. They are found more commonly in the posterior fossa; however, these tumors also can occur in the supratentorial region and in the spinal cord.

With more than 30 histopathologic classifications of primary pediatric brain tumors, establishing a diagnosis can be challenging even for the most experienced pediatric neuropathologist. The current WHO classification system is helpful with regard to establishing a uniform guideline for brain tumor classification and grading, but it is by no means complete. Advances in molecular genetics have improved our ability to classify brain tumors based on biologic markers but likely will not replace our current histopathologic classification for many years. Unfortunately, not all brain tumors are “created equal,” making diagnostic and management strategies nonuniform and highly individualized at times.

The morbidity and mortality associated with childhood brain tumors are multifactorial and depend not only on tumor pathology but also on location and treatment. Figure 1 lists some of the more common pediatric brain tumors according to neuroanatomic location. This list is far from exhaustive and is meant to demonstrate the diversity of tumor types based on location. It is also meant

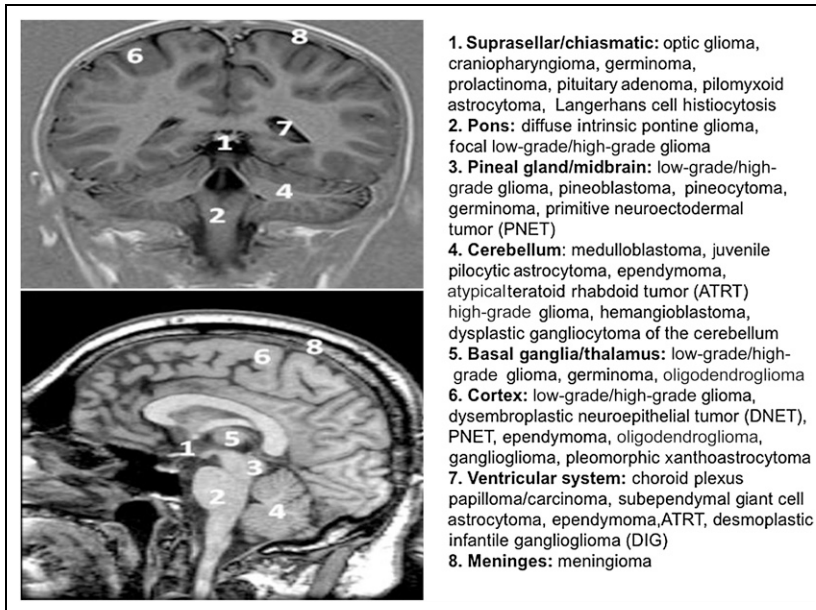


Figure 1. Common pediatric brain tumor subtypes according to anatomic location.

to provide the primary care physician with a general differential diagnosis in children suspected of having a brain tumor in the context of abnormal results on neurologic examination.

Signs and Symptoms

The presenting signs and symptoms of pediatric brain tumors can be incredibly diverse and elusive to the patient, parent, and clinician alike. In general, symptoms arise from the neuroanatomic pathways that are disrupted by the tumor, as illustrated in Fig 2. The most common symptom reported by children with a newly diagnosed brain tumor is headache. Headache occurs in approximately one third of pediatric patients newly diagnosed as having brain tumors. (7) Headache in the absence of other symptoms associated with normal neurologic findings does not have reliable positive predictive value in the diagnosis of a brain tumor. Therefore, the presence of headache alone should not be a “red flag” for this diagnosis.

Nausea and vomiting may occur in approximately one third of children newly diagnosed as having a brain tumor. (7) However, children who have systemic illnesses such as gastroenteritis, viral meningitis, and childhood migraine all can present with similar symptoms, and these are far more common illnesses than brain tumors.

Children will often present with the triad of headache, nausea or vomiting, and gait imbalance that develops over weeks to months. This triad, with progression of signs

and symptoms, should alert the clinician to the likelihood of cerebrospinal fluid (CSF) obstruction secondary to a brain tumor. In 15% of children newly diagnosed as having a brain tumor, papilledema also may be present.

The triad of headache, nausea or vomiting, and gait imbalance is the most common presentation of posterior fossa tumors and is usually accompanied by early morning vomiting as the defining feature. The pathophysiology of early morning vomiting is related to nocturnal hypoventilation, hypercarbia, vasodilation of cerebral vessels, increased cerebral blood volume, and increased CSF production, all during recumbent sleep. Posterior fossa tumors also may present with head tilt and torticollis, particularly when there is invasion of the foramen of Luschka.

One of the most difficult presenting signs of pediatric brain tumors to detect clinically is a visual field deficit. These defects can be associated with a variety of suprasellar and optic pathway tumors, including craniopharyngioma, optic glioma, and low-grade glioma, to name a few. Often, the visual field deficits in children are subacute or chronic and are not readily noticed by the child or caregiver, regardless of age, until progression to extreme papilledema and subsequent optic nerve pallor or infarction develops.

Similar to visual field deficits, signs and symptoms related to endocrine dysfunction may be present several months before a diagnosis of a brain tumor is made. The more common signs of endocrine dysfunction associated with brain tumors include precocious or delayed puberty, anorexia, and excessive urination. These symptoms localize to a tumor in the region of the hypothalamic-pituitary axis and include pituitary adenomas, germinomas, and low-grade gliomas.

The presence of a new-onset seizure, particularly of focal onset, may be seen in up to 40% of children diagnosed with cortical-based tumors. (7) Although seizures are a common presenting feature of brain tumors, the vast majority of seizures are due to other systemic or genetic influences. Overall, a new childhood brain tumor is associated with less than 4% of all new-onset seizure presentations.

Occasionally, patients may present with tics, tremors, movement disorders, or learning disabilities that can be confused with other postinfectious, demyelinating, or neurodegenerative diseases. CNS germinomas or low-grade

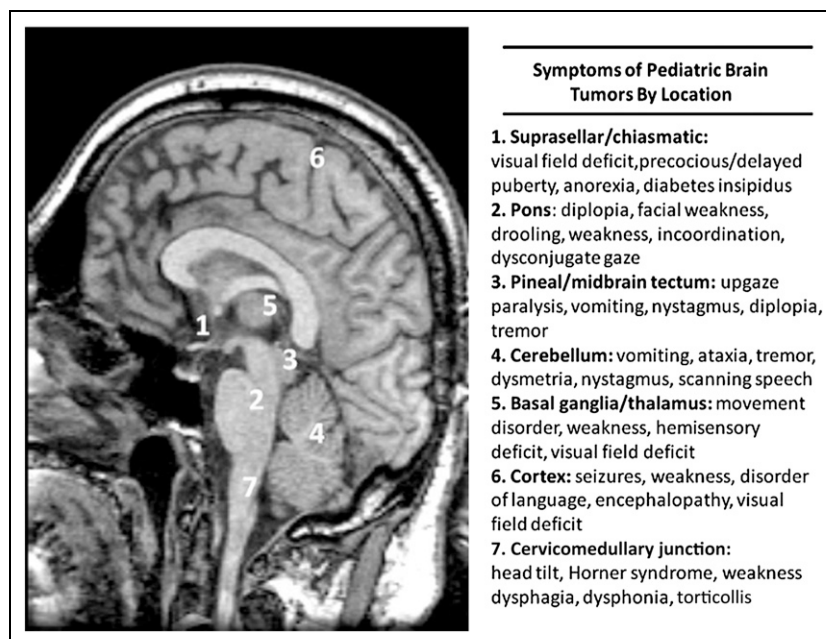


Figure 2. Common symptoms of pediatric brain tumors according to anatomic location.

gliomas of the basal ganglia, midbrain, or deep white matter in particular are associated with atypical symptoms.

Young children who have brain tumors often are the most challenging patients to diagnose. These children will present with macrocephaly (40%), vomiting (30%), irritability (25%), and lethargy (20%). (7) Macrocephaly usually is detected on routine health visit screenings and must be distinguished from other familial, traumatic, and neurogenetic causes. Two signs that can be overlooked in young children are failure to thrive and early handedness. In the case of failure to thrive, children may have a prolonged history of poor weight gain without an identifiable cause, and despite an exhaustive gastrointestinal evaluation, eventually neuroimaging reveals a midline tumor. In cases of diencephalic syndrome (a constellation of severe emaciation, normal or precocious intellectual development, and normal linear growth), a hypothalamic/chiasmatic tumor is present on neuroimaging that is almost always a low-grade glioma (with or without hydrocephalus). Remarkably, after treatment with surgery or chemotherapy, there is marked improvement in weight gain that correlates with tumor shrinkage. Early or changing handedness can be a sign of upper motor neuron injury and may be seen with both cortical-based and spinal cord tumors. A list of some of the more common warning signs in the presentation of childhood brain tumors that may warrant neuroimaging is shown in Table 1.

Neurologic Examination

A thorough neurologic examination is of paramount significance in the assessment of a child suspected of having a brain tumor. The majority of children diagnosed as having a brain tumor have abnormal findings on neurologic examination at presentation. (7) In a busy pediatric practice, a focused history and neurologic examination based on symptoms can be adequate to raise suspicion of a brain tumor. The key components of the neurologic examination include evaluation of mental status, cranial nerves, motor skills, sensation, reflexes, coordination, and gait (Table 2).

In terms of mental status, an increased degree of encephalopathy will most likely prompt emergent neuroimaging. However, in patients who have chronic hydrocephalus secondary to a midbrain tectum low-grade glioma, a history of slow but steady decline in school performance may be the only warning sign.

Examining extraocular movements can be a sensitive component of brain tumor detection, particularly in cases of midbrain, pineal, cerebellar, and brainstem tumors. Parinaud syndrome, a constellation of findings that include paralysis of upgaze, pupils that are mid-dilated and poorly reactive to direct light, convergence or retraction nystagmus, and eyelid retraction, is commonly seen with dorsal midbrain tumors. Children who have cerebellar tumors, especially with involvement of the flocculonodular lobe, will present with nystagmus in any direction. Limited upgaze or upgaze nystagmus is always pathologic and should prompt further evaluation.

Another syndrome presenting with abnormal eye movements worth mentioning in the context of pediatric neuro-oncology is opsoclonus myoclonus syndrome. This syndrome represents a paraneoplastic phenomenon characterized by involuntary conjugate eye movements of large amplitude and myoclonic jerks; it is usually associated with an extra-CNS neuroblastoma. These children can present with a cerebellar syndrome (eg, fast oscillating nystagmus, tremor, ataxia, dysmetria, irritability) in the absence of neuroimaging findings that may mimic a postinfectious syndrome.

As mentioned, visual field abnormalities are common in tumors involving the optic pathway (eg, nerves, chiasm,

Table 1. Signs and Symptoms Associated With Delayed Diagnosis of Childhood Brain Tumors

Signs and Symptoms	Tumor Location
Early morning vomiting, recurrent vomiting, enlarging head	Posterior fossa, ventricular system
Failure to thrive, anorexia	Suprasellar, hypothalamic
Visual complaints, abnormal eye movements	Optic pathway, suprasellar, brain stem, posterior fossa
Tics, tremor, movement disorder	Basal ganglia, thalamus, midbrain
Early handedness	Cortex, subcortical, brain stem, spinal cord
Facial nerve palsy	Brain stem, cerebellar pontine angle
Hearing loss	Cerebellar pontine angle
Precocious puberty, nocturnal enuresis	Suprasellar
Head tilt, torticollis	Cerebellar pontine angle, cervicomedullary junction

tracts, thalamus, radiation, visual cortex) and, if not tested for, can be missed. (8) The easiest way to assess visual fields in young patients is to use two colorful objects. While maintaining central fixation with one object, the second object should be placed in each of the four quadrants while monitoring for tracking. In older, more cooperative patients, it is necessary that each eye be tested individually while maintaining central fixation to test accurately for visual fields.

A fundoscopic examination is crucial not only in assessing for papilledema but also in detecting disc pallor, commonly seen in tumors involving the optic nerve and chiasm and indicative of optic nerve damage. Both the conventional and panoptic ophthalmoscope may be used to perform the fundoscopic examination. The panoptic ophthalmoscope allows for visualization of the entire disc and generally is regarded as more user-friendly than the conventional ophthalmoscope. Regardless of the equipment used, in an uncooperative or young child, a formal dilated examination performed by an ophthalmologist may be required to obtain accurate results.

Patients afflicted with brainstem tumors can present with a multitude of cranial neuropathies. Facial nerve palsy is a common presentation of most brainstem tumors involving the pons. Often confused with having Bell's palsy, these patients may have other cranial neuropathies (eg, esotropia, decreased hearing, drooling, dysphagia) specifically involving abducens, vestibulocochlear, glossopharyngeal, vagus, and hypoglossal nerves in isolation or in various combinations. Any patient presenting with new-onset facial palsy should have a thorough neurologic examination to exclude other

cranial neuropathies that would raise suspicion for a brainstem tumor and prompt immediate neuroimaging.

In terms of motor testing, the most important procedure is to assess for possible asymmetries in bulk, tone, and strength. Children who have longstanding upper motor neuron injury secondary to a low-grade cortical, subcortical, or brainstem tumor involving the cortical spinal tracts will have increased tone as well as hemiatrophy of the affected limb. These physical findings can provide useful clinical insight with regard to tumor grade and biologic behavior, because hemiatrophy and hypertonias represent longstanding upper motor

neuron injury and correlate with low-grade tumor pathology. In young children, in whom individual muscle groups are difficult to test, one can look for hand preference when grasping for objects. In older children, the presence of a pronator drift when the arms are extended in supination with the hands open is a sensitive test for extremity weakness.

Asymmetries in sensation (cold, light touch, and pinprick) can be clues to cortical tumors, spinal cord tumors, and, in the case of facial sensation, dysfunction of the divisions of the trigeminal nerve located throughout the brain stem.

Evaluation of reflexes can be very helpful, especially if there are asymmetries. The upper extremity reflexes (biceps, triceps, and brachioradialis) generally are more difficult to obtain in young children; however, asymmetries are pathologic and can be clues to tumor location. In the lower extremities, asymmetries in the patellar and Achilles reflexes are generally associated with a Babinski response, indicative of upper motor neuron dysfunction.

Coordination testing is extremely important in children who have suspected cerebellar and brainstem tumors. The classic finger-to-nose testing must be performed to assess for cerebellar dysmetria. It is critical for the child to extend the extremity fully and reach for the examiner's finger. Cerebellar testing can be done in both the arms and the legs. Alternatively, the patient may hold out a finger and mirror the examiner's finger movements in the extended position. This mirror testing is extremely sensitive in assessing cerebellar dysfunction, and in the case of patients who have cerebellar tumors, will result in an "overshoot" of the movement. A rather quick and sensitive screening test that can be

Table 2. Key Components of the Neurologic Examination in a Child Who Has a Suspected CNS Tumor

Examination	Pertinent Findings Suggestive of a Tumor
Mental status (level of alertness, speech and language)	Encephalopathy, progressive neurocognitive decline
Cranial nerve 2 (visual fields, fundoscopic examination)	Visual field deficit, papilledema
Cranial nerves 3, 4, 6 (extraocular movements, efferent pupillary function)	Nystagmus (upgaze in particular), gaze paralysis in any direction, mid-position, poorly reactive pupils
Cranial nerve 7 (facial symmetry)	Facial weakness (upper versus lower motor neuron distribution)
Cranial nerve 8 (hearing, balance)	Decreased hearing to finger rub (unilateral or bilateral), vertigo
Cranial nerves 9, 10, 12 (palate elevation, swallowing, tongue movements)	Drooling, dysphagia
Motor examination (bulk, tone, proximal and distal strength)	Early handedness, delayed motor milestones, pronator drift, focal changes in tone with associated atrophy
Reflexes (biceps, triceps, brachioradialis, patellar, Achilles)	Hyperreflexia with Babinski sign
Cerebellar function (finger to nose testing, mirror testing, rapid finger and toe tapping)	Dysmetria, overshoot on mirror testing, marked asymmetry of finger and/or toe tapping (must be differentiated from weakness)
Gait (heel, toe, tandem straight line)	Wide-based unsteady gait, inability to perform straight-line test, circumduction of gait
Sensory examination	Sensory deficits in a focal anatomic distribution

performed easily is to have the child rapidly tap his fingers against his thumbs and his feet on the floor. Asymmetries of these fine motor movements may be indicative of cerebellar dysfunction, focal motor weakness, or both.

Gait assessment is an important part of the neurologic examination and can be accomplished solely by observation. Patients who have cerebellar tumors, particularly those involving the midline cerebellum, will exhibit a classic wide-based ataxic gait, as well as an inability to perform tandem straight-line walking. Children who have cortical spinal tract involvement will exhibit a hemiparetic gait, with circumduction of the leg and asymmetries in the swing phase of the arms. In all cases of gait disturbance, it is important to consider spinal cord tumors in the differential diagnosis.

Finally, it is always prudent to perform a thorough skin examination, looking for neurocutaneous stigmata of disease. In particular, the presence of café au lait macules and axillary freckling should raise suspicion for neurofibromatosis and trigger fundoscopic examination and assessment for visual deficits (NF-1) and hearing deficits (NF-2). Patients who have ash leaf spots, shagreen patches, and facial angiomatosis should undergo head circumference measurement and a fundoscopic examination. In children who have known or suspected tuberous sclerosis who present with headache, vomiting, or irritability, the diagnosis of obstructive hydrocephalus secondary to a subependymal giant cell astrocytoma should be considered.

Neuroimaging Features of Childhood Brain Tumors

Any child who has an abnormal result on neurologic examination in the setting of the aforementioned symptoms should have neuroimaging to rule out a brain tumor. The choice of neuroimaging depends on the urgency of the symptoms and the degree of neurologic abnormality. Children who manifest altered mental status, behavioral changes, or cognitive decline associated with headache, nausea, vomiting, and ataxia in the absence of infection should be referred to the emergency department. In these situations, a noncontrast computed tomography (CT) scan of the head generally is performed based on availability and urgency.

It is important to note that some tumors, particularly tumors of the brainstem, cerebellum, and suprasellar region as well as infiltrative tumors of the white matter, can be missed on CT neuroimaging. Figure 3 shows examples of the CT appearances of various pediatric brain tumors with their associated signs and symptoms. CT neuroimaging is sensitive in detecting both blood and calcification and continues to have a role in the ongoing management of pediatric brain tumors, often because there may be no sedation requirement because the length of time for the procedure is short. Both coronal and sagittal reformatting of CT sequences are available at most centers and can provide additional anatomic information.

A CT scan with contrast is rarely necessary in the emergency setting of a patient suspected of having a brain tumor unless an infectious cause (eg, cerebral abscess) is in the differential diagnosis. Despite the utility of a CT scan in the emergency setting, magnetic resonance imaging (MRI) is the standard of care for all children who have a known or suspected brain tumor. MRI is the most sensitive neuroimaging modality for detecting a brain tumor, with and without intravenous gadolinium contrast. Although not every CNS tumor shows enhancement, the gadolinium is particularly helpful in detecting those patients who have disseminated leptomeningeal metastatic disease at presentation. Therefore, all children who have newly discovered brain tumors on neuroimaging should routinely have an MRI with contrast of the entire spinal axis. Occasionally, abnormalities will be encountered on an MRI that could be consistent with other disorders, such as demyelinating or postinfectious diseases, which may involve the deep white matter, basal ganglia, or thalamus. Under these circumstances, additional MRI sequences,

such as MRI perfusion and spectroscopy, can be used to differentiate tumor from mimickers. Although not used routinely in every case, it is hoped that additional MRI sequences can be used reliably to distinguish a tumor from radiation necrosis and help to predict responses to radiation, chemotherapy, or biologic therapy.

Although the MRI is an extremely valuable tool in the practice of neuro-oncology, it has its limitations. For example, in patients who have orthodontic braces, there is often magnetic susceptibility artifact that can limit the interpretation of suprasellar tumors in particular. In small children, sedation is required to obtain an adequate study because motion artifact is common in this age group.

MRIs have been notoriously ineffective at detecting blood and mineralization; however, this limitation is circumvented with newer sequences, including susceptibility weighted imaging. The most significant limitation of MRI is its inability to render a pathologic diagnosis. Although there are specific neuroimaging features of the various pediatric brain tumor subtypes, there is tremendous

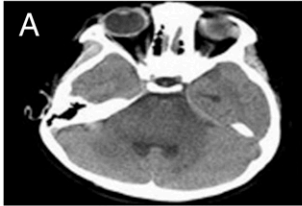
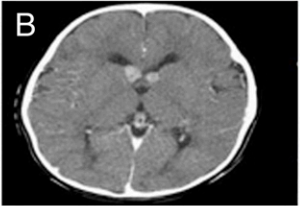

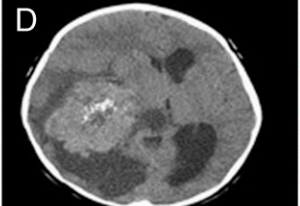
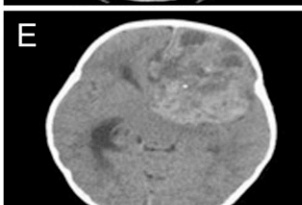
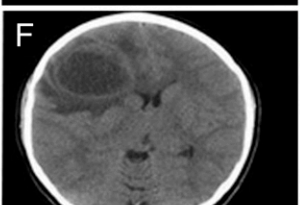
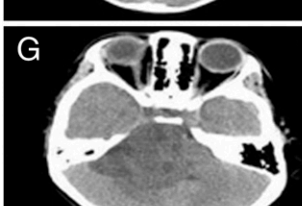
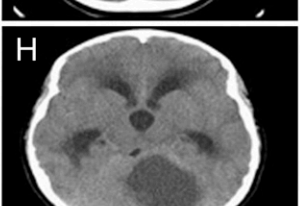
	Signs and Symptoms	Diagnosis
	Facial weakness, double vision, ataxia	Diffuse intrinsic pontine glioma
	Vomiting, hypopigmented macules	Subependymal giant cell astrocytoma, tuberous sclerosis
	Impaired upgaze, nystagmus, vomiting	CNS germinoma
	Altered mental status, vomiting, left-sided weakness	Choroid plexus carcinoma
	Headaches, vomiting, right-sided weakness	Atypical teratoid rhabdoid tumor
	Headaches, left focal seizures	Glioblastoma multiforme
	Facial weakness, hearing loss, ataxia,	Ependymoma
	Early morning vomiting, headaches, double vision	Juvenile pilocytic astrocytoma

Figure 3. Computerized tomography neuroimaging findings and associated symptoms of childhood brain tumors.

overlap, and therefore a specific diagnosis cannot be achieved based on MRI appearance alone.

With the exception of the CNS germinoma, which can display elevations of serum and CSF markers (α -fetoprotein and β -human chorionic gonadotropin), the final diagnosis of a brain tumor is made by histologic examination after biopsy or resection.

Examples of MRI neuroimaging features of pediatric brain tumors with associated symptoms are shown in Fig 4.

Acute Management of the Newly Diagnosed Patient

The management of the child newly diagnosed as having a brain tumor usually begins in the emergency department after neuroimaging. In general, the management of neuro-oncology patients is no different from that of patients who have other acute neurologic emergencies. Establishing an airway, sufficient breathing, and effective circulation remain the most crucial immediate priorities.

In cases of acute obstructive hydrocephalus with herniation syndrome, emergent neurosurgical consultation for either surgical resection or emergent temporizing ventricular decompression is required. Preoperative laboratory testing should include a complete blood cell count, coagulation studies, and blood type and cross-matching. In the case of suprasellar tumors, it is extremely helpful to obtain baseline electrolytes and endocrine studies before surgery, because patients who have large suprasellar tumors often have multiple endocrinopathies of both anterior and posterior pituitary function.

A baseline ophthalmologic evaluation, including visual field testing and fundoscopic evaluation, is important in preoperative evaluations because most patients do not complain of visual field deficits at presentation. Depending on the degree of vasogenic edema, intravenous corticosteroids with a gastrointestinal-protective agent are given conventionally before and after surgery. Although there is little evidence to support the use of corticosteroids with regard to overall outcome, corticosteroids can relieve headache, nausea, and vomiting and remain a generally accepted treatment.

If the diagnosis is based on CT imaging alone, a preoperative MRI of the brain and spine (with and without gadolinium) is necessary for surgical planning and staging. A general schematic of acute management strategies in patients newly diagnosed with a brain tumor is listed in Table 3.

Equally important in the management of newly diagnosed patients is providing psychosocial support during the initial confirmation of the diagnosis. It is beyond

the scope of the primary care physician or emergency department team to discuss tumor histology, treatment strategies, and outcomes. However, it is important to keep the patients (when appropriate) and parents informed of the diagnostic process. This task generally is performed best in a conference room setting, where neuroimages can be reviewed with the family and the neurosurgical/neuro-oncology team may be introduced.

It is common for parents to have extraordinary guilt when a brain tumor is diagnosed. It must be emphasized that brain tumors occur in children of all ages, races, and geographic locations, and there is no single cause for developing a brain tumor, a disorder that cannot be prevented.

Parents and clinicians often are plagued with guilt by delayed diagnosis due to unusual or vague symptoms. There has been no study to date that has correlated early detection of pediatric brain tumors with changes in overall or event-free survival. Children generally present for medical attention when their neurologic symptoms impede their ability to play.

Social workers, child life specialists, and neuropsychologists provide critical support to families and patients during diagnosis and throughout the course of care. Once a pathologic diagnosis is firmly established, a multidisciplinary conference is required to review the diagnosis, treatment plan, and prognosis.

Therapeutic Strategies and Outcomes

Neurosurgery generally is the first and most important intervention for children newly diagnosed as having a brain tumor. The ultimate goal of surgery is to obtain a complete resection without postoperative complications. Sometimes a complete resection is not feasible due to tumor location, in which case a subtotal resection or biopsy is performed. In children who have posterior fossa tumors (eg, medulloblastoma, juvenile pilocytic astrocytoma, ependymoma), a gross total resection correlates with improved event-free and overall survival.

However, the posterior fossa is a potentially dangerous location and prone to postoperative complications. Posterior fossa mutism syndrome, a constellation of mutism, hypotonia, and irritability, can occur in the immediate postoperative period and is presumed to be due to midline cerebellum connection disruption. Posterior fossa mutism can be partially or completely reversible over weeks to months and has been reported with varying degrees of severity in up to 10% to 20% of children who undergo posterior fossa surgery.

In children who have cortical-based tumors (eg, low-grade astrocytoma, ependymoma, oligodendroglioma,

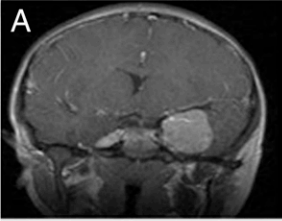
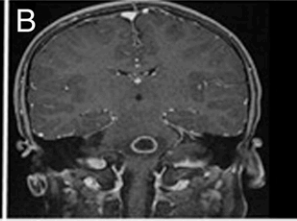
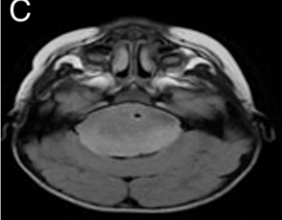
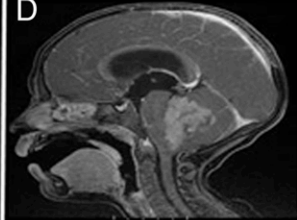
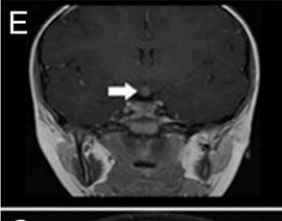


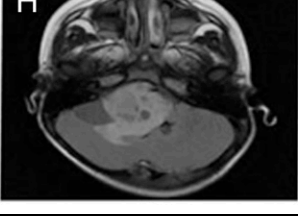
	Signs and Symptoms	Diagnosis
	Headache, seizures, hyperpigmented macules	Meningioma, neurofibromatosis 2
	Vomiting, facial weakness, ataxia, double vision	Glioblastoma multiforme
	Nystagmus, facial weakness, ataxia, dysphagia	Diffuse intrinsic pontine glioma
	Recurrent vomiting	Medulloblastoma
	Nocturnal enuresis	CNS germinoma
	Failure to thrive, visual abnormalities	Suprasellar juvenile pilocytic astrocytoma
	Visual loss, hyperpigmented macules	Optic glioma, neurofibromatosis type 1
	Facial weakness, ataxia, early morning vomiting	Ependymoma

Figure 4. Magnetic resonance imaging findings and associated symptoms of childhood brain tumors. CNS=central nervous system.

mixed glioneuronal tumors), the goal is to achieve gross total resection. In those patients who have high-grade tumors of any location, maximum tumor resection and adjuvant therapy are required, based on the high rate of recurrence and dissemination. In children who have deep-seated tumors (ie, thalamic, basal ganglia, pineal-tectal tumors), a biopsy often is sufficient to achieve a diagnosis, and tumor debulking is performed in cases in which there is significant mass effect.

In the case of CNS germinoma, a diagnosis can be made on the basis of elevation of serum or CSF tumor markers (α -fetoprotein and β -human chorionic gonadotropin) alone. A biopsy, although generally favored, is not always required to establish a diagnosis of CNS germinoma. A gross total resection in children who have extensive craniopharyngiomas can be curative; however, gross total resection is often associated with resulting visual field deficits and multiple endocrinopathies.

Children diagnosed with tectal or pineal tumors often undergo a biopsy approach, given the potential risk of surgical morbidity, and frequently also receive a CSF diversion procedure (ventricular peritoneal shunt versus endoscopic third ventriculostomy) in cases of obstructive hydrocephalus. The decision to place a shunt in a child who has a malignant brain tumor with associated hydrocephalus sometimes is based on medical necessity, but the procedure carries a 5% to 7% risk of extraneural seeding. Those who have large posterior fossa tumors frequently require a CSF diversion procedure because prolonged CSF obstruction is associated with papilledema and potential optic nerve infarction.

Despite the precarious location of the tumor, children who have brainstem tumors can undergo safe resection to achieve cure in cases of dorsal exophytic cervicomedullary tumors. Patients who have diffuse intrinsic pontine glioma, the most malignant of childhood brain tumors, generally do not undergo biopsy unless enrolled in

Table 3. General Management Strategy of Newly Diagnosed Pediatric Brain Tumors

Airway, breathing, circulation stabilization
 Neurosurgery/neuro-oncology consultation
 NPO
 Presurgical laboratory tests (electrolytes, CBC, coagulation studies, blood type and cross-matching)
 Intravenous steroids (dexamethasone) with GI-protective agent
 Magnetic resonance imaging of the brain and spine with and without intravenous contrast
 Preoperative endocrine laboratory tests for suprasellar tumors
 Ophthalmologic examination
 Seizure prophylaxis for patients presenting with or at high risk for convulsions
 Social work consultation

Lumbar puncture for CSF cytology and tumor markers (for suspected CNS germinoma) is generally performed 7 to 10 days postoperatively if there are no contraindications.

CBC=complete blood cell count, CNS=central nervous system, CSF=cerebrospinal fluid, GI=gastrointestinal, NPO=nothing by mouth.

a clinical trial, because the diagnosis can be made by the appearance of a characteristic expansile mass centered in the pons with minimal or no contrast enhancement on MRI. Occasionally, a biopsy is warranted in these cases, especially when there are focal, well-defined enhancing lesions, to exclude infectious or demyelinating mimickers of brainstem gliomas.

An additional tumor, optic nerve glioma, can be diagnosed on the basis of neuroradiographic features alone. These tumors often are low-grade gliomas associated with NF-1 and are seen easily on dedicated MRI sequences of the optic nerves. Very rarely, meningiomas and metastatic disease can present with optic nerve pathology. Children diagnosed as having optic nerve gliomas (with or without neurofibromatosis) are treated conservatively with observation but undergo chemotherapy if they demonstrate visual dysfunction or tumor progression. In summary, the outcome for children who have brain tumors is very much dependent on skilled neurosurgical management to achieve a gross total resection whenever feasible, and such management remains the ultimate goal for successful treatment.

Once neurosurgical intervention and sufficient healing of surgical wounds are achieved, additional treatments may be required, including chemotherapy, radiation therapy, or a combination of both. These adjunct therapies are chosen based on the pathologic diagnosis and amount of residual tumor. The nonsurgical management of childhood brain tumors is complex and depends on the age of

the patient, pathologic diagnosis, degree of residual tumor, presence or absence of dissemination, and availability of clinical trials. If the reader is interested in the management of a specific tumor type, there are numerous textbooks, published clinical trials, and review articles that outline the evidence-based management strategies and controversies of specific pediatric tumor subtypes.

For tumors of low-grade histologic type in which gross total resection is achieved, no further treatment is necessary. Children who have residual low-grade tumors generally are observed for progression. If they demonstrate growth on surveillance neuroimaging (every 4–6 months), they are treated with further surgery, chemotherapy, or radiation therapy, depending on age, tumor location,

degree of recurrence, and symptoms. Children who have malignant gliomas require radiation therapy postoperatively, in combination with the experimental biologic agents (eg, molecular-based targeted therapy) or oral chemotherapy agents such as temozolomide. The most prominent role of chemotherapy is in children who have embryonal tumors or CNS germinomas and in younger children who have progressive low-grade gliomas.

Based on strong research evidence, (1) it has been shown that a combination of chemotherapy involving either a two-drug regimen (carboplatin and vincristine) or a four-drug regimen (procarbazine, thioguanine, lomustine, and vincristine) can improve event-free survival in children diagnosed with progressive low-grade glioma. (9)

In children who have embryonal tumors (medulloblastoma, ependymoma, or atypical teratoid rhabdoid tumors), chemotherapy is often used in conjunction with either focal or craniospinal radiation, depending on the age, degree of dissemination, and tumor pathology. In children who have average-risk medulloblastoma (age >3 years, <1.5-cm² residual disease, nondisseminated disease, and nonanaplastic histology), a combination of craniospinal radiation with adjuvant chemotherapy followed by maintenance chemotherapy is used. Chemotherapy can be used either at standard doses or at higher doses to achieve greater CNS penetration that would require autologous stem cell support secondary to myeloablative chemotherapy. Current trials are underway to investigate the utility of a reduced dose of craniospinal radiation to

prevent long-term sequelae of radiation therapy without compromising survival.

Patients who have high-risk medulloblastomas require high-dose craniospinal radiation of 3,600 cGy with a posterior fossa boost, whereas patients who have average-risk medulloblastomas require either 1,800 or 2,340 cGy of craniospinal radiation with a similar posterior fossa boost. Current management strategies of children who have average-risk medulloblastomas have led to improvements of 5-year event-free survival that approach 85% in multiple international studies. Patients who have high-risk medulloblastomas, unfortunately, have much lower survival rates (40%–65%) and are the focus of intense investigation.

The results of adjuvant chemotherapy in patients who have posterior fossa ependymoma are less convincing than for medulloblastoma. Children can achieve durable responses to postoperative radiation alone. Previous studies in young children who delayed or avoided radiation demonstrated recurrence of ependymoma in up to two thirds of children treated with chemotherapy alone. Phase III clinical trials are being conducted to determine whether a combination of focal radiation and chemotherapy will have synergistic effects.

Children younger than 3 years provide additional challenges for the clinician, regardless of the tumor histology. The long-term effects of craniospinal and possibly even focal radiation have led to various management strategies to avoid or delay radiation therapy. In children who have embryonal tumors, higher doses of chemotherapy to achieve greater CNS penetrability have been used to delay or avoid radiation in a subset of children who have embryonal tumors. However, high-dose chemotherapy regimens are myeloablative, require autologous stem cell rescue during therapy, and have been associated with treatment-related morbidity and mortality in a small percentage of patients. One management strategy currently under investigation is to treat young children who have posterior fossa embryonal tumors with adjuvant methotrexate-based chemotherapy followed by involved-field-only radiation therapy, with the option of using craniospinal therapy for progressive disease.

Children who have CNS germinomas can be cured by using a combination of chemotherapy and involved-field lower dose radiation that involves the ventricular system, attaining cure rates of greater than 90%. The malignant counterpart of a CNS germinoma, the nongerminomatous germ cell tumor (embryonal, immature teratoma, choriocarcinoma, and mixed germ cell tumor), requires a combination of chemotherapy and craniospinal radiation and is associated with approximately 20% lower 5-year overall survival.

Children diagnosed with diffuse intrinsic pontine glioma have the worst survival rate, with greater than 90% mortality by 2 years despite radiation therapy and use of investigational agents. A variety of radiosensitizing biologic and chemotherapeutic agents have been used alone and in various combinations without improvement in survival. It is important to realize that not every brainstem tumor carries this dismal prognosis. Children who have exophytic brainstem tumors can be cured with surgery or radiation therapy. Children who have focal brainstem tumors can become long-term survivors and presumptively have tumors with low-grade pathologic characteristics. Children who have high-grade gliomas in general have similar poor survival rates as the adult patients and are the focus of numerous clinical trials.

Because cranial and craniospinal radiation is commonly used in both initial treatment regimens and salvage therapy at relapse, clinicians should be aware of the two major types of radiation treatments: photon and proton beam radiation. Both photon and proton beam irradiation use high-energy irradiation to create free radicals that deliver preferential damage to tumor DNA because tumor cells do not have competent enzymatic repair capabilities. Both modalities use frameless stereotactic navigation to provide three-dimensional conformal intensity-modulated radiation, in which radiation beams are formed to match the tumor shape. During intensity-modulated radiation therapy, the intensity of radiation is changed during treatment to spare normal surrounding tissues.

The concern for photon beam radiation is that there can be damage to normal surrounding tissue due to the intrinsic properties of the high-energy particle. This effect is important when targeting sensitive areas such as the cochlea, temporal lobes, and, in the case of spinal irradiation, the abdominal cavity.

Because of the physical nature of the proton, the radiation dosage deposited inadvertently in normal tissues (termed the exit dose) is less and therefore may spare vital organs. Children who have suprasellar and malignant posterior fossa tumors theoretically are good candidates for proton beam therapy from a neurocognitive standpoint. (10) Only a small number of proton beam centers exist in the United States, however, and therefore not every child can be treated with proton beam irradiation. Ongoing studies are being performed to determine whether there are any benefits of proton beam therapy with regard to survival or incidence of late effects, but these studies will not be completed for many years.

Management of Progressive or Recurrent Disease

The management of progressive brain tumor disease poses significant challenges, and pediatricians should be aware of the issues that patients and families face. Despite combined surgery, chemotherapy, and radiation treatments, a significant proportion of children will have progressive or recurrent disease. The risk of disease recurrence is dependent on the patient's age, tumor pathology, extent of resection, and previous treatment. In children who experience local relapse, surgery generally is offered, depending on the anatomic site of relapse. If patients have not received radiation therapy to the affected area, radiation generally is offered. Even when a patient has received previous radiation, radiosurgery techniques (stereotactic, highly focused radiation) have been used to prolong survival.

Most commonly, as with other malignancies, children who experience progressive or recurrent disease are offered enrollment in clinical trials. Most clinical trials of treatments for recurrent childhood brain cancer involve Phase I studies, designed to test a new drug's safety and tolerability. The decision to enroll in a clinical trial is a personal one and involves myriad factors, including geography, tolerability and mode of delivery of the agents, and quality of life. All clinical trials in the United States and many international trials are registered on www.clinicaltrials.gov. These clinical trials can be researched by patients, families, and clinicians. Each trial consists of both inclusionary and exclusionary criteria that must be met before enrollment.

Neuro-oncology therapy is changing constantly, and new clinical trials are added weekly. In patients for whom clinical trials are not an option, combinations of biologic and chemotherapeutic regimens, with or without radiation, have been used, with varying degrees of success in delaying the progression of the disease.

Acute and Subacute Effects of Treatment

The primary care physician should understand the acute and long-term effects of brain tumor treatment. Patients may have acute treatment-related effects from surgery, radiation, and chemotherapy, depending on the tumor type and therapy received. In the case of surgery, patients can experience headaches after the surgical procedure. Headaches generally are relieved with anti-inflammatory medications; however, if fever is present, an abscess or infection due to CSF leak must be considered.

Children receiving chemotherapy might experience allergic reactions or acute neurologic complaints, such as foot drop or cranial neuropathies. Children who have

CNS tumors may experience seizures at any time during their treatment. Administering non-enzyme-inducing anticonvulsants (eg, levetiracetam) whenever possible is a requirement for many clinical trials involving investigational drugs.

Children undergoing cranial radiation may experience fatigue, nausea, or vomiting during their treatment. On occasion, stimulant and nonstimulant medications can be used to treat radiation somnolence. In the case of radiation or chemotherapy-related emesis, antiemetic medications or low-dose corticosteroids can be very helpful in controlling symptoms.

The neuro-oncology team manages the usual adverse effects of chemotherapy on the hematopoietic system (neutropenia, anemia, and thrombocytopenia); however, it is crucial that the primary care physician be aware of when the patient is undergoing treatment to recognize potential complications of therapy. In children who are receiving craniospinal radiation, complete blood cell counts are performed weekly because of the risk for anemia associated with marrow disruption due to radiation.

Late Effects of Treatment

Improved patient survival has presented a new era of late effects of tumor therapies that the primary care provider must be able to recognize. As with other pediatric malignancies, treatment with chemotherapy poses a potential risk for future hematogenous malignancies. In children who have received craniospinal radiation, subsequent thyroid cancers, skin cancers, meningiomas, and secondary high-grade gliomas all have been reported. (11) Under these circumstances, a compelling argument can be made for performing yearly MRI examinations in children who have undergone previous cranial radiation and are long-term survivors.

Children who have received any form of chemotherapy for the treatment for a brain tumor are at risk for both hematogenous and systemic secondary malignancies. High-frequency hearing loss is extremely prevalent in children who have received platinum-based chemotherapies, and such children must have routine audiometric evaluations. Other potential late effects of chemotherapy on organ function include disruption of cardiac, renal, pulmonary, and hepatic function. The effect of chemotherapy on fertility of both genders is the subject of current investigation.

Radiation therapy, despite its critical role in the management of pediatric brain tumors, has the highest number of long-term sequelae that the primary care physician should recognize. (12)(13)(14)(15) The most common, and perhaps most significant, effect of radiation therapy is its

impact on neurocognition. Children younger than 8 years are at the highest risk for radiation-related neurocognitive injury. Those patients who receive craniospinal radiation are at risk for declines in IQ of 2 to 4 points per year (10–20 points overall), depending on radiation dosage, tumor location, and age of the child. Subsequently, these children often have difficulty with learning and memory and may require special education services. Studies are ongoing to determine whether pharmacologic interventions have any impact on improving neurocognition in this population of children.

Endocrinopathies are commonly seen in patients who have received either whole brain or suprasellar boosts of radiation. Although the hypothalamic-pituitary axis hormones often are measured before, during, and after therapy, the long-term consequences of treatment-related endocrinopathies acquired during childhood are unknown.

Another important long-term neurologic complication specific to children who have received cranial radiation is neurovascular disease. Depending on the radiation dose and location, children are at increased risk for cerebral vasculopathy, including Moyamoya disease, which increases the risk for a future stroke. The mechanism of radiation-related vasculopathy is not entirely known but is different from the atherosclerotic or cardioembolic pathophysiology of stroke seen in adults. Unfortunately, pharmacologic intervention is difficult to apply due to the lack of data on whether preventive therapy (eg, aspirin, cholesterol-lowering drugs, antiplatelet agents) decreases the risk of radiation-associated childhood strokes.

Children who have been treated with either chemotherapy or radiation therapy for a brain tumor may have chronic headaches. These headaches can have features of migraines, tension-type headaches, cluster headaches, or a combination of all three. The exact pathophysiologic mechanism and true incidence are not fully understood. A certain proportion of patients will develop chronic daily headaches and require both prophylactic and abortive headache regimens. Unfortunately, in some cases, it is difficult to determine whether the headache is related to the disease or to the sequelae of treatment. It is important to recognize that headaches could be a sign of disease recurrence and may be present before there is MRI evidence of progressive or recurrent disease. A thorough headache history may be helpful in distinguishing whether there is a change in the headache pattern from baseline that warrants neuroimaging.

Less understood late effects of brain tumor treatment are depression and other psychosocial consequences. A wide range of patients of all ages, with all tumor types, tumor locations, and therapies, are at risk for depression.

It is unclear whether this condition is due to a direct effect of the tumor diagnosis or of therapy. Regardless, patients should be screened routinely for signs and symptoms of depression. Screening can be performed by both the neuro-oncology team and the pediatrician. When depression is suspected, a referral to child psychiatry or initiation of antidepressant therapy may be warranted. In terms of the psychosocial consequences of brain tumors, a high divorce rate among parents, disrupted sibling relationships, and problems with peer-to-peer interactions have been observed. A summary of the common late effects of brain tumor therapy is shown in Table 4.

Future of Pediatric Neuro-Oncology

The field of pediatric neuro-oncology is evolving rapidly, thanks in part to the advances in molecular biology. Many common primary brain tumors now can be categorized according to molecular markers, which someday soon will serve as the basis of risk stratification in clinical trials. Our improved knowledge of the molecular mechanisms of neuro-oncogenesis has led to the discovery of an enormous number of molecular-targeted therapies (ie, biologic agents) that currently are being studied in clinical trials for recurrent or refractory disease. These drugs are designed specifically to disrupt known tumor-specific molecular signaling pathways. It is the hope that one day, more specific targeted biologic therapies will replace conventional chemotherapy or radiation in the treatment of childhood brain tumors.

One of the great limitations in achieving success of biologic-based treatments is the ability of these drugs to cross the blood–brain barrier. To overcome this gatekeeper, a number of treatment strategies, including gene-based delivery systems, immunotherapies, and convection-based drug delivery, currently are being investigated.

Advances in radiation oncology are necessary for improving neurocognitive outcomes without sacrificing therapeutic efficacy. It is unknown whether proton beam therapy will be superior to conventional photon beam therapy, and results may not be known for many years. An improved understanding of the molecular mechanisms of radiation-related neurocognitive injury will allow for the development and implementation of neuroprotective agents at the initiation of therapy. Likewise, advances in neuroimaging will allow detection of tumor reoccurrence earlier and more accurate differentiation of treatment-related changes from disease reoccurrence.

Determining the genetic underpinnings of neuro-oncologic disease includes understanding epigenetic factors that govern neuro-oncogenesis. Today, a variety of mouse models exist that spontaneously and at great

Table 4. Potential Late Effects of Pediatric Brain Tumor Therapy

1. Endocrinopathy (hypothyroidism, growth hormone deficiency, corticotropin deficiency, precocious or delayed puberty, diabetes insipidus)
2. Secondary neoplasms (hematogeneous, skin, thyroid, CNS)
3. Cerebral vasculopathy (stroke, Moyamoya disease, angiitis)
4. Neurocognitive effects (learning, memory, IQ)
5. Sensorineural hearing loss
6. Scoliosis
7. Osteopenia
8. Primary headache disorder
9. Epilepsy
10. Infertility/dysmenorrhea
11. Depression/anxiety
12. Obesity/diabetes
13. Neuropathy
14. Ocular effects (vision loss, amblyopia, cataracts)
15. Cardiomyopathy
16. Renal insufficiency

CNS=central nervous system.

frequency form brain tumors similar to childhood disease. Primary tumor cell cultures have been established for a variety of pediatric brain tumors and are being used to study individual tumor growth patterns, as well as the potential responsiveness of tumors to a variety of chemotherapeutic and biologic therapies. As our knowledge of the role of stem cells in disease formation and progression improves, innovative stem cell therapies may play a role in the future of neuro-oncologic treatment. It is our belief that one or all of these advances in molecular medicine will allow us to achieve individualized brain tumor therapies for our patients and give the best hope for cure.

Role of the Pediatrician

Pediatric brain tumors are a rare but serious disease of childhood that require a multidisciplinary approach to diagnosis, ongoing management, and recognition of late effects of treatment. The role of the pediatrician is extremely important in all aspects of brain tumor management. A heightened awareness of the signs and symptoms of childhood brain tumors in conjunction with a focused neurologic examination may lead to an earlier diagnosis. Children who are long-term survivors of brain tumors face unique challenges with regard to a multitude of potential late effects of therapy and therefore require meticulous continuity of care beyond childhood and into adulthood.

The pediatrician serves as a crucial liaison between pediatric and adult medicine in providing continuity of care. It is the hope that improved understanding of the biology of disease will translate into novel therapies and improved survivals of children diagnosed with brain tumors.

Summary

- Based on strong evidence, brain tumors, although rare, are the No. 1 cause of death among all childhood cancers.
- Based on consensus, the morbidity and mortality associated with childhood brain tumors are determined by many factors, particularly tumor pathology, anatomic location, and treatment.
- Based on strong evidence, headache occurs in approximately one third of patients newly diagnosed with pediatric brain tumors.
- Based on consensus, brain tumors are managed by surgery, chemotherapy, or radiation, depending on tumor type, location and dissemination, and age.
- Based on strong evidence, in treating brain tumors, chemotherapy places the child at risk for future malignancies and radiation therapy places the child at risk for developing neurocognitive deficits.

References

1. CBTRUS, Central Brain Tumor Registry of the United States. CBTRUS statistical report: primary brain and central nervous system tumors diagnosed in the United States in 2004-2008. Available at: www.cbtrus.org. Accessed July 12, 2012
2. Howlader N, Noone AM, Krapcho M, et al, eds. SEER Cancer Statistics Review, 1975-2008, Bethesda, MD: National Cancer Institute. Available at: http://seer.cancer.gov/csr/1975_2008/. Accessed July 12, 2012
3. Louis DN, Ohgaki H, Wiestler OD, et al. The 2007 WHO classification of tumours of the central nervous system. *Acta Neuropathol.* 2007;114(2):97-109
4. Leary SE, Olson JM. The molecular classification of medulloblastoma: driving the next generation clinical trials. *Curr Opin Pediatr.* 2012;24(1):33-39
5. Kool M, Korshunov A, Remke M, et al. Molecular subgroups of medulloblastoma: an international meta-analysis of transcriptome, genetic aberrations, and clinical data of WNT, SHH, Group 3, and Group 4 medulloblastomas. *Acta Neuropathol.* 2012;123(4):473-484
6. Ginn KF, Gajjar A. Atypical teratoid rhabdoid tumor: current therapy and future directions. *Front Oncol.* 2012;2:114
7. Wilne S, Collier J, Kennedy C, Koller K, Grundy R, Walker D. Presentation of childhood CNS tumours: a systematic review and meta-analysis. *Lancet Oncol.* 2007;8(8):685-695
8. Harbert MJ, Yeh-Nayre LA, O'Halloran HS, Levy ML, and Crawford JR. Unrecognized visual field deficits in children with primary central nervous system brain tumors. *J Neurooncol.* 2012; 107(3):545-549

9. Ater JL, Zhou T, Holmes E, et al. Randomized study of two chemotherapy regimens for treatment of low-grade glioma in young children: a report from the Children's Oncology Group. *J Clin Oncol*. 2012;30(21):2641–2647

10. Merchant TE, Hua CH, Shukla H, Ying X, Nill S, Oelfke U. Proton versus photon radiotherapy for common pediatric brain tumors: comparison of models of dose characteristics and their relationship to cognitive function. *Pediatr Blood Cancer*. 2008;51(1):110–117

11. Armstrong GT, Liu Q, Yasui Y, et al. Long-term outcomes among adult survivors of childhood central nervous system malignancies in the Childhood Cancer Survivor Study. *J Natl Cancer Inst*. 2009;101(13):946–958

12. Reimers TS, Ehrenfels S, Mortensen EL, et al. Cognitive deficits in long-term survivors of childhood brain tumors: identification of predictive factors. *Med Pediatr Oncol*. 2003;40(1):26–34

13. Spiegler BJ, Bouff  t E, Greenberg ML, Rutka JT, Mabbott DJ. Change in neurocognitive functioning after treatment with cranial radiation in childhood. *J Clin Oncol*. 2004;22(4):706–713

14. Mulhern RK, Merchant TE, Gajjar A, Reddick WE, Kun LE. Late neurocognitive sequelae in survivors of brain tumours in childhood. *Lancet Oncol*. 2004;5(7):399–408

15. Armstrong GT, Stovall M, Robison LL. Long-term effects of radiation exposure among adult survivors of childhood cancer: results from the Childhood Cancer Survivor Study. *Radiat Res*. 2010;174(6):840–850

Suggested Reading

Gupta N, Banerjee A, Haas-Kogan D, eds. *Pediatric CNS Tumors*. New York, NY: Springer-Verlag; 2010

Keating RF, Goodrich JT, Packer RJ, eds. *Tumors of the Pediatric Nervous System*. New York, NY: Thieme Medical Publishers Inc; 2001

PIR Quiz

This quiz is available online at <http://www.pedsinreview.aappublications.org>. NOTE: Learners can take *Pediatrics in Review* quizzes and claim credit online only. No paper answer form will be printed in the journal.

New Minimum Performance Level Requirements

Per the 2010 revision of the American Medical Association (AMA) Physician's Recognition Award (PRA) and credit system, a minimum performance level must be established on enduring material and journal-based CME activities that are certified for *AMA PRA Category 1 Credit™*. In order to successfully complete 2013 *Pediatrics in Review* articles for *AMA PRA Category 1 Credit™*, learners must demonstrate a minimum performance level of 60% or higher on this assessment, which measures achievement of the educational purpose and/or objectives of this activity.

In *Pediatrics in Review*, *AMA PRA Category 1 Credit™* may be claimed only if 60% or more of the questions are answered correctly. If you score less than 60% on the assessment, you will be given additional opportunities to answer questions until an overall 60% or greater score is achieved.

1. The symptom that most warrants emergent neuroimaging for a suspected brain tumor in a previously well 4-year-old child is:
 - A. Episodic vomiting.
 - B. Newly discovered myopia.
 - C. Occasional isolated headache.
 - D. Progressive ataxia.
 - E. Single generalized seizure.

2. A 3-year-old boy presents with a 4-week history of headache, morning vomiting, and a wide-based gait. His examination reveals papilledema, ataxia, and dysmetria. He is most likely to have a:
 - A. Craniopharyngioma.
 - B. Frontal lobe glioma.
 - C. Medulloblastoma.
 - D. Migraine headache.
 - E. Optic glioma.

3. A 6-year-old girl has been noted to have progressive deterioration of her coordination over the past month and is no longer interested in play. On examination, you note palsy of her left abducens and facial nerves. You suspect a brainstem glioma. The best choice as an initial neuroimaging study is:
 - A. Head computed tomography scan with contrast.
 - B. Head computed tomography scan without contrast.
 - C. Lumbar puncture for opening pressure.
 - D. Magnetic resonance imaging spectroscopy.
 - E. Magnetic resonance imaging with and without contrast.

4. Neurosurgery is an integral part of diagnosis and management of most brain tumors. However, there are two types of brain tumors for which surgery is not required to establish a diagnosis. Diffuse intrinsic pontine glioma is one. The other is:
 - A. Choroid plexus carcinoma.
 - B. Central nervous system germinoma.
 - C. Medulloblastoma.
 - D. Optic glioma.
 - E. Supratentorial ependymoma.

5. The parents of a 12-year-old boy who has received both chemotherapy and radiation for a brain tumor ask you about late sequelae of those treatments. You explain that hematogenous and secondary systemic malignancies are a threat to any child receiving chemotherapy, whereas the most common effect specifically attributable to radiation therapy is:
 - A. Cerebral vasculopathy.
 - B. Chronic headache.
 - C. Depression.
 - D. Impaired learning.
 - E. Seizures.

Childhood Brain Tumors
John Crawford
Pediatrics in Review 2013;34:63
DOI: 10.1542/pir.34-2-63

Updated Information & Services

including high resolution figures, can be found at:
<http://pedsinreview.aappublications.org/content/34/2/63>

References

This article cites 13 articles, 3 of which you can access for free at:
<http://pedsinreview.aappublications.org/content/34/2/63#BIBL>

Subspecialty Collections

This article, along with others on similar topics, appears in the following collection(s):
Hematology/Oncology
http://pedsinreview.aappublications.org/cgi/collection/hematology:oncology_sub
Cancer/Neoplastic
http://pedsinreview.aappublications.org/cgi/collection/cancer:neoplastic_sub
Neurology
http://pedsinreview.aappublications.org/cgi/collection/neurology_sub
Neurologic Disorders
http://pedsinreview.aappublications.org/cgi/collection/neurologic_disorders_sub

Permissions & Licensing

Information about reproducing this article in parts (figures, tables) or in its entirety can be found online at:
</site/misc/Permissions.xhtml>

Reprints

Information about ordering reprints can be found online:
</site/misc/reprints.xhtml>

American Academy of Pediatrics

DEDICATED TO THE HEALTH OF ALL CHILDREN™

