

PediatricsinReview®

Bone Lesions: Benign and Malignant

Rani Gereige and Mudra Kumar
Pediatrics in Review 2010;31;355
DOI: 10.1542/pir.31-9-355

The online version of this article, along with updated information and services, is located on the World Wide Web at:

<http://pedsinreview.aappublications.org/content/31/9/355>

Pediatrics in Review is the official journal of the American Academy of Pediatrics. A monthly publication, it has been published continuously since 1979. Pediatrics in Review is owned, published, and trademarked by the American Academy of Pediatrics, 141 Northwest Point Boulevard, Elk Grove Village, Illinois, 60007. Copyright © 2010 by the American Academy of Pediatrics. All rights reserved. Print ISSN: 0191-9601.

American Academy of Pediatrics

DEDICATED TO THE HEALTH OF ALL CHILDREN™



Bone Lesions: Benign and Malignant

Rani Gereige, MD, MPH,*
Mudra Kumar, MD,
MRCP[†]

Author Disclosure
Drs Gereige and
Kumar have disclosed
no financial
relationships relevant
to this article. This
commentary does not
contain a discussion
of an unapproved/
investigative use of a
commercial
product/device.

Objectives After completing this article, readers should be able to:

1. Describe the usual presenting symptoms of osteosarcoma.
2. Identify the clinical and laboratory features of osteoid osteoma.
3. Discuss the treatment of fibrous cortical defect.
4. Understand the potential actions of Ewing sarcoma and osteosarcoma.
5. Explain the appropriate procedure for biopsy of a malignant bone tumor.

Introduction

Bone lesions can be benign or malignant. Patients may present to the primary care practitioner with common complaints such as pain or fracture or lesions may be found incidentally on radiographs obtained for other reasons. Pediatricians should maintain a high degree of suspicion and be familiar with the clinical presentation and initial evaluation of a child who has bone pain. This article reviews the common types of bone lesions and their clinical characteristics, differentiating features, diagnostic evaluation, and treatment.

Epidemiology

Primary bone tumors are the sixth most common neoplasm occurring in children and constitute approximately 6% of all childhood malignancies. Sixty percent of all primary bone tumors occur in patients younger than 45 years of age, with a peak incidence in 15- to 19-year-old individuals. These lesions are the third most common tumors in adolescents and young adults (exceeded only by leukemia and lymphoma). Osteosarcoma and Ewing sarcoma are the most common malignant bone tumors in this age group. Although the overall incidence of osteosarcoma is higher than Ewing sarcoma in adolescents younger than 20 years, Ewing sarcoma is more common in children younger than 10 years of age. Benign bone lesions, fortunately, are more common compared with the (relatively) rare malignant neoplasms of bone.

Focal bone lesions can be classified into three primary categories: benign, malignant (primary or secondary), and non-neoplastic. Table 1 lists the common types of bone lesions and their incidence in each category.

Presentation and General Management

Bone tumors often present as incidental findings on radiographs obtained for other reasons. Patients who have bone tumors occasionally present with pain, swelling, refusal to use the part, decreased range of motion, or a hard or fixed mass that may be tender. Approximately 5% to 10% of patients may present with fracture after seemingly minor trauma. Pain is more common with malignant lesions, usually present at rest or at night, and nonresponsive to nonsteroidal anti-inflammatory drugs (NSAIDs) or weak narcotics. However, pain also can be present in benign lesions.

Although a lesion that is enlarging rapidly usually suggests malignancy, some benign lesions (such as aneurysmal bone cysts) may enlarge rapidly, presenting a diagnostic challenge for the clinician. Others may mimic osteomyelitis and cause a delay in diagnosis.

Figure 1 highlights the diagnostic steps in the evaluation of a patient who has bone pain, swelling, or other bone symptoms. The primary care practitioner typically begins the evaluation with a plain radiograph. A referral to a subspecialist is warranted for additional delineation of a lytic or solitary bone lesion.

In many instances, a characteristic radiologic appearance helps differentiate benign from

*Editorial Board.

[†]Associate Professor of Pediatrics, University of South Florida, Tampa, Fla.

Table 1. Common Bone Lesions

Benign

- Osteochondroma (exostosis)
- Endochondroma
- Chondroblastoma
- Chondromyxoid fibroma
- Osteoid osteoma (2% to 3%)* 10% to 12% of all benign tumors
- Osteoblastoma (1%)* 3% of all benign tumors

Malignant

- Osteosarcoma (3.5%)[†]
- Ewing sarcoma (2% to 3%)[†]
- Chondrosarcoma
- Malignant fibrous histiocytoma
- Small cell osteosarcoma
- Adamantinoma

Non-neoplastic

- Unicameral bone cyst
- Aneurysmal bone cyst
- Fibrous dysplasia
- Osteofibrous dysplasia
- Eosinophilic granuloma
- Histiocytosis syndromes of childhood
- Infectious: Osteomyelitis

*Incidence of all childhood malignancies

[†]1% in patients <20 years of age

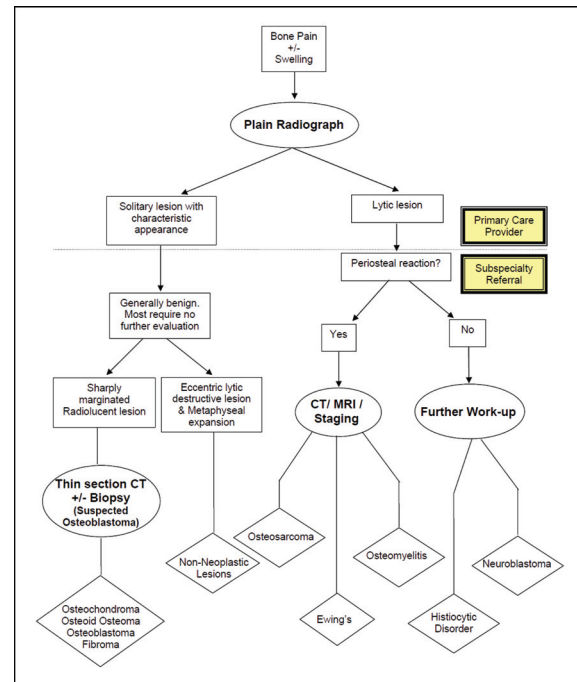


Figure 1. Diagnostic evaluation of bone pain with or without swelling.

malignant lesions and dictates additional evaluation. For example, benign tumors appear radiographically to be discrete lesions that have sclerotic margins and require little or no additional evaluation. A large number also resolve spontaneously or require no treatment.

In contrast, malignant tumors appear radiographically as lesions that have ill-defined margins, periosteal reaction, or soft-tissue calcification. For suspected malignant lesions, prompt referral to a comprehensive pediatric cancer center that has expertise in managing bone tumors is crucial. The biopsy should be performed by an orthopedic surgeon who has experience in oncology because when performing the biopsy, the clinician must consider how potential limb-salvage surgery would be affected by the biopsy procedure. Good sampling is essential to provide material for histology and other special studies such as biologic and immunologic markers and cytology. Needle biopsies may provide inadequate samples and may cause local tumor spread. The same surgeon preferably should perform the later surgery.

Magnetic resonance imaging (MRI) of the primary lesion is helpful in evaluating the intramedullary and extraosseous extent of the tumor as well as the tumor's

proximity to nerves and blood vessels before biopsy as well as in planning for later surgery. In addition, meta-static evaluation should be undertaken, including computed tomography (CT) scan of the chest, bone scan, and other studies, as indicated.

The treatment of malignant bone tumors is multidisciplinary and involves a team consisting of a surgeon, oncologist, and radiation oncologist as well as a rehabilitation specialist and physical therapist. Treatment should be undertaken in a specialized oncology center.

The current treatment approach encourages limb salvage and preservation, goals that are achieved and feasible in 90% of patients. Chemotherapy is administered before resection, followed by surgery. The resected tumor and tissue are studied extensively to determine the extent of necrosis, which indicates the chemosensitivity of the tumor. Tumor necrosis of more than 90% to 95% indicates a good response and an improved long-term prognosis. Resection is followed by postoperative chemotherapy and radiotherapy in some circumstances. Amputation occasionally is required when radiation or surgery would lead to incomplete tumor eradication or unacceptable functional outcome. Early prosthetic fitting and gait training should be encouraged. Rehabilitation and physical therapy are important components of

the management for all patients. Resection of metastases, such as lung lesions, may be indicated in some patients.

Malignant Bone Lesions (Table 2)

Osteosarcoma

Osteosarcoma is the most common primary malignant bone tumor in children and adolescents, constituting 15% of all primary bone tumors. This tumor is of mesenchymal origin and produces osteoid tissue. The peak incidence in the second decade coincides with the growth spurt. Affected teens usually are taller than their age-matched peers. The tumor is slightly more common in males than in females and in whites compared with those of other races. Osteosarcoma typically affects the long bones, often originating in the metaphysis. The areas around the knee (distal femur followed by the proximal tibia) are the most common sites. Other sites are listed in Table 2. Predisposing conditions include hereditary retinoblastoma, benign bone conditions such as Paget disease, endochondromatosis, multiple hereditary exostoses, fibrous dysplasia, and prior radiation exposure.

Patients usually present with a history of localized, dull, aching pain (day and night); swelling; a palpable mass; and occasional pathologic fracture (10% to 15% of cases). Systemic symptoms such as fever, weight loss, and decreased appetite are rare. Physical examination might reveal a palpable, soft, painful tissue mass with limitation of motion, joint effusion, warmth, and tenderness. Eighty percent of cases have localized tumor at presentation, but one in five patients has pulmonary metastases at diagnosis. The lungs are the most common site of metastases, followed by bones.

Laboratory studies may show elevated lactate dehydrogenase (LDH) concentrations (30%), alkaline phosphatase concentrations (40%), and erythrocyte sedimentation rate (ESR). Initial evaluation should include plain radiographs, which often reveal the hallmark of a sclerotic, destructive, bone-forming lesion, with occasional mineralization often extending into the surrounding soft tissues, described as a classic “sunburst” appearance (Fig. 2).

The general approach for evaluation and management has been discussed. With the introduction of chemotherapy, the long-term survival has improved over the past 30 years from 25% to 60% to 70% for nonmetastatic osteosarcoma. Fifty percent of patients who have limited pulmonary metastasis may be cured, and 25% of all patients who have metastasis may achieve long-term relapse-free survival.

One of the most important good prognostic factors is

the presence of more than 95% necrosis in the tumor at the time of surgery after preoperative chemotherapy. The prognosis is poor for those who have pelvic tumors and those who have bone and widespread lung metastases at presentation.

Very small pulmonary metastases (nodules <5 mm on CT scan) have no prognostic significance, but larger nodules (>10 mm) adversely affect survival. Survival also is better with smaller numbers (three or fewer pulmonary nodules), unilateral (versus bilateral) lesions, and successful and complete surgical resection of all lesions.

Almost 30% to 40% of patients who have extremity osteosarcoma develop recurrences (80% in lung and 15% distant bone metastases). The most important prognostic factor after relapse is the ability to achieve a second remission. Surgical resection is curative for patients who have parosteal osteosarcoma, a less aggressive variant found usually on the surface of long-bone metaphyses. Table 2 lists the primary prognostic indicators for osteosarcoma.

Ewing Sarcoma

Ewing sarcoma is the second most common bone malignancy in children and adolescents and represents 2% to 3% of all pediatric cancers. It is an undifferentiated, small, round cell tumor believed to be of neural crest origin and sometimes referred to as peripheral primitive neuroectodermal tumor. The Ewing sarcoma family of tumors usually arises in bone; extraosseous Ewing sarcoma is rare. Tumors of the chest wall also are called Askin tumors. Ewing sarcoma is more prevalent in males and in whites and practically absent in African Americans. The median age at diagnosis is 14 years; the tumor rarely is diagnosed before 5 years of age or after 40 years. The annual incidence is 250 new cases in the United States.

Ewing sarcoma affects primarily the metadiaphysis of long bones, followed by the pelvis and spine (Table 2). Spinal involvement is more common in the lumbar spine and sacrum. The tumor metastasizes primarily to lung or bones. A significant number of patients already have distant metastatic disease at presentation.

The most common clinical presentation of Ewing sarcoma includes localized, intermittent, and variable pain with a palpable mass and swelling in a bone or joint. A coincidental athletic injury may be implicated as the cause of pain, leading to a delay in diagnosis. Systemic symptoms such as fever, malaise, and weight loss are seen in advanced disease, often accompanied by elevated inflammatory markers (white blood cell count, ESR, and LDH), making osteomyelitis a consideration in the differential diagnosis. Other presenting symptoms can in-

Table 2. Comparison of Osteosarcoma and Ewing Sarcoma

	Osteosarcoma	Ewing Sarcoma
Sex: Male/Female	1.5 to 1	1.3 to 1.5:1
Race	All races	Primarily white
Most Common Site of Origin	<ul style="list-style-type: none"> Metaphysis of long bones (80% to 90%) (<i>Distal femur > proximal tibia > proximal humerus > middle and proximal femur > other bones</i>) 	<ul style="list-style-type: none"> Long bones (30%) (<i>Femur > ilium > tibia > humerus > fibula > ribs</i>) <ul style="list-style-type: none"> – Metadiaphysis (59%) – Diaphysis (35%) Pelvis (26%) Spine (11%) Occasionally soft tissue
Metastasis	<ul style="list-style-type: none"> Lungs (90%) Bone (10%) 	<ul style="list-style-type: none"> Lungs (50%) Bone (25%) Bone marrow (25%)
Radiographic Findings	<ul style="list-style-type: none"> Sclerotic destruction "Sunburst pattern" 	<ul style="list-style-type: none"> Primarily lytic "Onion skinning"
Differential Diagnosis	<ul style="list-style-type: none"> Ewing sarcoma Osteomyelitis 	<ul style="list-style-type: none"> Osteomyelitis Eosinophilic granuloma Lymphoma Neuroblastoma Rhabdomyosarcoma
Outcome	<ul style="list-style-type: none"> No metastasis: 70% cure Metastasis at diagnosis: ≤20% survival 	<ul style="list-style-type: none"> No metastasis: 60% cure Metastasis at diagnosis: 20% to 30% survival
Poor Prognostic Factors	<ul style="list-style-type: none"> Age <14 years High alkaline phosphatase value at presentation Tumor volume at presentation >200 mL Inadequate surgical margins Poor response to chemotherapy Presence of metastatic disease (most important) (~20% present with clinically detectable metastasis) – mostly lungs 	<p>Newly diagnosed patients:</p> <ul style="list-style-type: none"> <u>Site</u>: Pelvic and axial primaries <u>Stage</u>: Metastatic disease (lung only, better than bone only, better than combined) <u>Size</u>: Larger tumors >200 mL <u>Age at time of diagnosis</u>: Older patients <u>Other</u>: <ul style="list-style-type: none"> –Increased lactate dehydrogenase value –Male sex –Poor response to chemotherapy <p>Recurrent disease:</p> <ul style="list-style-type: none"> <u>Time to first recurrence</u>: <2 years have worse prognosis (2.5% to 12% versus 14% to 48% survival) <u>Site of recurrence</u>: Lungs only and local recurrence only have more favorable outcomes <u>Poor response to chemotherapy at time of recurrence</u> <u>Other</u>: <ul style="list-style-type: none"> –Lactate dehydrogenase value at time of diagnosis –Initial stage –Sex and age at time of recurrence
Favorable prognostic factors	<ul style="list-style-type: none"> An extremity as the primary tumor Tumor size <1/3 the diameter of the affected bone Absence of metastasis Good response to induction chemotherapy (<10% viable tumor remaining) Complete surgical remission of primary tumor 	<ul style="list-style-type: none"> <u>Histologic response to chemotherapy</u>: >90% tumor necrosis good prognostic factor <u>Radiologic response to chemotherapy</u> High response to chemotherapy Type 1 EWS-FLI-1 fusion transcript P53 expression by <20% of tumor cells

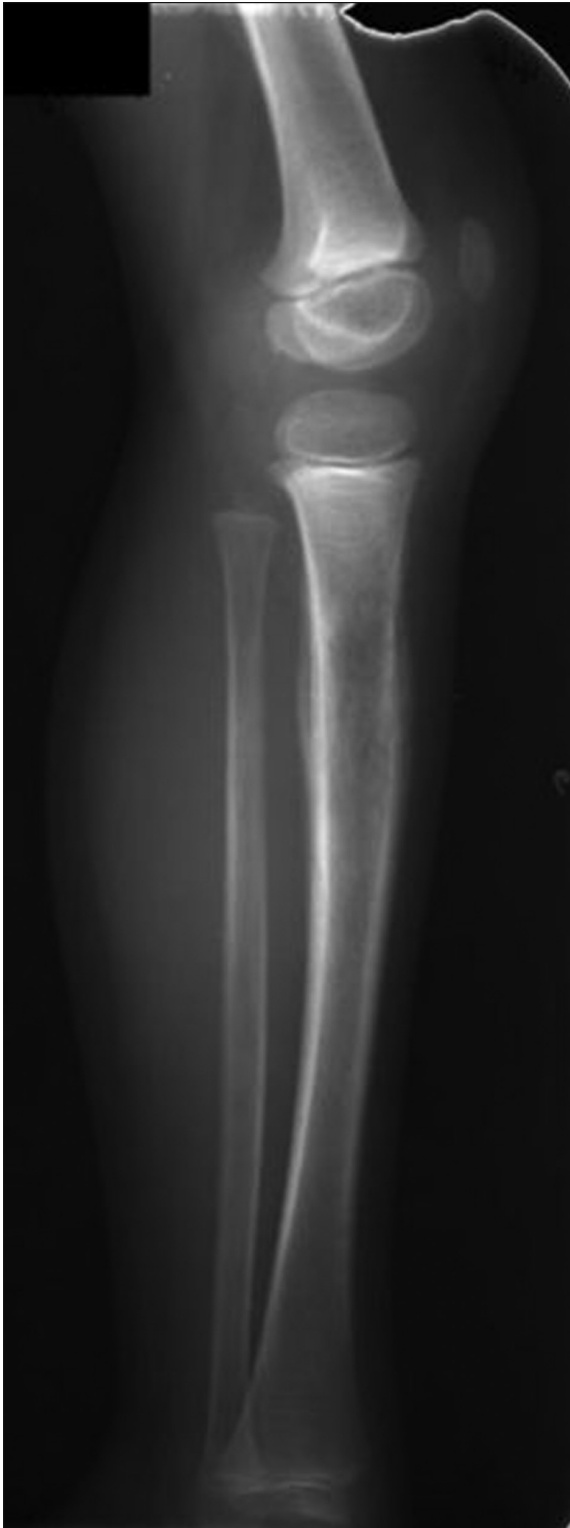

Figure 2. Lucent lesion of Ewing sarcoma in the proximal tibia with poorly defined borders and aggressive periosteal reaction.

clude respiratory distress in huge chest wall primary tumors and signs of cord compression in paraspinous or vertebral primary tumors.

Radiographs show a poorly marginated intramedullary lytic lesion with periosteal reaction or a mixed sclerotic and lytic lesion giving the typical “onion-skinning” appearance or “hair-on-end pattern” (Fig. 3). MRI is sensitive in evaluating the extent of disease. Diagnosis is confirmed by biopsy of the lesion with special neural stains and markers that help differentiate it from other blue round cell tumors, such as neuroblastoma and lymphoma. Eighty-five percent of cases have a balanced translocation EWS-FLI-1. Most have a nonrandom chromosomal translocation, 90% to 95% of which is the characteristic $t(11;22)(q24;q12)$. CT scan of the chest, MRI of the spine, bone scan, and bone marrow aspirate with biopsy are needed to evaluate the extent of the tumor.

Differential diagnosis includes osteosarcoma, osteomyelitis, Langerhans cell histiocytosis, primary lymphoma of bone, metastatic neuroblastoma, and rhabdomyosarcoma (extraosseous origin).

Multiagent intensive chemotherapy has improved the survival of patients who have nonmetastatic disease and has made limb salvage possible. Multinational protocols have demonstrated improved local disease control with surgery, with or without adjuvant radiation, compared with radiotherapy alone for nonmetastatic disease (5% to 10% versus 35% local recurrence).

Although the Ewing tumor is very radiosensitive, radiation is employed very selectively. Radiotherapy may have a role for tumors not amenable to surgical resection due to concerns of radiation-induced secondary tumors (4% to 8%), as when there is involvement of margins, poor response to chemotherapy, or metastatic disease.

Table 2 lists the primary prognostic indicators of Ewing sarcoma. Localized disease (especially distally located extremity tumors) has a 5- and 10-year survival rate of 70% to 75% and 50%, respectively. The most important prognostic factor is the presence of metastases at the time of diagnosis. Recurrent or metastatic disease at diagnosis is associated with a 25% to 30% 8-year overall survival rate. Response to chemotherapy is another important prognostic factor. Signs of response to chemotherapy include pain relief, decrease in tumor size and LDH values, radiologic improvement, and evidence of necrosis in resected specimens.

Primary lesions in the leg and ribs have a better outcome than tumors arising in the pelvis, humerus, and femur. Patients who have isolated pulmonary metastases and skip metastases in the same bone have a better clinical

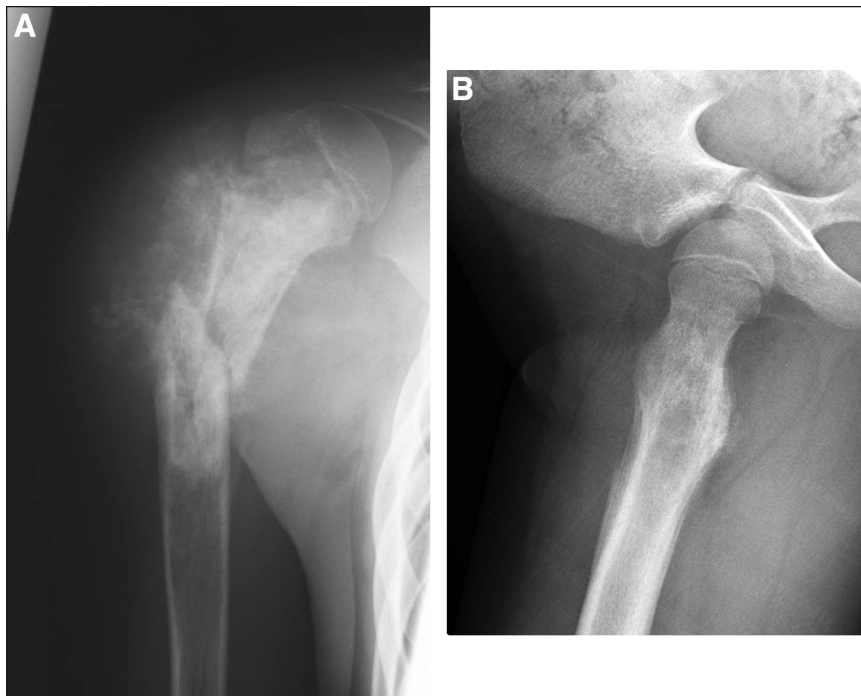


Figure 3. A. Permeative lesion in proximal humerus with pathologic fracture and extensive cloudlike bone formation in the soft tissue mass typical of osteosarcoma. B. Ewing sarcoma of the proximal femur demonstrating "onion skin" appearance. Courtesy of Doernbecher Children's Hospital, Portland, Ore.

outcome than those whose tumors have spread to other sites. The cumulative risk of developing bone sarcoma after treatment for Ewing sarcoma is estimated to be 20% at 20 years. High-dose chemotherapy and autologous bone marrow transplant may be associated with an 8% incidence of treatment-related leukemia and myelodysplastic syndrome

Other Malignant Lesions

Bone pain is the presenting feature of leukemia in approximately 50% of newly diagnosed children, but the bone pain more frequently is generalized and nonspecific rather than localized. The radiographs may appear normal, although in about 25% of patients, leukemic lines may be seen, which are faint lines that mimic growth arrest lines.

A primary B-cell lymphoma is very rare and may resemble Ewing sarcoma on radiographs. Bone is a frequent site of metastasis for many malignancies, including neuroblastoma, in which bone metastases typically are multifocal.

Chondrosarcomas are locally aggressive intramedullary lesions. Surgical excision is the mainstay of treatment because they are resistant to conventional chemotherapy

and radiotherapy and have a decreased tendency to metastasize to distant locations.

Malignant fibrous histiocytomas are high-grade malignant pleomorphic bone tumors that occur primarily in individuals older than 40 years of age. Small cell osteosarcomas are a rare variant of osteosarcoma, have a poor prognosis, and are difficult to distinguish pathologically. Adamantinoma are low-grade, slowly progressive lesions that occur exclusively in the diaphysis of the tibia and may metastasize to lungs, lymph nodes, and bones, with a 20% risk of recurrence.

Benign Bone Lesions

Osteochondroma (exostosis) is one of the most common benign bone tumors in adolescence, arising as an outward growth from almost any bone. Most are asymptomatic, but patients may present with pain due to irritation of overlying tissues.

These lesions arise in cartilage. They may enlarge as the child grows until he or she reaches skeletal maturity. On plain radiographs, osteochondromas appear as a stalk or projection from the bone surface. Osteochondromas generally are not removed (curettage/resection) unless the lesions cause pain or risk joint destruction. Patients should be evaluated by an orthopedist annually and followed with radiographs. Multiple hereditary exostosis is an autosomal dominant disorder with an increased risk of joint deformity, limitations in range of motion, and malignant degeneration. Osteochondroma rarely undergoes malignant degeneration to a chondrosarcoma in children.

Enchondroma is a benign cartilaginous lesion that usually appears as radiolucent with cortical thinning on radiographs and often is discovered incidentally following a pathologic fracture. Lesions most commonly occur in the phalanges, but the proximal humerus and distal femur also are frequent sites. Most are solitary; multifocal involvement is called Ollier disease. Multiple enchondromas associated with angiomas of the soft tissue is called Maffucci syndrome. Both Ollier and Maffucci syndromes are associated with a high rate of malignant transformation.

Chondroblastoma occurs primarily in the hip, shoulder, and knee. Typically, the tumor presents in the second decade of life with mild-to-moderate pain. Muscle atrophy and local tenderness may be the only signs. On plain radiograph, chondroblastoma appears as a sharply marginated, radiolucent lesion in the epiphysis or apophysis, occasionally with metaphyseal extension across the physis. Because they are locally aggressive, proximity to the joint may cause joint deformity, effusion, or erosion. Accordingly, chondroblastoma should be treated on presentation.

Chondromyxoid fibroma is an uncommon benign tumor often found in the lower extremity. Radiography shows eccentric, metaphyseal lucency with sharp, sclerotic, and scalloped margins.

Osteoid osteoma is a relatively common, self-limiting, small, benign osteogenic tumor (<2 cm) that has limited or no growth potential. Patients present with pain that is acute, intense, unremitting, of sudden onset, not associated with exercise or trauma, worse at night and at rest, and responsive to NSAIDs. Common sites are the femur and tibia. Plain radiographs show a round or oval metaphyseal or diaphyseal lucency (0.5 to 1 cm in diameter) surrounded by sclerotic bone. Central lucency corresponds to intense uptake on bone scan. Lesions smaller than 3 mm may not be seen on plain radiograph but can be seen with thin-section CT scan. MRI is poor in detecting them but sensitive in detecting nonspecific characteristics of the tumor, including bone marrow and soft-tissue edema. A contrast-enhanced CT scan may be needed to differentiate osteoid osteoma from chronic osteomyelitis.

Lesions of osteoid osteoma may resolve spontaneously, but treatment usually is undertaken to relieve pain, using curettage, CT scan-guided ablation, or en bloc resection. Radiofrequency ablation has emerged as a less invasive, substantially more time- and cost-effective technique. Surgery should be reserved for either spinal or appendicular lesions in proximity to neurovascular elements, for cases in which histology is unclear, and after repeated failures of percutaneous ablation or resection. Malignant transformation into aggressive osteoblastomas is rare; lesions more than 2 cm should raise the suspicion of osteoblastoma.

Osteoblastoma is a rare, benign, locally destructive, progressively growing lesion of insidious onset that causes dull, aching pain and presents similarly to osteoid osteoma. Osteoblastoma accounts for 1% of all bone neoplasms and 3% of all benign bone tumors and is more common in males. This tumor has a predilection for the spine and involves the same bones as osteoid osteoma. In

43% of cases, the radiographic appearance is diagnostic, but in 10% to 25% of patients, the lesion shows features suggestive of malignant neoplasm, making biopsy necessary. Osteoblastoma may be associated with other bony lesions, including aneurysmal bone cyst, giant cell tumor, and even osteogenic sarcoma. Treatment is surgical, using curettage, bone grafting, en bloc excision, and stabilization of the spine when necessary. A 17-year retrospective review of medical records of children with osteoblastoma showed a higher likelihood of recurrence in children younger than 6 years of age.

Fibromas (or benign fibrous cortical defects) usually are asymptomatic lesions in the femur occurring in children older than 2 years of age. They are bilateral or multiple in 50% of cases. They are the most common benign lesions of the skeletal system, frequently detected incidentally on radiographs taken for unrelated reasons. The diagnosis usually is based on history, physical examination, and radiographic findings. Fibromas appear as a sharply demarcated lucency of the metaphyseal cortex with sclerotic borders. Fibromas regress spontaneously after skeletal maturity; most require no biopsy or treatment. Lesions involving more than 50% of the bone diameter may require curettage and bone grafting due to the risk of pathologic fracture.

Non-neoplastic Bone Lesions

Unicameral bone cysts are fluid-filled lesions of unknown cause that occur most commonly in the proximal humerus and femur and often extend to the physis. They can be diagnosed at any age but rarely before 3 years of age or after skeletal maturity. Most are asymptomatic, and some are discovered after a pathologic fracture resulting from minor trauma. Radiographically, the cysts appear as solitary, centrally located lesions in the medullary bone. Some may resolve spontaneously after skeletal maturity. Treatment typically is pursued for large lesions or those in high-stress areas at risk of pathologic fracture. Pathologic fractures at the time of presentation typically are allowed to heal before treating. Treatments include aspiration of the lesion and injection with methylprednisolone, bone marrow aspirate, or another grafting material, often along with other biologic agents. This therapy may need to be repeated or curettage may be needed.

Aneurysmal bone cyst is a rapidly growing, reactive lesion in which the cavernous spaces of the involved bone are filled with blood and solid tissue aggregates. Such cysts present typically in the first 2 decades of life with pain and swelling. The cyst appears on radiography as an eccentric, lytic, destructive lesion with expansion of the metaphysis, differing from a unicameral bone cyst in that

the cyst may expand beyond the width of the epiphyseal plate. Treatment includes curettage and bone grafting or excision. There is a 20% to 30% recurrence risk 2 years after surgery, especially in younger children.

Fibrous dysplasia is a solitary or multifocal bone lesion that consists of fibrous replacement of cancellous bone. Most of these lesions are asymptomatic and self-limiting. Classically, lesions have a ground-glass appearance on radiographs and are expansile, involving the metaphysis or diaphysis. Surgery is indicated for relief of pain, progressive deformity, or pathologic fracture and is undertaken after growth is complete. Lesions of the femoral neck should be treated earlier due to the risk of pathologic fracture. The triad of fibrous dysplasia with precocious puberty and cutaneous pigmentation constitutes Albright syndrome.

Osteofibrous dysplasia is a benign bone lesion that occurs in children in the first decade of life. The lesion usually involves the tibia and presents with anterior swelling or enlargement of the leg. There is no pain unless a pathologic fracture exists. Radiographically, osteofibrous dysplasia appears as a solitary or multiple lucent cortical diaphyseal lesions that look radiographically similar to adamantinoma, a malignant neoplasm, necessitating biopsy more commonly than for other benign bone lesions. Treatment is observation. Excision and bone grafting should be delayed until after 10 years of age.

Eosinophilic granuloma is a disorder on the spectrum of Langerhans cell histiocytosis. Eosinophilic granuloma is a monostotic or polyostotic lesion occurring in the first 3 decades of life, primarily in boys 5 to 10 years of age. The condition most commonly affects the skull, followed by the vertebrae. Typically, the lesion presents with local pain. Because of the possibility of polyostotic involvement and skull lesions, a skeletal survey is warranted. Radiographically, eosinophilic granuloma appears as radiolucent lesions with well-defined margins. Biopsy is necessary to confirm the diagnosis. Bone scan may reveal additional lesions, although many will not demonstrate increased uptake. Because many of the lesions resolve spontaneously with no recurrence, a conservative approach may be tried. Other treatments include curettage, bone grafting, low-dose radiation, or corticosteroid injection. Although eosinophilic granuloma is considered a benign member of the histiocytosis group, involvement of multiple sites and organ systems such as skin, lymph nodes, bone marrow, liver, spleen, and central nervous system occurs in other forms of histiocytosis, which often are more aggressive and require intensive chemotherapy and treatment. The most common disorder in the histiocytosis group is Langerhans cell histiocytosis.

Summary

- Most primary bone tumors develop in the second decade of life (during the growth spurt).
- Most primary bone lesions are metaphyseal.
- A plain radiograph may be diagnostic in many tumors (especially benign lesions that have a characteristic appearance and site) and is a good starting point in the evaluation of focal bone lesions.
- CT scan may yield additional diagnostic information for very small lesions or in cases that have confusing radiographic findings.
- Both osteosarcoma and Ewing sarcoma metastasize to the lungs.
- Staging studies, including MRI of the local site, should be performed before any biopsy.
- Bone lesions should be biopsied in a center that has experience in the diagnosis and management of bone tumors.
- Limb salvage should be attempted and is possible in most bone malignancies.
- Most benign bone lesions can be managed conservatively with observation. Occasionally, curettage or excision may be required for large lesions, those proximal to a joint, or those that have premalignant features. Lesions involving more than 50% of the bone diameter may require curettage and bone grafting due to the risk of pathologic fracture.

Suggested Reading

- Arkader A, Dormans JP. Osteoblastoma in the skeletally immature. *J Pediatr Orthop*. 2008;28:555–560
- Bielack SS, Carrle D, Hards J, Schuck A, Paulussen M. Bone tumors in adolescents and young adults. *Curr Treat Options Oncol*. 2008;9:67–80
- Caudill JS, Arndt CA. Diagnosis and management of bone malignancy in adolescence. *Adolesc Med State Art Rev*. 2007;18:62–78
- Heare T, Hensley MA, Dell'orfano S. Bone tumors: osteosarcoma and Ewing's sarcoma. *Curr Opin Pediatr*. 2009;21:365–372
- Herzog CE. Overview of sarcomas in the adolescent and young adult population. *J Pediatr Hematol Oncol*. 2005;27:215–218
- Khoury JD. Ewing sarcoma family of tumors. *Adv Anat Pathol*. 2005;12:212–220
- Leavey PJ, Collier AB. Ewing sarcoma: prognostic criteria, outcomes and future treatment. *Exp Rev Anticancer Ther*. 2008;8:617–624
- Papathanassiou ZG, Megas P, Petsas T, Papachristou DJ, Nilas J, Siablis D. Osteoid osteoma: diagnosis and treatment. *Orthopedics*. 2008;31:1118
- Riggi N, Stamenkovic I. The biology of Ewing sarcoma. *Cancer Lett*. 2007;254(1):1–10
- Weber K, Damron TA, Frassica FJ, Sim FH. Malignant bone tumors. *Instr Course Lect*. 2008;57:673–688
- Yanagawa T, Watanabe H, Shinozaki T, Ahmed AR, Shirakura K, Takagishi K. The natural history of disappearing bone tumours and tumour-like conditions. *Clin Radiol*. 2001;56:877–886

PIR Quiz

Quiz also available online at <http://pedsinreview.aappublications.org>.

1. A 15-year-old boy has swelling of his right leg above the knee associated with aching pain. You find a 10-cm-long, tender mass along the distal shaft of the femur. Plain radiography identifies a sclerotic, destructive lesion that has areas of mineralization in the femur and surrounding soft tissues. Chest radiography appears normal. Of the following, the *most* likely diagnosis is:
 - A. Ewing sarcoma.
 - B. Lymphoma.
 - C. Osteoid osteoma.
 - D. Osteomyelitis.
 - E. Osteosarcoma.
2. A 10-year-old girl presents with the sudden onset of pain over her right proximal tibia. The pain is fairly severe, exacerbated by rest, and not relieved by sleep, although it is relieved by ibuprofen. Plain radiography reveals a 1.5-cm oval lucency in the metaphysis of the tibia surrounded by sclerotic bone. Of the following, the *most* likely diagnosis is:
 - A. Eosinophilic granuloma.
 - B. Ewing sarcoma.
 - C. Osteoid osteoma.
 - D. Osteomyelitis.
 - E. Osteosarcoma.
3. A 6-year-old girl fractures her proximal fibula while playing lacrosse. An incidental radiologic finding is a 1.0-cm, sharply demarcated radiolucency in the distal femoral metaphysis with a distinct rim of reactive bone. The child has no history of pain or swelling in this area. The radiologist believes that this is a fibrous cortical defect. Of the following, the *most* appropriate management is:
 - A. Biopsy.
 - B. Curretage.
 - C. En bloc incision.
 - D. Magnetic resonance imaging.
 - E. Observation.
4. A 12-year-old girl has had intermittent pain in her right arm for 5 weeks. Fever and malaise have developed over the past 2 weeks, and this morning she noted a swelling in the arm. A radiograph of the humerus reveals an intramedullary lytic lesion, which is poorly marginated. On the margin of the film, the radiologist notes two small pulmonary nodules. Of the following, the *most* likely diagnosis is:
 - A. Ewing sarcoma.
 - B. Langerhans cell histiocytosis.
 - C. Malignant fibrous histiocytoma.
 - D. Osteomyelitis.
 - E. Osteosarcoma.
5. You are evaluating a 16-year-old boy for a swelling of the proximal tibia. Plain radiography identifies the classic sunburst pattern of osteosarcoma. Of the following, the *most* important next step is to:
 - A. Measure alkaline phosphatase as a prognostic indicator.
 - B. Obtain chest radiography to rule out pulmonary metastases.
 - C. Order a white blood cell count and erythrocyte sedimentation rate to rule out Ewing sarcoma or osteomyelitis.
 - D. Refer the boy to a pediatric oncologic center that has orthopedic expertise in bone tumors.
 - E. Schedule echocardiography to evaluate baseline cardiac function before chemotherapy.

Bone Lesions: Benign and Malignant

Rani Gereige and Mudra Kumar
Pediatrics in Review 2010;31;355
DOI: 10.1542/pir.31-9-355

Updated Information & Services

including high resolution figures, can be found at:
<http://pedsinreview.aappublications.org/content/31/9/355>

References

This article cites 11 articles, 0 of which you can access for free at:
<http://pedsinreview.aappublications.org/content/31/9/355#BIBL>

Subspecialty Collections

This article, along with others on similar topics, appears in the following collection(s):
Hematology/Oncology
http://pedsinreview.aappublications.org/cgi/collection/hematology:oncology_sub
Blood Disorders
http://pedsinreview.aappublications.org/cgi/collection/blood_disorders_sub
Rheumatology/Musculoskeletal Disorders
http://pedsinreview.aappublications.org/cgi/collection/rheumatology:musculoskeletal_disorders_sub

Permissions & Licensing

Information about reproducing this article in parts (figures, tables) or in its entirety can be found online at:
</site/misc/Permissions.xhtml>

Reprints

Information about ordering reprints can be found online:
</site/misc/reprints.xhtml>

American Academy of Pediatrics

DEDICATED TO THE HEALTH OF ALL CHILDREN™

